

Are your **MRI contrast agents** cost-effective?

Learn more about generic **Gadolinium-Based Contrast Agents**.



FRESENIUS  
KABI

caring for life

**AJNR**

**MR of oculomotor nerve palsy.**

P Y Blake, A S Mark, J Kattah and M Kolsky

*AJNR Am J Neuroradiol* 1995, 16 (8) 1665-1672

<http://www.ajnr.org/content/16/8/1665>

This information is current as  
of April 20, 2024.

# MR of Oculomotor Nerve Palsy

Pamela Y. Blake, Alexander S. Mark, Jorge Kattah, and Martin Kolsky

**PURPOSE:** To assess the utility of MR in third cranial nerve palsy. **METHODS:** We reviewed precontrast and postcontrast MR of 50 patients with third cranial nerve palsy. **RESULTS:** MR demonstrated an appropriate lesion in 32 cases. Of these patients, 6 had brain stem lesions and 15 had involvement of the nerve in the cavernous sinus; lesions of the cisternal segment of the nerve were present in 11 patients, with enhancement of this segment observed in 9 patients. An inflammatory or infiltrative source of the palsy was indicated in 19 of these 32 cases. Of 7 patients with pupillary involvement suggestive clinically of a compressive lesion, 4 demonstrated thickening and enhancement consistent with an infiltrative lesion of the nerve. Eighteen patients with pupil-sparing third cranial nerve palsies and a history of diabetes or vascular disease had normal MR findings, with no enhancement of the third cranial nerve observed. **CONCLUSIONS:** Patients who do not have a history of diabetes or hypertension and in whom a complete or incomplete third cranial nerve palsy develops with or without pupil sparing should undergo MR imaging initially (unless there are clear symptoms or signs of subarachnoid hemorrhage) to exclude the presence of an infiltrative lesion or intraparenchymal process. Patients who have a history of vascular disease and a clinical presentation that is suggestive of an ischemic event may be observed initially, but should undergo imaging if improvement does not occur within 3 months.

**Index terms:** Brain stem, magnetic resonance; Nerves, oculomotor (III)

*AJNR Am J Neuroradiol* 16:1665–1672, September 1995

Paresis of the oculomotor nerve is a commonly encountered neurologic finding in patients who present with diplopia or ptosis. In a recent review of more than 4000 cases of patients with ocular motility palsies (1), the third cranial nerve was second only to the sixth cranial nerve in frequency of involvement.

Patients may present with an isolated or nonisolated, pupil-sparing or nonpupil-sparing cranial nerve III palsy. These clinical features are useful in locating the lesion along the course of the nerve and establishing its most likely cause. Pertinent details of the medical history, including the age of the patient, the presence of

vascular diseases including diabetes and hypertension, and a known systemic inflammatory process or malignancy, may suggest the etiologic diagnosis of a third cranial nerve palsy. Several studies have shown the statistically most common causes of oculomotor nerve palsy (2, 3, 4). There is debate, however, as to the location of the responsible lesion in several clinical settings. This is particularly true for the typically pupil-sparing cranial nerve III palsy in diabetic or hypertensive patients, which traditionally has been attributed to microvascular ischemia in the peripheral segment of the nerve, but by more recent authors to brain stem infarction (5).

Radiographic correlation with clinical symptoms was frequently not possible before the advent of magnetic resonance (MR) imaging. MR imaging has proved invaluable in confirming the site of the lesion in many patients with cranial nerve III palsy, because it allows the observer to scrutinize the entire course of the oculomotor nerve and surrounding structures. A characteristic appearance of the nerve is noted in different pathophysiologic processes. A pre-

---

Received November 15, 1994; accepted after revision March 20, 1995.

From the Departments of Neurology (P.Y.B.) and Ophthalmology (J.K.), Georgetown University Medical Center, and the Departments of Radiology (A.S.M.) and Ophthalmology (M.K.), Washington Hospital Center, Washington, DC.

Address reprint requests to Pamela Y. Blake, MD, Department of Neurology, Georgetown University Medical Center, 3800 Reservoir Rd, Washington, DC 20007.

*AJNR* 16:1665–1672, Sep 1995 0195-6108/95/1608–1665

© American Society of Neuroradiology

vious study (6) has described the enhancement of the cisternal segment of the oculomotor nerve as a neuroradiologic finding most often related to leptomeningeal inflammation or neoplastic infiltration of the nerve.

To assess better the value of this imaging modality in the evaluation of a patient with cranial nerve III palsy, 50 patients with this clinical presentation were retrospectively reviewed.

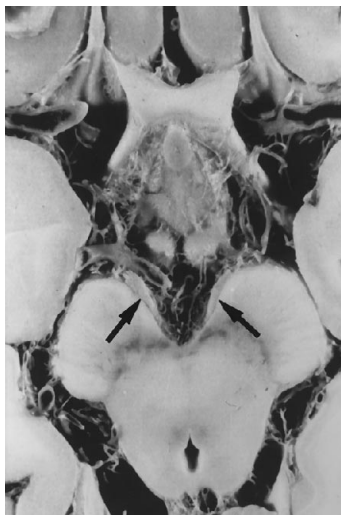### Materials and Methods

Fifty nonconsecutive patients from several institutions who developed a pupil-involving ( $n = 7$ ) or pupil-sparing ( $n = 43$ ) oculomotor nerve palsy were evaluated with MR. We retrospectively reviewed the available clinical data and the imaging studies. Data were not available to determine whether the cranial nerve III involvement was complete or incomplete. There were no specific selection criteria; the patients who were scanned presented a diagnostic dilemma to clinicians. Four of the patients described in this series were previously described (6). Our intent in the review was to note the various lesions that could be identified with MR imaging, not to determine the incidences of the various causes.

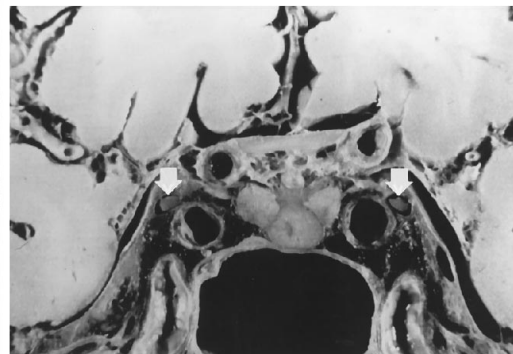
All patients underwent MR imaging on 1.5-T magnet with and without gadopentate dimeglumine, with T1-weighted images (600/14-20/3-4 [repetition time/echo time/excitations]) obtained in the axial plane with 3-mm-thick sections,  $256 \times 192$  matrix, and 16-20 field of view. Postcontrast T1-weighted images were obtained in coronal and axial planes through the interpeduncular and suprasellar cisterns. T2-weighted images (2600/30-90/3-4) axial images were obtained through the whole brain in 5-mm-thick sections with a 2.5-mm gap.

Fig 1. A, Normal anatomy is demonstrated in this axial anatomic section through the interpeduncular cistern. Note the cisternal segment of the oculomotor nerve (*arrow*).

B, Coronal anatomic section through the posterior aspect of the cavernous sinus. The oculomotor nerve (*arrow*) is located immediately above and lateral to the cavernous carotid artery. (Figure 1 courtesy of Jack DeGroot, MD.)



A



B

### Diagnoses of patients with MR-demonstrable cranial nerve III lesions

Diagnosis	Number of Patients
Brain Stem	
Ischemic infarct	2
Mass lesion	1
Cryptic vascular malformation	1
Hemorrhagic shearing injury	1
Hemorrhagic infarct	1
Subarachnoid Space	
Aneurysm	1 (1)
Lymphoma	3 (1)
Ophthalmoplegic migraine	1 (1)
Viral meningitis	2
Coccidioidiomycosis	1 (1)
Trauma	1
Syphilis	1
Miller-Fisher syndrome	1
Cavernous Sinus/Superior Orbital Fissure	
Lymphoma	3
Carcinoma	2
Tolosa-Hunt syndrome	4 (1)
Cavernous carotid aneurysm	2 (2)
Pituitary apoplexy	3
Craniopharyngioma	1

Note.—Numbers in parentheses indicate the subset of patients with pupil-involving cranial nerve III palsy.

### Results

Of the 50 patients studied, an identifiable imaging abnormality was found in 32 patients, as listed in the Table. Of the 11 patients with involvement in the subarachnoid space, enhancement of the nerve was evident in 9. The 15 with involvement in the cavernous sinus had either extension of a mass lesion (eg, pituitary ade-

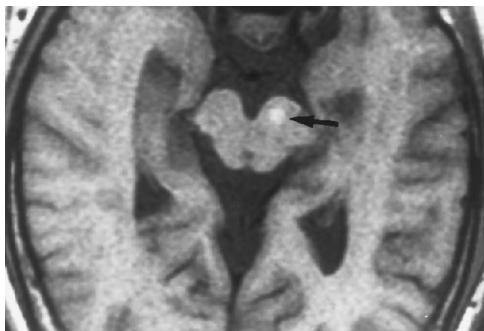


Fig 2. Fascicular lesion in a 40-year-old human immunodeficiency virus-positive man. Axial T1-weighted image demonstrates a small hyperintense lesion (*arrow*) that was present on both the T1-weighted images and the T2-weighted images. This appearance is consistent with a hemorrhagic lesion of unclear cause in this patient.

noma or a craniopharyngioma) into the sinus or increased tissue within the sinus (eg, Tolosa-Hunt syndrome). Six patients with a process affecting the cavernous sinus (2 with lymphoma, 2 with carcinoma, and 2 with Tolosa-Hunt syndrome) demonstrated enhancement of the nerve. Seven patients had involvement of the pupil, and 4 of these demonstrated intrinsic nerve lesions in the cisternal segment of the nerve. The remaining 3 had aneurysmal compression of the nerve.

Of the 18 patients who demonstrated no disease on MR imaging, there was a history of vasculopathy, attributable to hypertension or

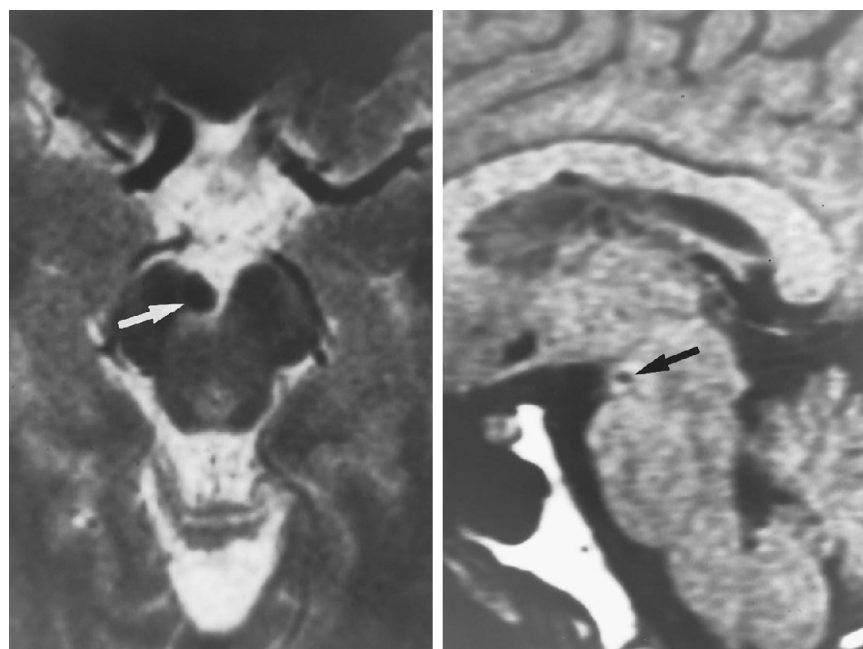
diabetes mellitus, in all. Among the 32 patients with identifiable lesions, there was a history of hypertension in only one patient with a brain stem infarct. None of the 32 patients had diabetes.

Figures 2 through 10 illustrate a variety of lesions affecting the oculomotor nerve that can be demonstrated with MR imaging. The incidence of the various causes of cranial nerve III palsy has been addressed by other reviewers (1, 7).

### Discussion

MR imaging is uniquely suitable for seeing the oculomotor nerve from its nuclear origin ventrolateral to the cerebral aqueduct at the level of the superior colliculus, along its intraaxial course through the midbrain to the interpeduncular cistern, and finally, along its subarachnoid course into the cavernous sinus and superior orbital fissure and orbital muscles (Fig 1). Lesions can be identified on gadopentetate dimeglumine-enhanced imaging along the entire course of the nerve from the nucleus to the superior orbital fissure.

Lesions within the brain stem affecting the nucleus or fascicle of the nerve have typical imaging patterns (Fig 2). The appearance of acute demyelinating and ischemic lesions on MR is very similar, with increased signal inten-



A

B

Fig 3. A presumed pial midbrain hemorrhage in a 32-year-old man with an acute right cranial nerve III palsy that spared the pupil.

A, The axial T2-weighted image demonstrates a 5-mm very low-intensity area on the medial aspect of the right cerebral peduncle at the emergence of the left cranial nerve III, consistent with a pial cryptic vascular malformation or hemangioma. Angiography was negative for aneurysm.

B, A sagittal T1-weighted image demonstrates a small area of low intensity (*arrow*) at the emergence of the right cranial nerve III, attributable to hemosiderin deposition.

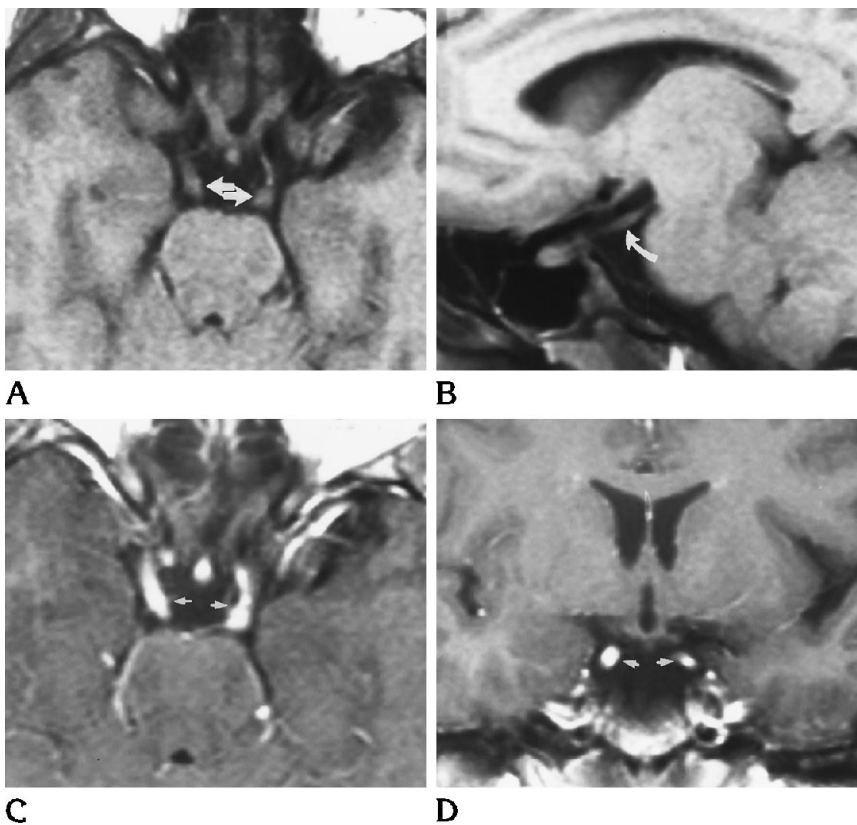
Fig 4. Syphilitic meningitis with cranial nerve involvement in a 19-year-old woman with headache, mild right cranial nerve III palsy, and diffuse sensory loss.

A, Marked thickening of the oculomotor nerves bilaterally is seen in the axial precontrast T1-weighted image of a young woman with acute syphilitic meningitis and concomitant human immunodeficiency virus infection.

B, Abnormal enlargement of the oculomotor nerve also is apparent in the parasagittal image.

C, After administration of gadopentetate dimeglumine, there is marked enhancement of the nerves bilaterally in the axial plane.

D, Coronal image through the suprasellar cistern also shows pronounced thickening and enhancement, with more involvement on the right. The thickening and enhancement of the nerves were partially resolved on a follow-up study performed after treatment with penicillin.



sity noted on T2-weighted images (8). The presence of other foci of high signal in the periventricular white matter may be suggestive of a more diffuse white matter disease, such as multiple sclerosis, or ischemic disease if many small punctate lesions are seen in the basal ganglia, basis pontis, and internal capsule. Clearly the age and clinical presentation of the patient and ancillary studies remain important in the identification of the underlying pathologic process. The MR appearance of brain stem hemorrhage (Fig 3) also is characteristic and helpful in estimating the age of the clot (9, 10).

Cranial nerve III involvement was observed in a number of inflammatory and neoplastic processes, in which infiltration of the meninges may cause thickening of the nerve that may be apparent on the unenhanced MR image (Fig 4). The disruption of the blood-brain barrier by either an inflammatory, infiltrative, or neoplastic process along the course of the nerve also may lead to enhancement of the cisternal portion of the nerve after the administration of gadopentetate dimeglumine (6). Cranial nerve involvement is particularly common in patients with lymphoma (Fig 5) and leukemia. A recently reported case of a patient in whom a third

nerve palsy with nerve enhancement developed several months before the diagnosis of lymphoma illustrates the importance of recognizing oculomotor nerve enhancement as potentially reflecting a systemic disease process (11).

Cranial nerve III enhancement has been shown consistently to represent an abnormality, but not always in conjunction with a clinically apparent cranial nerve III palsy (6). Primary human immunodeficiency virus infection was felt to be the cause in an asymptomatic patient who showed resolution of the enhancement after the initiation of antiretroviral drugs (6). The significance of the finding of enhancement is obvious in the four patients in our series who had oculomotor paresis with pupil involvement and normal arteriograms, but were found to have intrinsic nerve lesions demonstrated by nerve enhancement on MR imaging. The diagnoses of the patients with this combination of clinical and radiographic findings included ophthalmoplegic migraine (6), Tolosa-Hunt syndrome, lymphoma, and coccidioidomycosis (6). Thus, it is important to note that inflammatory or infiltrative processes may give rise to a painful, pupil-involving cranial nerve III palsy suggestive of an

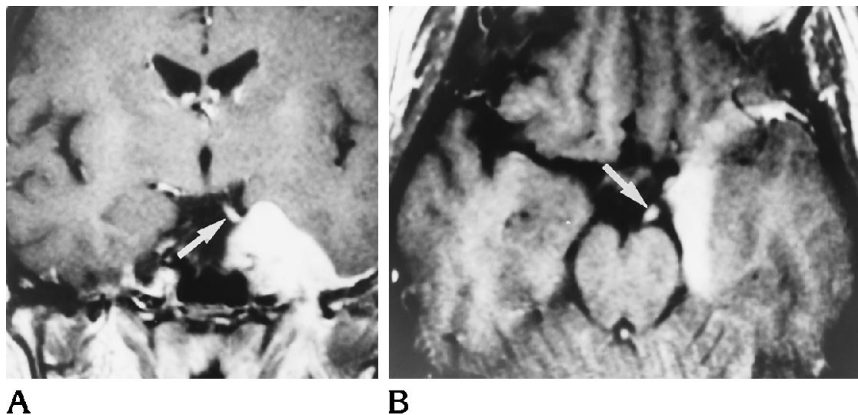


Fig 5. Cavernous sinus lymphoma in a 40-year-old woman who presented with left ophthalmoplegia.

A, Postcontrast coronal T1-weighted image demonstrates a large mass involving the posterior aspect of the left cavernous sinus, displacing the left uncus. Note infiltration of the left cranial nerve III (*arrow*).

B, Axial image demonstrates infiltration of the left oculomotor nerve (*arrow*) with thickening and enhancement after administration of gadopentetate dimeglumine.

aneurysm, and although conventional arteriography remains the critical diagnostic procedure to definitively diagnose an aneurysm, MR has an important role in determining other noncompressive etiologic processes. Furthermore, if MR performed early in the diagnostic evaluation is positive for intrinsic third cranial nerve involvement, it may render conventional angiography unnecessary.

Nerve enhancement also was demonstrated in a patient with ophthalmoplegia, areflexia, and ataxia (Miller-Fisher syndrome) (Fig 6). This finding corroborates the location of the abnormality in Miller-Fisher syndrome to be peripheral in cranial nerve III, as observed in autopsy (12) and neurophysiologic (13) studies, and not in the brain stem. The enhancement caused by demyelination is similar to that observed in demyelinating optic neuropathy (14, 15).

MR imaging has dramatically improved our ability to see the structures contained within the cavernous sinus. The clinical impression of cavernous sinus involvement may be confirmed by the nonspecific depiction of increased tissue mass in the sinus that often enhances after the administration of gadopentetate dimeglumine and may be seen extending into the superior orbital fissure (Fig 7). Nerve thickening and diffuse enhancement of cranial nerve III also may be observed in addition to the cavernous sinus mass (6).

Compression of the third cranial nerve also can result from sellar region mass lesions. The more fulminant processes, including pituitary apoplexy (Fig 8), are more likely to compress the third cranial nerve.

Microinfarction of the peripheral segment of the oculomotor nerve is a common complica-

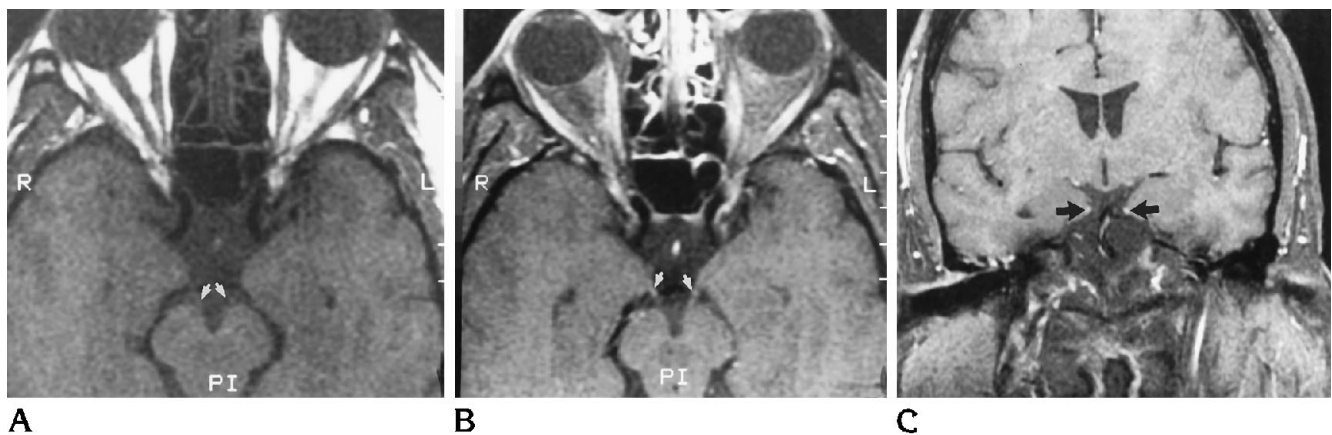


Fig 6. Miller-Fisher syndrome in a 39-year-old man with painless ophthalmoplegia, areflexia, and ataxia.

A, Axial T1-weighted image shows essentially normal anatomy. The oculomotor nerves are barely visible exiting into the intercavernous cistern.

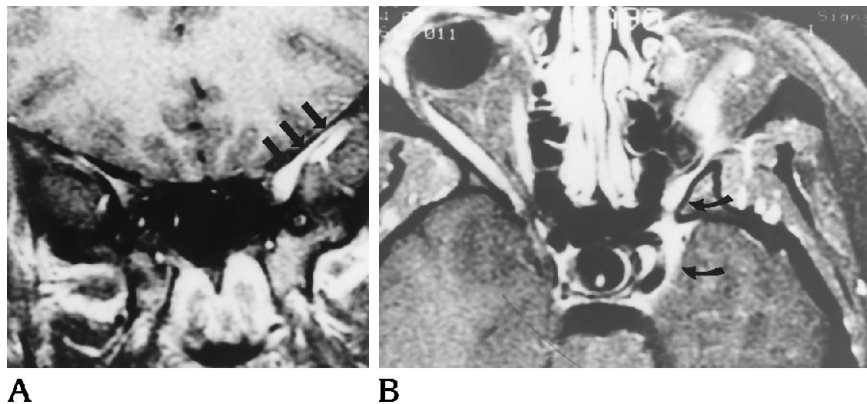
B, Mild enhancement of the oculomotor nerves demonstrated as isointensity to the adjacent brain is seen bilaterally on the axial gadopentetate dimeglumine-enhanced T1-weighted images.

C, The postcontrast coronal image also demonstrates mild enhancement of the nerves bilaterally.

Fig 7. Tolosa-Hunt syndrome involving the superior orbital fissure and cavernous sinus in a 20-year-old woman with painful ophthalmoplegia and headache.

A, Postcontrast fat-saturated T1-weighted images in the coronal plane demonstrate marked enhancement and thickening of the left superior orbital fissure (arrows).

B, After administration of gadopentetate dimeglumine, axial images with fat-saturation demonstrate thickening and enhancement of the anterior aspect of the cavernous sinus and the left orbital apex (curved arrow).



tion of systemic vascular diseases, particularly hypertension and diabetes, accounting for one third to half of all cases of isolated cranial nerve III palsy (1, 2, 3, 4, 7). Autopsy studies of patients with a known history of diabetes who died shortly after the development of a cranial nerve III palsy have shown well-demarcated areas of ischemia with accompanying noninflammatory demyelination of the intracavernous (16, 17) and subarachnoid (18) segments of the oculomotor nerve. Examination of the third cranial nerve in one patient who also had a remote third nerve palsy on the opposite side (17) demonstrated no abnormality of the axon or myelin. This finding supports the theory of demyelination with subsequent remyelination as the lesion in the diabetic, or ischemic, third nerve palsy. The relatively low incidence of ischemic causes

in our series was attributable to preselection of the patients who underwent scanning, because many patients with a known history of hypertension or diabetes who develop a pupil-sparing cranial nerve III palsy may not undergo an extensive evaluation. Notable in our review was the lack of any significant peripheral cranial nerve III abnormalities in the MR studies performed on patients with a history of diabetes mellitus or hypertension. Consequently, a normal, nonenhancing MR appearance of the oculomotor nerve and brain stem is felt to be consistent with (but not diagnostic of) vascular ischemia resulting in microinfarction of the core of the nerve in its peripheral segment. Our review revealed one case of brain stem infarction among the diabetic or hypertensive patients with acute cranial nerve III palsy. Brain stem infarction is therefore felt to be an uncommon cause of cranial nerve III palsy in these patients; microvascular infarction of the peripheral segment of the nerve, as reported by Dreyfus et al (16), is the more likely cause.

Based on these findings, it is generally accepted that a pupil-sparing cranial nerve III palsy in a patient with a history of arterial hypertension or diabetes mellitus is most likely attributable to infarction of the extraaxial segment of the nerve (19, 20). Third cranial nerve palsies caused by peripheral ischemia were shown to improve in 100% of patients within 12 weeks after the onset of symptoms in a recent review by Capo et al (21). These authors suggest that these patients may be treated with close observation (every 48 hours for 1 week). If symptoms do not improve substantially within 3 months, then another cause should be considered, and MR imaging may be undertaken at that time.

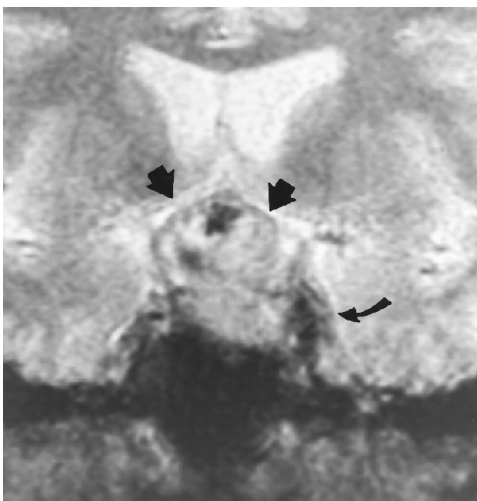


Fig 8. Coronal gradient echo image demonstrates areas of hemorrhage in the suprasellar portion of a pituitary adenoma (arrows) consistent with pituitary apoplexy, which extends into the left cavernous sinus (curved arrow).

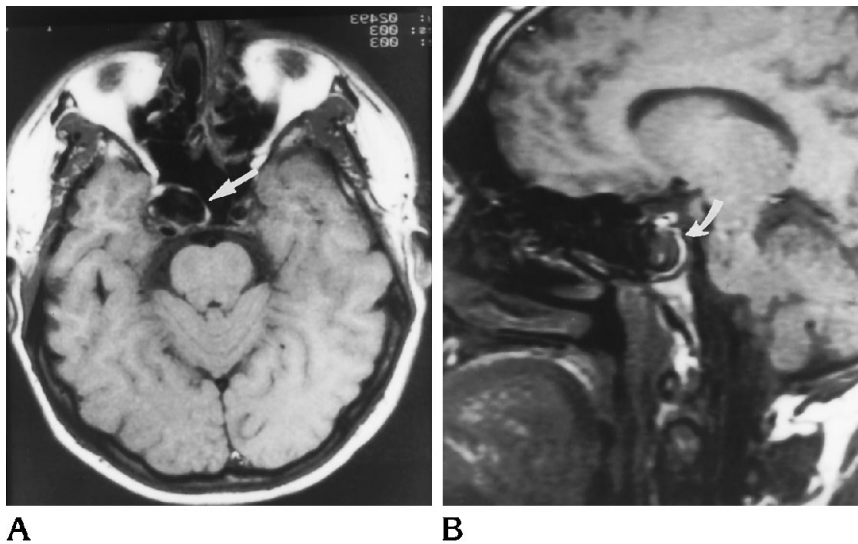


Fig 9. A 40-year-old woman with right cranial nerve III and cranial nerve IV palsies.

A, Axial T1-weighted image demonstrates a 1.5-cm right cavernous carotid aneurysm (*arrow*).

B, Sagittal T1-weighted image demonstrate right cavernous carotid aneurysm (*curved arrow*).

As cranial nerve III exits the midbrain it courses between the superior cerebellar and posterior cerebral arteries. Aneurysmal enlargement of either artery, or an aneurysm at the junction of the internal carotid and posterior communicating arteries, may compress the nerve and result in an isolated cranial nerve III palsy, almost always involving the pupil. An aneurysm of the posterior communicating artery was found to be the most common cause of an isolated, painful pupil-involving third nerve palsy in a review by Green et al (22). Aneurysms also may be seen on routine brain MR images (Fig 9); this is particularly important in the significant minority of patients in whom a third cranial nerve palsy develops from aneurysmal compression but with sparing of pupillary fibers (23).

Traumatic damage to the third cranial nerve may be sustained during head injury. A hemorrhagic injury to the brain stem may damage the nuclear or fascicular portion, or injury to the more peripheral segment of the nerve may be caused by a fracture that extends to the superior orbital fissure or cavernous sinus (24, 25). Stretching of the nerve may result in shearing injury or contusion, and excessive stretch may even cause an avulsion of the nerve. This is particularly important in patients who have an underlying clival or parasellar tumor, which may either stretch or immobilize the nerve, rendering it more vulnerable to any further stress. Complete avulsion of the nerve may be seen as a loss of the continuity of the nerve in the prepontine cistern (Fig 10). The onset of a cranial nerve III palsy after head trauma should prompt

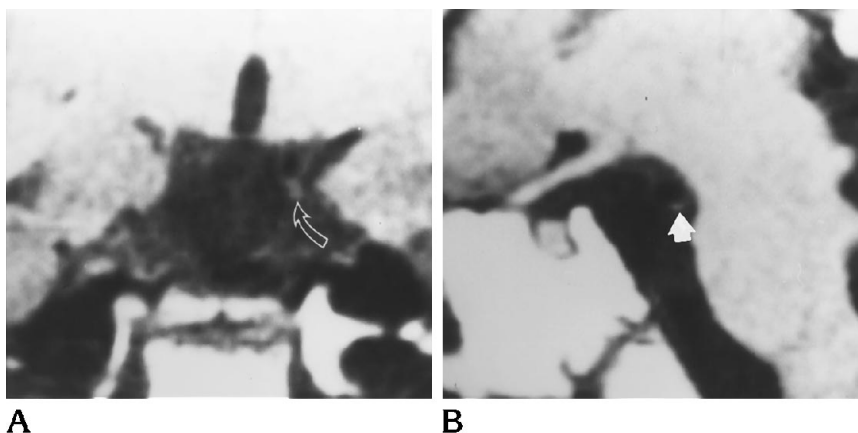


Fig 10. A, Traumatic avulsion of the third nerve is demonstrated on this parasagittal T1-weighted image, which does not fully show the third cranial nerve. Only a small residual stump (*arrow*) is noted between the superior cerebellar and posterior cerebral artery.

B, Coronal section demonstrates normal left cranial nerve III (*arrow*) with absence of right cranial nerve III.



an examination for an underlying mass lesion, which is most adequately performed with MR imaging.

From our observations, it is clear that MR imaging can show a variety of processes affecting cranial nerve III, including those that result in a pupil-sparing cranial nerve III palsy that may have previously been attributed to microvascular ischemia in the era before MR. In a young adult with no history of vascular disease or with a systemic inflammatory or neoplastic disease, or in the setting of trauma, the cause of a pupil-sparing cranial nerve III palsy frequently may be identified on MR imaging. Any patient with a pupil-involving cranial nerve III palsy should undergo imaging to exclude the presence of a compressive or infiltrative lesion. In the proper clinical setting, however, a patient with a pupil-involving cranial nerve III palsy who is obtunded or has signs of subarachnoid hemorrhage may initially benefit from computed tomography scanning to identify subarachnoid hemorrhage. If subarachnoid blood is seen, conventional angiography should follow to identify aneurysm.

## References

- Richards BW, Jones FR, Younge BR. Causes and prognosis in 4,278 cases of paralysis of the oculomotor, trochlear, and abducens cranial nerves. *Am J Ophthalmol* 1992;113:489-496
- Rucker CW. Paralysis of the third, fourth and sixth cranial nerves. *Am J Ophthalmol* 1958;46:787-794
- Rucker CW. The causes of paralysis of the third, fourth and sixth cranial nerves. *Am J Ophthalmol* 1966;61:1293-1298
- Rush JA, Younge BR. Paralysis of cranial nerves III, IV and VI: cause and prognosis in 1,000 cases. *Arch Ophthalmol* 1981;99:76-79
- Hopf HC, Gutmann L. Diabetic 3rd nerve palsy: evidence for a mesencephalic lesion. *Neurology* 1990;40(7):1041-1045
- Mark AS, Blake P, Atlas SW, Ross M, Brown D, Kolsky M. Enhancement of the cisternal segment of the third cranial nerve on Gd-MRI: clinical and pathological correlation. *AJNR Am J Neuroradiol* 1992;13:1463-1470
- Trobe JD. Isolated pupil-sparing third nerve palsy. *Ophthalmology* 1985;92:58-61
- Brant-Zawadzki M, Kucharczyk W. Vascular diseases: ischemia. In: Brant-Zawadzki M, Norman D, eds. *Magnetic Resonance Imaging of the Central Nervous System*. New York: Raven Press; 1987:2245-2263
- Zimmerman RD, Heier LA, Snow RB, Liu DPC, Kelly AB, Deck MDF. Acute intracranial hemorrhage: intensity changes on sequential MR scans on 0.5T. *AJNR Am J Neuroradiol* 1988;9:47-57
- Thulborn KR, Atlas SW. Intracranial hemorrhage. In: Atlas SW, ed. *Magnetic Resonance Imaging of the Brain and Spine*. New York: Raven Press; 1991:185-203
- Galetta SL, Sergott RC, Wells GB, Atlas S, Bird S. Spontaneous remission of a third-nerve palsy in meningeal lymphoma. *Ann Neurol* 1992;32:100-102
- Phillips MS, Stewart S, Anderson JR. Neuropathological findings in Miller-Fisher syndrome. *J Neurol Neurosurg Psychiatry* 1984;47:492-495
- Jamal GA, Ballantyne JP. The localization of the lesion in patients with acute ophthalmoplegia, ataxia and areflexia (Miller-Fisher syndrome). *Brain* 1988;111:95-114
- Guy J, Fitzsimmons J, Ellis EA, Mancuso A. Gadolinium-DTPA-enhanced magnetic resonance imaging in experimental optic neuritis. *Ophthalmol* 1990;97:592-599
- Guy J, Mancuso A, Quisling RG, Beck R, Moster M. Gadolinium-DTPA-enhanced magnetic resonance imaging in optic neuropathies. *Ophthalmol* 1990;97:592-600
- Dreyfus PM, Hakim S, Adams RD. Diabetic ophthalmoplegia: report of a case, with postmortem study and comments on the vascular supply of human oculomotor nerve. *Arch Neurol Psychiatry* 1957;77:337-349
- Asbury AK, Aldredge H, Hershberg R, Fisher M. Oculomotor palsy in diabetes mellitus: a clinico-pathologic study. *Brain* 1970;93:555-566
- Weber RB, Daroff RB, Mackey EA. Pathology of oculomotor nerve palsy in diabetics. *Neurology* 1970;20:835-838
- Trobe JD. Isolated pupil-sparing third nerve palsy. *Ophthalmol* 1985;92:58-61
- Trobe JD. Isolated third nerve palsies. *Semin Neurol* 1986;6:2
- Capo H, Warren F, Kupersmith MJ. Evolution of oculomotor nerve palsies. *J Clin Neuroophthal* 1992;10:21-25
- Green WR, Hackett ET, Schlezinger NE. Neuro-ophthalmologic evaluation of oculomotor nerve paralysis. *Arch Ophthalmol* 1960;72:154-167
- Kissel JT, Burde RM, Klingele TG, Zeigler HE. Pupil-sparing oculomotor paresis with internal carotid-posterior communicating artery aneurysms. *Ann Neurol* 1983;13:149-154
- Walsh FB, Hoyt WF. Craniocerebral trauma, hypoxia and injury by other physical agents. In: *Clinical Neuro-Ophthalmology*. 3rd ed. Baltimore, Md: Williams and Wilkins; 1969:2388
- Kruger M, Noel P, Ectors P. Bilateral primary traumatic oculomotor nerve palsy. *J Trauma* 1986;14:1237-1241