AJNR

Outcome analysis of preoperative embolization with N-butyl cyanoacrylate in cerebral arteriovenous malformations.

J S DeMeritt, J Pile-Spellman, H Mast, N Moohan, D C Lu, W L Young, L Hacein-Bey, J P Mohr and B M Stein

AJNR Am J Neuroradiol 1995, 16 (9) 1801-1807
http://www.ajnr.org/content/16/9/1801

Outcome Analysis of Preoperative Embolization with *N*-Butyl Cyanoacrylate in Cerebral Arteriovenous Malformations

J. S. DeMeritt, J. Pile-Spellman, H. Mast, N. Moohan, D. C. Lu, W. L. Young, L. Hacein-Bey, J. P. Mohr, and B. M. Stein

PURPOSE: To determine the influence of preoperative *N*-butyl cyanoacrylate embolization on outcome in the treatment of cerebral arteriovenous malformations. **METHODS:** Two groups were compared: 30 patients who underwent surgery and embolization versus 41 patients who underwent surgery only. Both groups were categorized by Spetzler-Martin grade and evaluated with the Glasgow Outcome Scale at various intervals. The long-term follow-up in months was, for surgery only, mean of 35 and range of 4 to 59, and for surgery and embolization, mean of 10 and range of 1 to 19). **RESULTS:** The arteriovenous malformations in the surgery and embolization group had a larger average greatest diameter (4.2 ± 1.5 cm versus 3.4 ± 1.8 cm) and were of higher Spetzler-Martin grade (89% versus 68% grade III-V). No significant difference in the preoperative or immediate postoperative (less than 24 hours) Glasgow Outcome Scale was identified between the two groups. At 1 week after surgery, the surgery and embolization group displayed a significantly better outcome evaluation (70% versus 41% with Glasgow Outcome Scale score of 5). The long-term evaluation continued to favor the surgery and embolization patients (86% versus 66% with Glasgow Outcome Scale score of 5). **CONCLUSION:** Preoperative *N*-butyl cyanoacrylate embolization improves postsurgical outcome.

Index terms: Arteriovenous malformations, cerebral; Arteriovenous malformations, embolization; Interventional materials, cyanoacrylate; Efficacy studies

AJNR Am J Neuroradiol 16:1801–1807, October 1995

The surgical treatment of cerebral arteriovenous malformations (AVMs) is thought to be facilitated by preoperative embolization. The natural course of cerebral AVMs (1) and the surgical outcome based on certain neuroanatomic features have been previously established (2–4). Preoperative embolization is felt to improve surgical results by reducing the size of the AVM, eliminating deep or inaccessible feeding vessels, decreasing blood loss, lowering the frequency of complications related to normal perfusion pressure breakthrough, and facilitating a surgical resection plane (5–7). Although a number of studies have addressed the potential benefits of combined endovascular and surgical treatment (7–12), few have attempted to quantify the difference in outcome with regard to concurrent or historical "surgery only" controls (5, 6).

Pasqualin et al (6) conducted a quantitative retrospective analysis of patients undergoing preoperative embolization with particulate agents versus surgery only controls. The preoperative embolization group was heterogeneous: 10 patients received flow-directed embolization into the carotid or vertebral artery using 2.5-mm silastic sponge particles, 35 patients underwent selective embolization with polyfilament threads, and 4 patients received a combination of the two techniques. Despite this mixed group of embolic agents and techniques, they demonstrated a significant decrease in major complications for patients undergoing preoperative embolization. Specifically, the rate of new

Supported by National Institutes of Health grant RO1-NS27713.

From the Departments of Radiology (J.S.D., J.P.-S., N.M., D.C.L., L.H.-B.), Neurology (J.P.M., H.M.), Neurosurgery (B.M.S.), and Anesthesiology and Neurosurgery (W.L.Y.), Columbia-Presbyterian Medical Center, New York, NY.

Address reprint requests to John Pile-Spellman, MD, Department of Radiology, 177 Fort Washington Ave, MHB4-4002, Columbia-Presbyterian Medical Center, New York, NY 10032.

AJNR 16:1801–1807, Oct 1995 0195-6108/95/1609–1801

major deficits for AVMs in eloquent areas was 5% for combined treatments and 31% for the surgery-only patients ($P = .03$) (6).

The only study to evaluate statistically preoperative *N*-butyl cyanoacrylate embolization with regard to surgery only controls showed similar long-term outcome between the two groups, despite larger size and higher Spetzler-Martin grade AVMs in the preoperative embolization group (5). These results are noteworthy, because the correlation between worse neurologic outcome and higher Spetzler-Martin grade has been previously demonstrated (2, 4, 13).

In this study, we have attempted to determine the influence of preoperative *N*-butyl cyanoacrylate embolization on early and long-term neurologic outcome in the treatment of cerebral AVMs.

Materials and Methods

The study group consisted of 30 consecutive patients with cerebral AVMs who underwent preoperative *N*-butyl cyanoacrylate embolization and surgical resection between April 1992 and November 1993. The nature of the embolization procedure was fully explained to each patient, and informed consent was obtained. Patients undergoing *N*-butyl cyanoacrylate embolization and subsequent radiosurgery were excluded from the study. The control group consisted of 41 concurrent and historical surgery only patients dating back to 1989. The average age for both groups was identical, 36 years old. All of the AVMs were embolized by a single interventionalist and resected by a single surgeon.

Both groups were categorized by Spetzler-Martin grade, which was calculated from the following: size of the AVM, eloquence of the adjacent brain, and the presence or absence of deep venous drainage (4). Whenever possible, the size of the AVM was determined from the pretreatment computed tomography or magnetic resonance scans by measuring the single greatest diameter to the nearest one tenth of a centimeter. Occasionally, cut film angiograms were used to measure the size, particularly for some of the older surgery-only controls. The angiogram was used to determine the pattern of venous drainage, whereas both the cross-sectional studies and the angiogram were used to determine the eloquence of adjacent brain.

The 30 surgery and embolization patients underwent a total of 72 embolizations for an average of 2.4 embolizations per patient. All of the patients were embolized with *N*-butyl cyanoacrylate via the femoral route. After the femoral puncture, the patients were kept fully heparinized for the duration of the procedure. Heparin was continued postoperatively, usually until the following morning, when the femoral sheath was removed. The usual routine was to place a 7F guiding catheter into the appropriate neck vessel and then perform a superselective catheterization of an AVM feeder using a flow-directed microcatheter (Magic, Balt, Montmorency, France). Road mapping was used to facilitate the catheterization. A superselective angiogram then was performed followed by a baseline neurologic exam. After scrutinizing the superselective angiogram for normal side branches, we routinely performed provocative testing, injecting sodium amobarbital first and then lidocaine, followed by a focused neurologic exam. If no neurologic deficit was found, we proceeded to embolize the feeder with the goal of depositing the *N*-butyl cyanoacrylate at the artery-vein communication site or nidus. Every effort was made to minimize the amount of *N*-butyl cyanoacrylate deposited in the veins and also to occlude any proximal dysplastic arterial segment. We routinely mixed *N*-butyl cyanoacrylate with the oil-based contrast material ethiodized oil (Ethiodol, Savage Laboratories, Melville, NY) to slow polymerization times; tantilum was added to opacify the solution. We estimated the *N*-butyl cyanoacrylate concentration and volume needed on the basis of the superselective angiogram. For example, faster shunts require a higher concentration of *N*-butyl cyanoacrylate relative to ethiodized oil, and larger vessels require more volume. Typical *N*-butyl cyanoacrylate–to–ethiodized oil ratios range from 1:1 in slow-flow shunts to essentially pure adhesive with a few drops of oil in very high-flow situations. In addition, systemic hypotension was induced to facilitate the embolization of high-flow shunts. Whenever possible, deep feeding vessels were preferentially embolized relative to the more surgically accessible superficial feeders. On average, a total of 2 to 4 feeders were embolized per session, with 3 to 4 weeks usually separating multistaged embolizations.

All patients undergoing embolization during a given week were reviewed at a multidisciplinary AVM conference. At these meetings, decisions were made concerning future embolization strategies and readiness for final surgical resection. In order of priority, the patients underwent embolization until terminal feeding vessel aneurysms or dysplastic segments were sealed, deep feeders were eliminated, the large fistulas were closed, and the majority of smaller shunts occluded. An attempt was made to embolize more thoroughly the more eloquent or surgically inaccessible lesions such as in the brain stem. Surgical resection was generally performed 1 to 4 weeks after the final embolization session. All patients underwent postoperative angiography to document complete surgical removal of their AVM. Typical preembolization, postembolization, and postresection angiograms are shown in Figure 1.

Clinical outcome was measured by using the Glasgow Outcome Scale, a five-point scoring system of neurologic function. A score of 1 represents a patient death; a score of 2 reflects a persistent vegetative state with no obvious cortical function; a score of 3 equals a severe mental or physical disability in which the patient depends on others for daily support; a score of 4 (moderate disability) is defined as independently living with varying degrees of aphasia, hemiparesis, ataxia, intellectual impairment, memory deficits, or personality changes; and a score of 5 represents a good recovery with no or minimal disability,

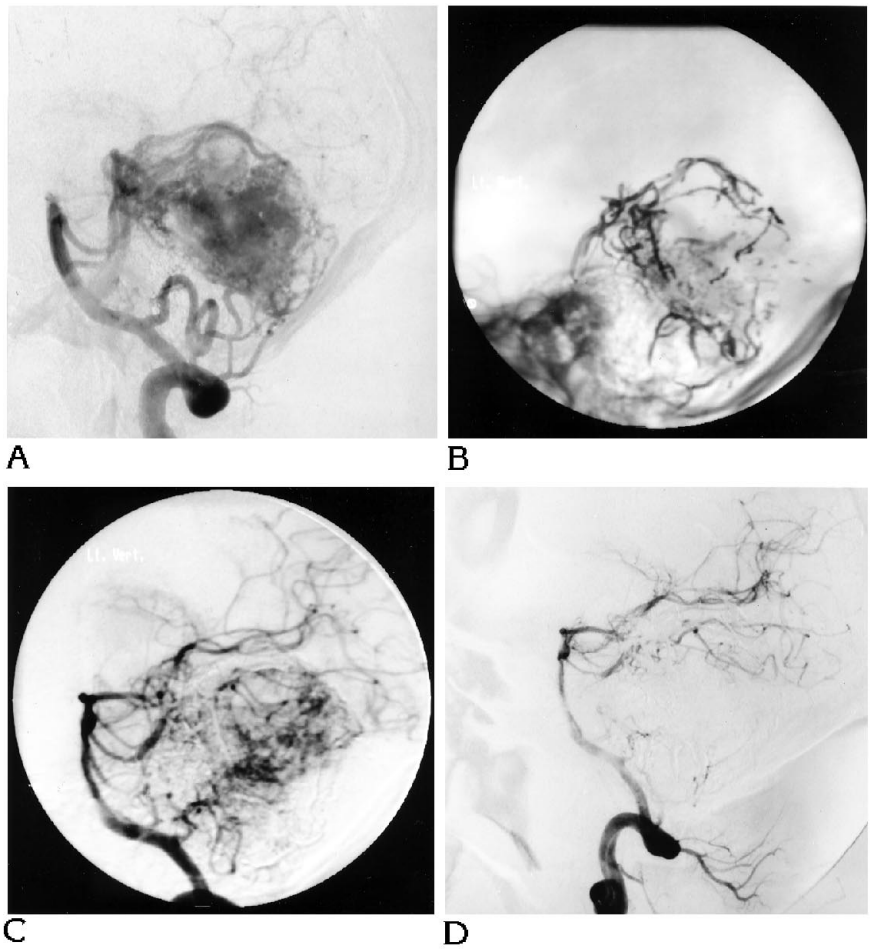

Fig 1. *A*, Preembolization lateral vertebral angiogram demonstrates a cerebellar AVM.

B, Postembolization lateral scout film shows radiopaque acrylate glue depositions in multiple feeding vessels and nidus of the AVM.

C, Postembolization lateral vertebral angiogram demonstrates a marked reduction in the size of the AVM.

D, Postoperative lateral vertebral angiogram demonstrates complete removal of the AVM.

and the patient is able to perform/resume normal activities despite minor deficits (15). A large visual-field defect (hemianopsia versus quadrantanopsia) or lower-field defect was considered to be a moderate disability, because it frequently limited activities of daily living such as driving or negotiating stairs. The patient examinations were performed by members of the stroke neurology service who then helped apply the Glasgow Outcome Scale. Immediate outcome was determined within the first 24 hours after surgery, whereas early outcome scores were obtained just before discharge, usually about 1 week after surgery. The Glasgow Outcome Scale also was used to evaluate the patients just before surgery and before and after each embolization procedure. The long-term clinical follow-up was performed with office visits and phone interviews. The surgery and embolization baseline outcome scores reflect their preembolization status, and the surgery-only baseline outcome scores were obtained immediately before surgery. For the purpose of analysis, the surgery and embolization and surgery-only patients were subdivided into those with outcome scores of less than 5 and those with a score of 5. This grouping separated patients with no or minimal deficit from those patients who were moderately disabled or worse.

Fisher's Exact (for $n < 5$) and χ^2 P values were used to perform statistical analysis of the data, using the software package StatView 4.01 (Abacus Concepts, Berkeley, Calif). Statistical significance was defined as $P < .05$.

Results

Relative to the surgery-only patients, the AVMs in the surgery and embolization group had a larger average greatest diameter (4.2 ± 1.5 cm versus 3.4 ± 1.8 cm) ($P < .05$) and tended to be of a higher Spetzler-Martin grade (89% grade III through V versus 68% grade III through V) ($P < .05$) (Table 1). All 71 patients had complete removal of their AVM documented by postoperative angiography usually within 3 days; a few patients underwent staged resection in the surgery-only group.

The baseline and postembolization outcome scores from the 30 study group patients are displayed in Table 2. Each patient underwent an average of 2.4 separate embolization proce-

Table 1. Spetzler-Martin grades

Grade	Surgery and Embolization	Surgery Only	**Total**
I, II	3 (10%)	13 (32%)	**16**
III through V	27 (90%)	28 (68%)	**55**
Total	**30**	**41**	**71**

Note.— Fisher's Exact $P = .0437$.

Table 2. Glasgow Outcome Scale patient distribution for embolization sessions*

Score	Preembolization	1 Week after Final Session	Presurgery
5	26	24	25
4	4	6	5
3	0	0	0
2	0	0	0
1	0	0	0

* Total of 72 embolizations for an average of 2.4 embolizations per patient.

dures. Two patients experienced deficits related to the embolization sessions within the first 24 hours, both dropping one level from a baseline outcome score of 5 to 4, and both deficits persisting at 1 week after the final session. One of the 2 patients had returned to baseline by the time surgery was to be performed, and 1 remained with an outcome score of 4.

The complete distribution of outcome scores for both the surgery and embolization and the surgery-only patients is displayed in Table 3. There was no statistically significant difference in preoperative or immediate postoperative (<24 hours) outcome scores between the two groups (Tables 4 and 5). The single patient with a baseline outcome score of 3 was in the surgery-only group; 76% of the surgery-only patients started with a score of 5 versus 87% in the surgery and embolization group. About half of the no or minimal deficit patients in each group got worse immediately after surgery, with a reduction from 26 to 13 (surgery and embolization group) and 31 to 15 (surgery-only group) in the number of patients with an outcome score of 5. The only two patients with immediate postoperative outcome scores of 2 were in the surgery-only group. At 1 week after surgery (Table 6), the surgery and embolization group had significantly better outcome scores (70% with Glasgow Outcome Scale score of 5) as compared with the surgery-only group (41% with Glasgow Outcome Scale score of 5) ($P < .05$). This 1-week delayed difference in outcome presumably reflects the resolution of more transient deficits in the surgery and embolization patients.

The range of long-term follow-up in the surgery-only group was 4 to 59 months, with an average of 35 months. The range of long-term follow-up in the surgery and embolization group was 1 to 19 months, with an average of 10 months. The long-term evaluation (Table 7) continued to favor the surgery and embolization patients (87% with Glasgow Outcome Scale score of 5) relative to the surgery-only patients (66% with Glasgow Outcome Scale score of 5) ($P = .057$), despite a significantly shorter average time of follow-up and higher Spetzler-Martin grade AVMs in the surgery and embolization group. The outcome results are summarized graphically in Figure 2.

Discussion

We have shown that preoperative *N*-butyl cyanoacrylate embolization improves surgical outcome. The data supporting preoperative endovascular therapy have been largely anecdotal, with two studies showing a quantitative benefit of embolization (5, 6). Our results show an improved outcome in the surgery and embolization group, which is first notable at 1 week after surgery (70% versus 41% with Glasgow Outcome Scale score of 5). Interestingly, there was no significant difference between the two groups immediately (<24 hours) after surgery, with about half of patients becoming worse in each group immediately after surgery. Presumably, the difference between the two groups becomes apparent after the resolution of more transient deficits, as might occur from postoperative edema or brain retraction. Alternatively, the surgery and embolization group may be more resilient, with a higher percentage regaining neurologic function by the end of the first week.

The long-term outcome scores continued to favor the surgery and embolization group (87% versus 66% with Glasgow Outcome Scale score of 5) ($P = .057$) despite shorter average follow-up and higher Spetzler-Martin grade AVMs. Shorter average follow-up (10 versus 35 months) and higher Spetzler-Martin grade (90% versus 68% with grade III through V) biased against the surgery and embolization group. These differences are noteworthy, because the correlation between improved outcome with

Table 3. Glasgow Outcome Scale patient distribution: surgery and embolization (SE) versus surgery only (SO)

Score	Preoperative*		24 Hours after Surgery		1 Week after Surgery		Long Term†	
	SE	SO	SE	SO	SE	SO	SE	SO
5	26	31	13	15	21	17	26	27
4	4	9	15	21	8	21	4	13
3	0	1	2	3	1	2	0	1
2	0	0	0	2	0	1	0	0
1	0	0	0	0	0	0	0	0

* Preembolization baseline for surgery and embolization patients and presurgery baseline for surgery-only patients.

† Length of long-term follow-up: surgery only, mean of 35 months; surgery and embolization, mean of 10 months.

Table 4. Preoperative* Glasgow Outcome Scale scores

Score	Surgery and Embolization	Surgery Only	**Total**
5	26 (87%)	31 (76%)	**56**
<5	4 (13%)	10 (24%)	**15**
Total	**30**	**41**	**71**

* Preembolization baseline for surgery and embolization patients and presurgery baseline for surgery-only patients.

Note.—Fisher's Exact $P = .367$.

Table 5. Immediate postoperative Glasgow Outcome Scale scores (<24 hours)

Score	Surgery and Embolization	Surgery Only	**Total**
5	13 (43%)	15 (37%)	**28**
<5	17 (57%)	26 (63%)	**43**
Total	**30**	**41**	**71**

Note.—$P = .5655$.

longer follow-up time (13) and worse outcome with higher Spetzler-Martin grade (2, 4, 13) has been previously established. The data from Heros et al (13) demonstrate the correlation between worse outcome and higher Spetzler-Martin grade and that significant improvement in outcome can occur with long-term follow-up. The percentage of patients with good or excellent results at the time of discharge after AVM surgery was 88.7% for grade III, 61% for grade IV, and 28.6% for grade V. At a mean follow-up of 3.8 years, the percentage of patients with good or excellent results was 100% for grade III, 87.8% for grade IV, and 61.9% for grade V (13). In our study, there was a 2-year greater average length of follow-up in the surgery-only patients, biasing against the surgery and embolization group. These differences in outcome with time should be kept in mind when considering the optimal window for comparing various treatment modalities.

Embolization-related complications appeared to have a minimal effect on the outcome of our study group. Only 1 patient of 30 (72 embolizations) experienced a lasting deficit related to the embolization sessions, dropping from a Glasgow Outcome Scale score of 5 to 4. The second embolization-related neurologic complication resolved before surgery, returning to a baseline Glasgow Outcome Scale score of 5. In an attempt to include the effect of embolization on overall outcome, the preembolization status of the surgery and embolization group was compared with the presurgical status of the surgery-only group. Our yearly combined major and minor complication rate between April 1992 and April 1993 was 2.9% (7 of 243 procedures) (16). A minor complication was defined as a permanent neurologic deficit (persistent at discharge) not affecting one's previous level of employment or activities of daily life (4 of 243). A major complication was defined as death (within 30 days of the procedure) or an inability of patients to return to their previous level of employment or activities of daily life (3 of 243). Specifically, there were two deaths and one major neurologic complication within 30 days of procedure for a yearly major complication rate of 1.2%. One of the deaths resulted from a cerebral bleed 15 days after the procedure and was questionably related; exclusion of this latter patient results in a yearly major complication rate of <1%. These data more specifically address the safety of embolization in a larger number of patients.

The Glasgow Outcome Scale was used to evaluate neurologic status for a number of reasons. The Glasgow Outcome Scale is most ideally suited for the evaluation of long-term outcome (17), the primary goal of the study;

Table 6. Early postoperative Glasgow Outcome Scale scores (1 week)

Score	Surgery and Embolization	Surgery Only	Total
5	21 (70%)	17 (41%)	**38**
<5	9 (30%)	24 (59%)	**33**
Total	**30**	**41**	**71**

Note.—P = .0172.

Table 7. Long-term postoperative Glasgow Outcome Scale scores

Score	Surgery and Embolization	Surgery Only	Total
5	26 (87%)	27 (66%)	**53**
<5	4 (13%)	14 (34%)	**18**
Total	**30**	**41**	**71**

Note.—Length of follow-up for surgery only was mean of 35 months; for surgery and embolization, mean of 10 months. Fisher's Exact P = .0569.

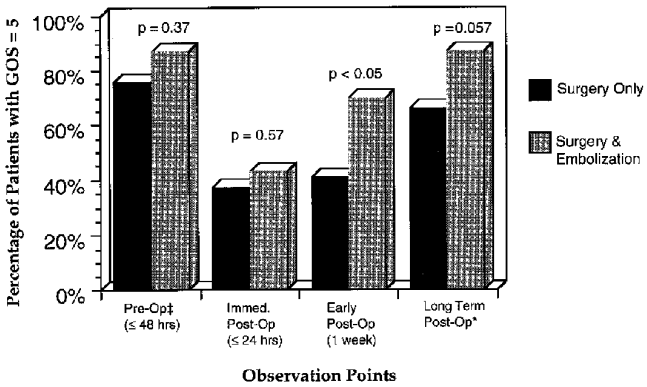

Fig 2. Percentage of patients with a Glasgow Outcome Scale (*GOS*) score of 5 at intervals after surgery (embolization and surgery versus surgery only).

‡ *Pre-Op* refers to preembolization baseline for surgery and embolization patients and presurgery baseline for surgery only patients.

* Length of follow-up (*Post-Op*): surgery only, mean of 35 months; surgery and embolization, mean of 10 months.

conclusions about short-term outcome were secondary. The Glasgow Outcome Scale has unambiguous endpoints that reflect large differences in neurologic function. Although a stroke scale would be ideally suited for early postoperative evaluations, it is less adaptable to a phone interview format and requires more expertise to apply. In this context, the Glasgow Outcome Scale was felt to be the most useful considering the primary goal of the study and the limitations of patient follow-up.

The various theories of why preoperative embolization appears to improve surgical outcome include shrinking the size of the AVM, decreasing blood loss, eliminating deep feeders, decreasing shunting, and reducing the frequency and severity of normal perfusion pressure breakthrough (5–7). Our most frequent complication after embolization is clearly cerebral ischemia; this is also the experience of Viñuela et al (7). The most frequent surgical complication in our institution also is probably ischemic, with only occasional hemorrhagic events reported. During the routine embolization of AVM feeding vessels, normal nutrient arteries below and occasionally above the resolution of angiography are invariably occluded despite meticulous technique. The subsequent development of clinical symptoms will largely depend on the eloquence of the involved brain, the volume of tissue at risk, and the availability of collateral flow. The development of collateral flow will be influenced by time and the number of available collateral vessels in the adjacent tissue. In support of this concept, we have noted a disproportionate increase in the number of ischemic complications when we embolize more than 2 or 3 feeders per session and/or separate the sessions by fewer than 3 weeks. We speculate that the improved outcome in the surgery and embolization group is partially the result of the staged sacrifice of normal nutrient vessels that would otherwise occur all at once during a single surgical procedure. This staged approach allows the tissue to recover and the microcirculation to develop collaterals. Staged preoperative embolization may in essence reduce the ischemic complications of surgery by gradually disconnecting branches to normal brain adjacent to the dedicated shunts.

Controversy remains concerning the safest and most effective embolic agent for treating cerebral AVMs (18). The embolic agents most frequently used today include polyvinyl alcohol particles, silk thread, microcoils, and the liquid adhesive *N*-butyl cyanoacrylate. The theoretical advantages of *N*-butyl cyanoacrylate include deep intranidal penetration, permanent occlusion, high thrombogenicity, and relative ease of delivery through small atraumatic microcatheters. Nonadhesive agents such as coils, silk thread, and polyvinyl alcohol (19) are subject to recanalization over time, making it difficult to treat large AVMs with multistaged embolizations over weeks to months. Although the cyanoacrylates are not immune to recanalization

(10, 15), it is distinctly unusual in our experience. Berenstein et al report an occurrence rate of less than 2% (20). Microcoils and silk thread can result in proximal occlusions with subsequent development of collateral vessels. This is particularly problematic for the surgeon if deep perforating arteries are recruited (7). The previously reported technical difficulties resecting AVMs embolized with the related agent isobutyl-2-cyanoacrylate have not been the experience with *N*-butyl cyanoacrylate. The embolized vessels have been easy to identify, retract, and transect (5, 10). The primary disadvantage of *N*-butyl cyanoacrylate is that significant experience is required for its proper use.

In conclusion, *N*-butyl cyanoacrylate embolization appears to improve postsurgical outcome, which is first evident at 1 week after surgery, presumably after more transient deficits have resolved. The long-term evaluation continued to favor the surgery and embolization group, despite shorter average follow-up and higher Spetzler-Martin grade AVMs relative to the surgery-only patients.

Acknowledgments

We thank Tara Jackson, BS, William Thompson, Steven Marshall, Andrei Osipov, Noeleen Ostapkovich, and the neuroradiology technologist staff for technical assistance and data collection. We gratefully acknowledge the support and contributions of the other members of the Columbia University AVM Study Project, including Robert R. Sciacca, PhD, and Philip O. Alderson, MD.

References

1. Ondra SL, Troupp H, George ED, Schwab K. The natural history of symptomatic arteriovenous malformations of the brain: a 24-year follow-up assessment. *J Neurosurg* 1990;73:387–391
2. Hamilton MG, Spetzler RF. The prospective application of a grading system for arteriovenous malformations. *Neurosurgery* 1994; 34:2–7
3. Heros RC, Tu YK. Is surgical therapy needed for unruptured arteriovenous malformations? *Neurology* 1987;37:279–286
4. Spetzler RF, Martin NA. A proposed grading system for arteriovenous malformations. *J Neurosurg* 1986;65:476–483
5. Jafar JJ, Davis AJ, Berenstein A, Choi IS, Kupersmith MJ. The effect of embolization with N-butyl cyanoacrylate prior to surgical resection of cerebral arteriovenous malformations. *J Neurosurg* 1993;78:60–69
6. Pasqualin A, Scienza R, Cioffi F, et al. Treatment of cerebral arteriovenous malformations with a combination of preoperative embolization and surgery. *Neurosurgery* 1991;29:358–568
7. Vinuela F, Dion JE, Duckwiler G, et al. Combined endovascular embolization and surgery in the management of cerebral arteriovenous malformations: experience with 101 cases. *J Neurosurg* 1991;75:856–864
8. Cromwell LD, Harris AB. Treatment of cerebral arteriovenous malformations: combined neurosurgical and neuroradiologic approach. *AJNR Am J Neuroradiol* 1983;4:366–368
9. Debrun G, Vinuela F, Fox A, Drake CG. Embolization of cerebral arteriovenous malformations with bucrylate. *J Neurosurg* 1982; 56:615–627
10. Fournier D, TerBrugge KG, Willinsky R, Lasjaunias P, Montanera W. Endovascular treatment of intracerebral arteriovenous malformations: experience in 49 cases. *J Neurosurg* 1991;75:228–233
11. Fox AJ, Pelz DM, Lee DH. Arteriovenous malformations of the brain: recent results of endovascular therapy. *Radiology* 1990; 177:51–57
12. Spetzler RF, Martin NA, Carter LP, Flom RA, Raudzens PA, Wilkinson E. Surgical management of large AVM's by staged embolization and operative excision. *J Neurosurg* 1987;67:17–28
13. Heros RC, Korosue K, Diebold PM. Surgical excision of cerebral arteriovenous malformations: late results. *Neurosurgery* 1990;26: 570–577
14. Rauch RA, Vinuela F, Dion J, et al. Preembolization functional evaluation in brain arteriovenous malformations: the ability of superselective Amytal test to predict neurologic dysfunction before embolization. *AJNR Am J Neuroradiol* 1992;13:309–314
15. Rao VR, Mandalam KR, Gupta AK, Kumar S, Joseph S. Dissolution of isobutyl 2-cyanoacrylate on long-term follow up. *AJNR Am J Neuroradiol* 1989;10:135–141
16. Young WL, Pile-Spellman J. Anesthetic considerations for interventional neuroradiology. *Anesthesiology* 1994;80:428–430
17. Jennett B, Bond M. Assessment of outcome after severe brain damage. *Lancet* 1975;1:480–484
18. Purdy PD, Batjer HH, Risser RC, Samson D. Arteriovenous malformations of the brain: choosing embolic materials to enhance safety and ease of excision. *J Neurosurg* 1992;77:217–222
19. Germano IM, Davis RL, Wilson CB, Hieshima GB. Histopathological follow-up study of 66 cerebral arteriovenous malformations after therapeutic embolization with polyvinyl alcohol. *J Neurosurg* 1992;76:607–614
20. Berenstein A, Lasjaunias P, Choi IS. Endovascular treatment of arteriovenous malformations of the brain. In: Anton V, ed. *Interventional Neuroradiology*. New York, NY: Springer-Verlag; 1993: 93–110