Fulminant Cerebral Lymphoma in AIDS

Frances L. Chiang, Bruce L. Miller, Linda Chang, Duncan McBride, Marcia Cornford, and C. Mark Mehringer

Summary: Three cases of cerebral lymphoma in patients with acquired immunodeficiency syndrome are presented. They are remarkable for their extremely rapid progression, which simulated an infectious processes during trials of antitoxoplasma therapy. Fourteen days of therapy are generally required to assess a negative response. However, earlier biopsies and shorter therapeutic trials may be indicated in these patients.

Index terms: Acquired immunodeficiency syndrome (AIDS); Lymphoma; Brain neoplasms

More than 80% of brain masses in patients with acquired immunodeficiency syndrome (AIDS) are caused by either toxoplasmosis or lymphoma (1). Because there is significant overlap in the clinical and imaging presentations, many patients receive 10 to 14 days of empiric treatment for presumed toxoplasmosis before brain biopsy is considered (2, 3). This delay in diagnosis is not usually significant (4, 5), although isolated cases in which growth is more rapid have been included in larger series (6, 7). We describe three patients with AIDS treated empirically for toxoplasmosis in whom fulminant growth of cerebral lymphoma occurred.

Case Reports

Case 1

A 28-year-old man with AIDS presented with a 1-week history of lethargy and bilateral third and sixth nerve palsies. Initial magnetic resonance (MR) showed four ring-enhancing lesions and irregular periventricular enhancement. Lumbar puncture revealed an elevated protein and normal glucose. Cytologic analysis, cultures, stains, and serum toxoplasmosis titers were negative. He was given a 10-day course of antitoxoplasma medications and dexamethasone during which his mental status declined. Subsequent computed tomography (CT) and MR showed that all lesions had increased in size, varying from 60% to 300% in volume (Fig 1). (Tumor volumes were calculated based on the largest dimension for round lesions or the average of the largest and smallest dimensions for oval lesions. Periventricular encasement was not included in tumor volume comparisons.) Brain biopsy yielded intermediate-grade B-cell lymphoma, large-cell type. He improved with radiation, but 5 months later there was recurrence in the spinal cord, and he died.

Case 2

A 32-year-old man with AIDS, Kaposi sarcoma, and a CD4 count of zero presented with a 1-month history of falls and low-grade fever. CT showed cerebral atrophy and a single ring-enhancing lesion in the right frontal lobe. Lumbar puncture revealed an elevated protein, normal glucose, and negative microbiology cultures and stains. Histoplasmosis titers were weakly positive, and cerebrospinal fluid cytologic analysis was negative. Serum toxoplasmosis IgG titers were negative, and the patient was discharged and received antitoxoplasma medications. Five days later he returned with worsening ataxia, nausea, vomiting, and declining mental status. The frontal lesion had increased in size on CT. MR additionally showed a rim of periventricular enhancement and a new solid nodule in the left temporal lobe. Noncompliance with medications was suspected, and he was maintained on antitoxoplasma therapy plus phenytoin and dexamethasone. Mental status continued to deteriorate. Eight days later the right frontal lesion was slightly smaller on MR, but the other areas had increased in volume by up to 1300% (Fig 2). Biopsy yielded a B-cell immunoblastic lymphoma. In the interim the patient had become unresponsive, did not improve with radiation therapy, and died within 3 weeks of pathologic diagnosis.

Case 3

A 33-year-old man with AIDS and a CD4 count of 20 presented with a 2-day history of fever, headache, nausea,

Received July 19, 1994; accepted after revision March 30, 1995.

Supported by grants 5R01NS29919-03 and M01RR00425 from the US Public Health Service.

From the Departments of Radiology (F.L.C., C.M.M.), Neurology (B.L.M., L.C.), Surgery (D.M.), and Pathology (M.C.), Harbor-University of California Los Angeles Medical Center, Torrance.

Address reprint requests to Frances L. Chiang, MD, Harbor-University of California Los Angeles Medical Center, 1000 W Carson St, Box 27, Torrance, CA 90509.

AJNR 17:157–160, Jan 1996 0195-6108/96/1701–0157

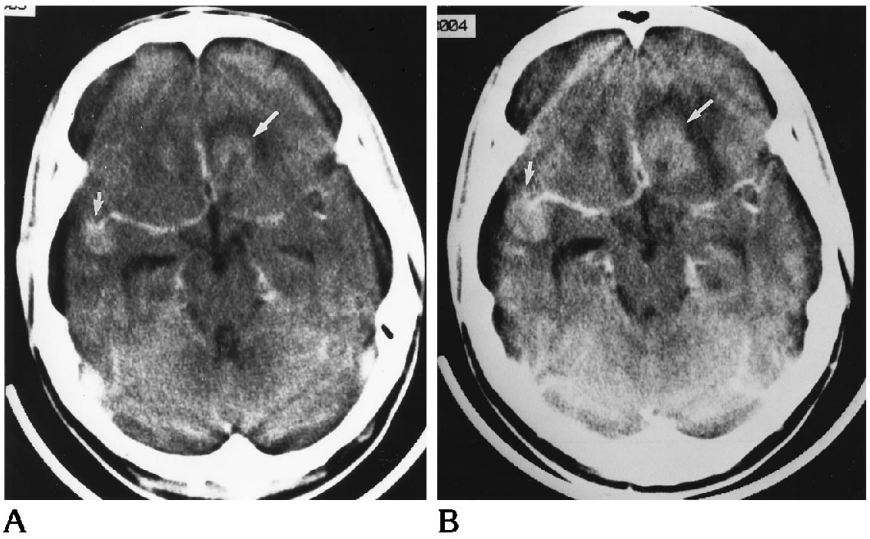

Fig 1. Case 1.
A, Enhancing masses on CT at presentation.
B, Follow-up enhanced CT shows rapid interval growth. Corresponding masses are indicated by *arrows*.

and vomiting. The initial CT scan showed four isodense masses with both ring and nodular patterns of enhancement and moderate edema. Lumbar puncture revealed an elevated protein and seven white cells. Microbiology studies and antigens were negative, including serum toxoplasmosis titers. He was given empiric antitoxoplasma and antituberculous therapy and steroids. After initially improving, his condition worsened. Because of suspected noncompliance, a new 2-week trial of antitoxoplasma treatment was begun. On follow-up CT 11 days later, lesions had increased in size (60% to 470% increased volume) and number. MR with gadolinium contrast showed 15 masses, all predominantly isointense to hypointense to gray matter on both short- and long-repetition-time/echo-time sequences. The lesions were ring enhancing; six had focal areas of hemorrhage. An initial biopsy was nondiagnostic but when repeated showed a high-grade B-cell lymphoma, consistent with an immunoblastic sarcoma. CT at the time of biopsy showed two lesions had increased in volume by 150% and 700% in the intervening 18 days. The patient was lethargic and disoriented and died 2 weeks later.

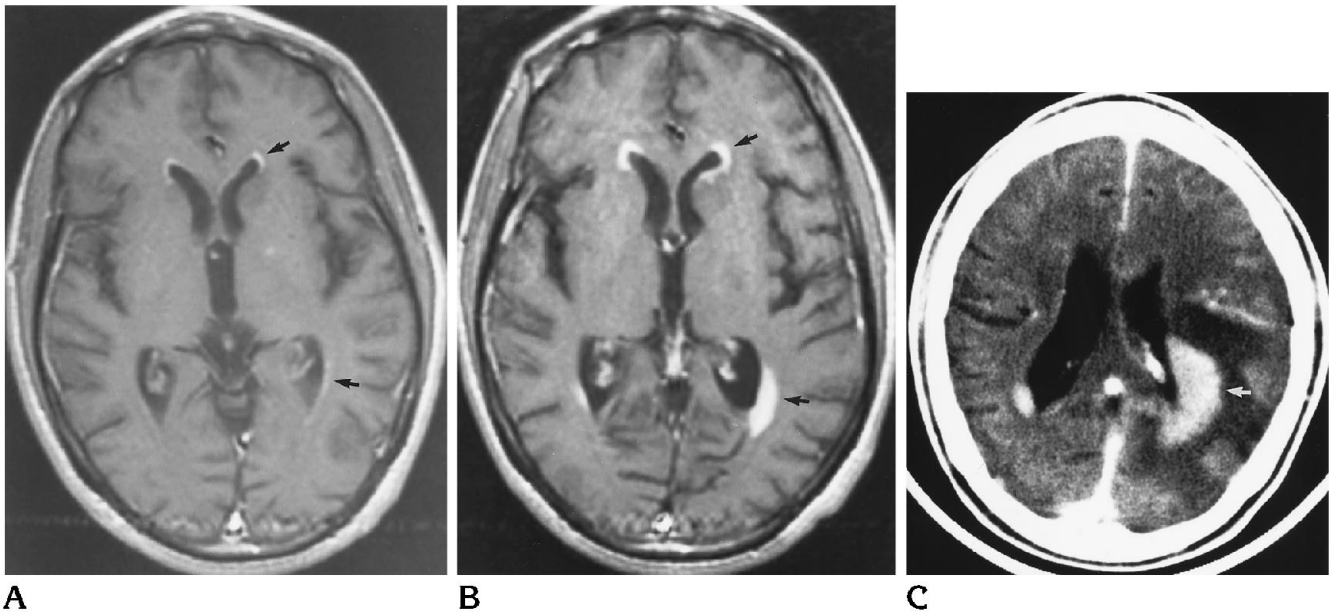

Fig 2. Case 2.
A, MR shows a thin rim of periventricular enhancement (*arrows*), also seen on CT at the same time (not shown).
B, Enhanced MR 8 days after A, shows a rapid increase in size.
C, Enhanced CT 7 days after the second MR (B) and 15 days after the first MR (A). Areas in B and C corresponding to A are indicated by *arrows*.

Discussion

Differentiation of toxoplasmosis and lymphoma in AIDS can be difficult and is not reliably made on imaging criteria alone. Classically, brain lymphoma may be a hyperdense mass on CT, although in patients with AIDS it may be hypodense. MR shows lesions that are hypointense on T1-weighted images and isointense or hypointense on T2-weighted images with variable areas of hyperintense signal. In patients without AIDS, lesions enhance confluently, but in patients with AIDS, heterogeneous or ring patterns occur. Periventricular spread encasing the ventricles is highly characteristic. Spontaneous hemorrhage is uncommon in lymphoma but common in toxoplasmosis. Lymphomas may hemorrhage after steroids or radiation therapies (as in case 3) (7, 8).

Toxoplasmosis abscesses are typically smaller and more numerous than are lymphomas. On CT, these lesions are hypodense. On MR they are hypointense on short-repetition-time/echo-time sequences and hyperintense on long-repetition-time/echo-time sequences unless focal hemorrhage has occurred. Early enhancement can be absent. However, lesions less than 1 cm in size often enhance throughout, whereas larger lesions may ring enhance, depending on the level of immune response. Toxoplasmosis abscesses do not spread in a periventricular pattern and uncommonly involve the ependyma (8). At times both diseases may be present concurrently (4, 7). Preliminary reports suggest that thallium-201 brain single-photon emission CT may show abnormal uptake in lymphoma but not in toxoplasmosis, for selected lesions (9, 10).

The clinical features of toxoplasmosis and lymphoma overlap. Similarly, cerebrospinal fluid samples show moderately elevated protein in lymphoma, normal or mildly elevated in toxoplasmosis (5, 8). Serum toxoplasma titers are negative in 22% of patients with pathologically proved disease (11), whereas patients with lymphoma sometimes have positive titers (7). Although lymphoma is suspected with negative toxoplasma titers, this is not sufficiently specific to direct therapy.

Empirical therapy with antitoxoplasma medications is used in most patients with AIDS who have brain masses. Follow-up radiographic studies show evidence of response to therapy after 14 days of treatment in 95% of patients with toxoplasmosis (2, 3, 11). Earlier images are obtained if new neurologic deficits develop. However, some series have shown an average delay of 4 weeks from the start of empirical therapy to biopsy (7, 8). Early diagnosis is important, because radiation therapy increases the mean survival in patients with lymphoma and AIDS from 42 to 134 days and changes the cause of death from tumor to other opportunistic infections. Delay in radiation therapy has resulted in poorer response and survival (12). Steroids are known to cause regression and tumor lysis in lymphoma. Although it may make biopsy diagnosis more difficult, this response has also been considered by some to be diagnostic (13, 14).

Our three patients exemplify the problem of empirical trials with antitoxoplasma medications and show the extremely aggressive nature of lymphomas in some patients with AIDS. All deteriorated rapidly over the 11 days during which they received empirical toxoplasma therapy. Images obtained 8 to 16 days from the initial studies showed that tumor volumes had increased between 60% and 1300%. In each patient at least one lesion increased by 300%, 470%, and 1300%, despite the use of steroids. In our patients 2 and 3, the outcomes were extremely poor in part because of the delayed diagnoses.

Others have described AIDS lymphoma cases with this fulminant course. Cordoliani et al found the mean doubling time was 13.6 days (7), whereas Epstein et al described a child who had new lesions every few days and died within 3 weeks (6). So et al mention three cases in which clinical progression was so rapid that vascular and infectious disorders were suspected (5). Lesions that double in less than 2 weeks are typically caused by infections. However, in the setting of AIDS, rapid growth of lymphoma is not rare; the patients described here represent 33% of the lymphomas that we have evaluated over the past 3 years. This rapid growth is troublesome because many lymphoma patients have a 2-week delay before biopsy with an even longer time before the onset of radiation. Additional delays occur as in two of our cases because of probable noncompliance with antitoxoplasma therapy. Of our three patients, all had negative toxoplasmosis titers, and two had highly characteristic patterns of periventricular tumor spread. Although neither of these features are diagnostic of lym-

phoma, together they indicate a need for earlier biopsy (8, 11). In our patients, tumor growth was so rapid that it suggested the course of an untreated infectious process, not tumor. Recognizing that lymphoma can progress this rapidly should prompt immediate biopsy in cases of imaging data more suggestive of lymphoma, and earlier follow-up studies during empirical therapy for toxoplasmosis.

References

1. Ciricillo SF, Rosenblum ML. Use of CT and MR imaging to distinguish intracranial lesions and to define the need for biopsy in AIDS patients. *J Neurosurg* 1990;73:720–724
2. Cohn JA, McMeeking A, Cohen W, Jacobs J, Holzman RS. Evaluation of the policy of empiric treatment of suspected toxoplasma encephalitis in patients with the acquired immunodeficiency syndrome. *Am J Med* 1989;86:521–527
3. Luft BJ, Hafner R, Korzun AH, et al. Toxoplasmic encephalitis in patients with the acquired immunodeficiency syndrome. *N Engl J Med* 1993;329:995–1000
4. Iglesias-Rozas JR, Bantz B, Adler T, et al. Cerebral lymphoma in AIDS: clinical, radiological, neuropathological and immunopathological study. *Clin Neuropathol* 1991;10:65–72
5. So YT, Beckstead JH, Davis RL. Primary central nervous system lymphoma in acquired immune deficiency syndrome: a clinical and pathological study. *Ann Neurol* 1986;20:566–572
6. Epstein LG, DiCarlo FJ, Joshi VV, et al. Primary lymphoma of the central nervous system in children with acquired immunodeficiency syndrome. *Pediatrics* 1988;82:355–363
7. Cordoliani Y, Derosier C, Pharaboz C, Jeanbourquin D, Schill H, Cosnard G. Primary cerebral lymphoma in patients with AIDS: MR findings in 17 cases. *AJR Am J Roentgenol* 1992;159:841–847
8. Dina TS. Primary central nervous system lymphoma versus toxoplasmosis in AIDS. *Radiology* 1991;179:823–828
9. O'Malley JP, Ziessman HA, Kumar PN, Harkness BA, Tall JG, Pierce PF. Diagnosis of intracranial lymphoma in patients with AIDS: value of 201-T1 single-photon emission computed tomography. *AJR Am J Roentgenol* 1994;163:417–421
10. Ruiz Am, Ganz WI, Post JD, et al. Use of thallium-201 brain SPECT to differentiate cerebral lymphoma from toxoplasma encephalitis in AIDS patients. *AJNR Am J Neuroradiol* 1994;15:1885–1894
11. Porter SB, Sande MA. Toxoplasmosis of the central nervous system in the acquired immunodeficiency syndrome. *N Engl J Med* 1992;327:1643–1648
12. Baumgartner JE, Rachlin JR, Beckstead JH, et al. Primary central nervous system lymphomas: natural history and response to radiation therapy in 55 patients with acquired immunodeficiency syndrome. *J Neurosurg* 1990;73:206–211
13. DeAngelis LM. Primary central nervous system lymphoma: a new clinical challenge. *Neurology* 1991;41:619–621
14. DeAngelis LM, Yahalom J, Heinemann MH, Cirrincione C, Thaler HT, Krol G. Primary CNS lymphoma: combined treatment with chemotherapy and radiotherapy. *Neurology* 1990;40:80–86