



ASNR Career Center

The Go-To Job Site for Neuroradiology Employers and Job Seekers
Start here: careers.asnr.org

AJNR

Prognostic value of the hyperdense middle cerebral artery sign and stroke scale score before ultraearly thrombolytic therapy.

T Tomsick, T Brott, W Barsan, J Broderick, E C Haley, J Spilker and J Khoury

This information is current as of October 2, 2023.

AJNR Am J Neuroradiol 1996, 17 (1) 79-85
<http://www.ajnr.org/content/17/1/79>

Prognostic Value of the Hyperdense Middle Cerebral Artery Sign and Stroke Scale Score before Ultraearly Thrombolytic Therapy

Thomas Tomsick, Thomas Brott, William Barsan, Joseph Broderick, E. Clarke Haley, Judith Spilker, and Jane Khoury

PURPOSE: To determine the relationship between the hyperdense middle cerebral artery sign (HMCAS) and neurologic deficit, as evidenced by the National Institutes of Health (NIH) stroke scale score, and to determine the relationship of the HMCAS and the NIH stroke scale score to arteriographic findings after thrombolytic therapy. **METHODS:** Fifty-five patients with acute ischemic stroke were rated on the NIH stroke scale, were examined with CT, and were treated with intravenous alteplase within 90 minutes of symptom onset. Presence of the HMCAS was determined on the baseline CT scan by a neuroradiologist blinded to the patient's neurologic deficit. Patients with the HMCAS were compared with those without the HMCAS with regard to baseline NIH stroke scale score, 2-hour NIH stroke scale score, findings at posttreatment arteriography, 3-month residual neurologic deficit, and 3-month ischemia volumes as evidenced on CT scans. **RESULTS:** Eighteen patients (33%) had the HMCAS. These patients had a median baseline NIH stroke scale score of 19.5 compared with a median score of 10 for the patients lacking the HMCAS sign. At 3 months, one (6%) of the HMCAS-positive patients was completely improved neurologically compared with 17 (47%) of the HMCAS-negative patients. Restricting analysis to those patients with a stroke scale score of 10 or greater ($n = 37$), 18 HMCAS-positive patients showed less early neurologic improvement, were less likely to be completely improved at 3 months, and had larger infarcts compared with the 19 HMCAS-negative patients. Compared with the HMCAS-positive and HMCAS-negative patients with a stroke scale score of 10 or greater, patients with a stroke scale score of less than 10 had fewer occlusive changes of the internal carotid and middle cerebral arteries on posttreatment arteriograms and had a better neurologic recovery at 3 months. **CONCLUSION:** The presence of the HMCAS on CT scans obtained within 90 minutes of stroke onset is associated with a major neurologic deficit, and in this study it predicted a poor clinical and radiologic outcome after intravenous thrombolytic therapy. However, a major neurologic deficit, defined as a stroke scale score of 10 or more, was better than a positive HMCAS as a predictor of poor neurologic outcome after thrombolytic therapy. Patients with a low stroke scale score (<10) may benefit from ultraearly intravenous alteplase therapy.

Index terms: Brain, infarction; Arteries, cerebral, middle; Thrombolysis

AJNR Am J Neuroradiol 17:79–85, January 1996

The hyperdense middle cerebral artery sign (HMCAS), a marker of thrombus in the middle

Received April 28, 1995; accepted after revision August 15.

Supported by National Institutes of Health, National Institute of Neurological Disorders and Stroke NOI-NS-3-2324.

From the Departments of Radiology (T.T.), Neurology (T.B., J.B., J.S., J.K.), and Emergency Medicine (W.B.), University of Cincinnati (Ohio) Medical Center; and the Department of Neurology, University of Virginia, Charlottesville (E.C.H.).

Address reprint requests to Thomas Tomsick, MD, Department of Radiology, University of Cincinnati Hospital, 231 Bethesda Ave, Cincinnati, OH 45267.

AJNR 17:79–85, Jan 1996 0195-6108/96/1701-0079

© American Society of Neuroradiology

cerebral artery (MCA), has been recognized as a harbinger of a subsequent large cerebral infarction by computed tomography (CT) (1–7) (Fig 1). Ricci et al (8) suggested that stroke patients with the sign have a poorer outcome than those without it. Leys et al (9) demonstrated that only one fifth of patients with the sign have an excellent prognosis. Wolpert et al (10) did not detect a correlation between the presence of the sign and a subsequent recanalization after therapy with intravenous alteplase (tissue plasminogen activator; Activase, Genentech, South San Francisco, Calif), but they did not analyze the potential relationship of

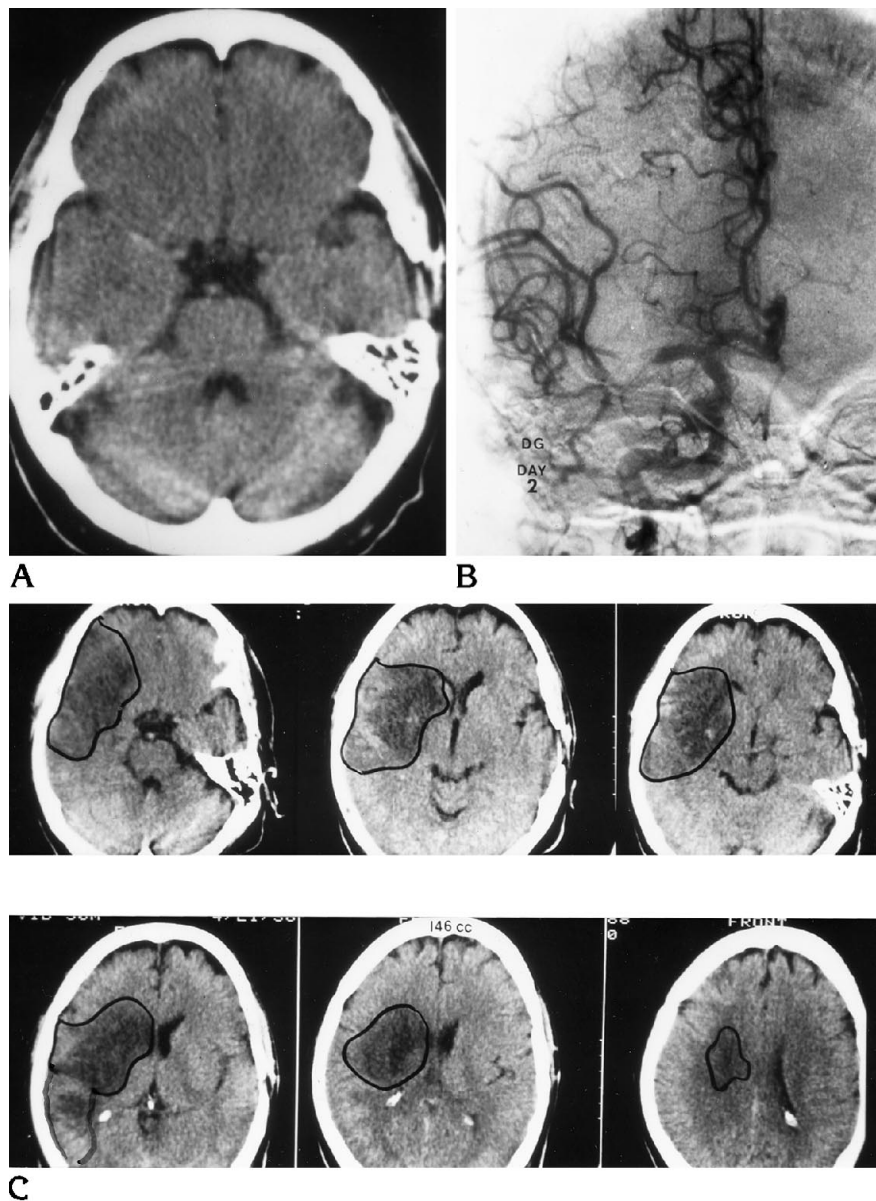


Fig 1. Patient with initial NIH stroke scale score of 15.

A, Hyperacute CT scan shows hyperdense right MCA involving distal M1 segment.

B, Arteriogram on day 2 after symptom onset shows distal M1 thrombus with incomplete occlusion.

C, CT scans on day 7 after symptom onset. Infarct volume at 7 days was 146 cm³. NIH stroke scale score at 3 months was 6.

the sign to clinical outcome. More recently, the HMCAS has been shown to be an ultraearly predictor of a large infarct and poor outcome (11, 12).

Comparison of acute stroke patients with the sign (HMCAS+) and without the sign (HMCAS-) in terms of baseline neurologic function and response to thrombolytic treatment might provide useful information about the sign's ability to predict neurologic deficit, immediate response to thrombolytic therapy, or

long-term differences in neurologic outcome. For example, if presence of the HMCAS identifies a group of patients who do more poorly than those not exhibiting the HMCAS, investigation of different treatment algorithms for stroke patients depending on the presence or absence of the sign might be warranted.

We report our findings at baseline neurologic examination, of initial response to intravenous alteplase therapy, and of long-term (3-month) outcome in 55 patients (18 with the HMCAS)

Baseline Stroke Scale Score, Median 3-mo Stroke Scale Score, Median Days to Arteriography, and Median Infarct Volume in Groups 1, 2, and 3

Group*	No. of Patients	Median Baseline Stroke Scale Score (Interquartile Range)	Median 3-mo Stroke Scale Score (Interquartile Range)	Median No. of Days to Posttreatment Arteriography (Interquartile Range)	Median Infarct Volume, cm ³ (Interquartile Range)
1	18	19.5 (15–21)	9 (5.8–14)	1 (1–2)	89 (49–178)
2	19	13 (12–17)	5 (1–21)	1 (1–1)	20 (4–94)
3	18	6 (5–8)	0.5 (0–3)	1 (1–4)	3 (0–13)

* Group 1 = patients with a hyperdense middle cerebral artery sign (HMCAS); group 2 = patients without an HMCAS and an initial stroke scale score of 10 or greater; group 3 = patients without an HMCAS and an initial stroke scale score of less than 10.

who were treated within 90 minutes of symptom onset.

Patients and Methods

Fifty-five patients with acute ischemic stroke were examined and treated within 90 minutes of symptom onset as part of a safety trial of intravenous alteplase therapy carried out at hospitals associated with three universities. All patients had CT to exclude cerebral hemorrhage and then were treated with intravenous alteplase within 90 minutes of symptom onset (13). No pretreatment arteriograms, which necessarily would delay therapy, were obtained. The trial was designed as an open-label dose-escalation study, and alteplase doses ranged from 22 mg to 87 mg. Patients were not excluded on the basis of the presumed ischemic stroke type (eg, lacunar and vertebro-basilar stroke patients were eligible), but patients older than age 80, patients with severe hypertension, and patients on anticoagulants were excluded. The neuroradiologist, who was aware of the presence of a suspected ischemic stroke but unaware of the nature of the deficit, reviewed the pretreatment CT scans and determined whether the HMCAS was present. CT signs of parenchymal ischemic changes were not specifically examined. The initial scans were obtained with a section thickness of 10 mm in 39 patients, 9 mm in one patient, 8 mm in 9 patients, and 5 mm in 6 patients. The different imaging protocols reflect the use of different CT scanners and standard CT protocols at the 12 participating hospitals. Infarct/edema volumes were measured in surviving patients by a cursor-trace technique (14) on subsequent scans at 18 to 24 hours, 7 to 10 days, and 3 months.

The patients were examined neurologically by means of the National Institutes of Health (NIH) stroke scale (15) immediately before alteplase treatment and at 2 hours, 24 ± 6 hours, 7 to 10 days, and 3 months. Neurologic improvement was defined as a rise in score of 2 or more points within 2 hours or 4 or more points within 24 hours. For analysis, NIH stroke scale scores in patients who died of infarct or hemorrhage were assigned a maximal number of 42. The NIH stroke scale score is zero for a healthy

patient and 42 for a comatose patient with all scale items maximally impaired. Patients' outcome was defined prospectively; at 3 months patients were classified as completely improved, partially improved, unchanged, worsened, or dead. At 3 months, patients with an NIH stroke scale score of 0 to 1 were classified as completely improved.

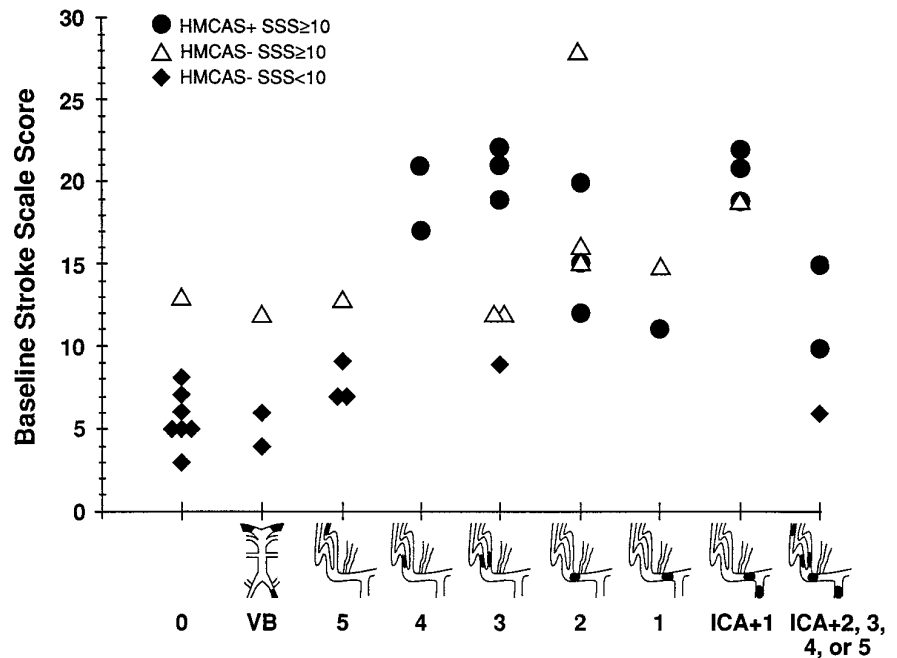
Data management and analysis were done using SAS software (SAS Institute; Cary, NC). The groups were compared by using the χ^2 or Wilcoxon's rank sum tests, as appropriate. Stepwise multiple logistic regression was used to analyze the factors affecting outcome at 3 months. A *P* value of less than .05 was considered significant.

Results

Of 55 patients treated with intravenous alteplase, 18 were HMCAS+ and 37 were HMCAS– on the side appropriate to their clinical findings. The patients with an HMCAS had a greater pretreatment neurologic deficit than those without the HMCAS. The median pretreatment NIH stroke scale score of HMCAS+ patients was 19.5 (interquartile range, 15 to 21) and that of HMCAS– patients was 10 (interquartile range, 6 to 14) (*P* = .001) (Table). None of the HMCAS+ patients had an NIH stroke scale score of less than 10. A typical patient with an NIH stroke scale score of 10 and left MCA occlusion might exhibit minimal drowsiness, minor facial paresis, no resistance to gravity with a right arm or leg, partial sensory loss, partial neglect, and mild dysarthria.

Within 30 minutes of the end of the alteplase infusion, 3 of the 18 HMCAS+ patients improved neurologically compared with 13 of the 37 HMCAS– patients (*P* = .08). By 24 hours, 6 of the 18 HMCAS+ patients had improved by 4 or more points on the NIH stroke scale compared with 16 of the 37 HMCAS– patients (*P* = .24).

Fig 2. Graph shows pattern of arterial occlusion (after treatment) versus initial stroke scale score (SSS) (modified from Saito et al [16]).



With regard to neurologic status at 3 months, the median NIH stroke scale score of the 18 HMCAS+ patients was 9 (interquartile range, 5.8 to 14) compared with a 3-month median stroke scale score in the 37 HMCAS- patients of 2 (interquartile range, 0 to 6) ($P = .002$). With regard to outcome at 3 months, only 1 of the 18 HMCAS+ patients was completely improved compared with 17 of the 37 HMCAS- patients ($P = .002$).

To examine whether the HMCAS was an important predictor of neurologic status or improvement independent of the initial neurologic deficit, the 18 HMCAS+ patients (all with NIH stroke scale scores ≥ 10) were compared with the 19 HMCAS- patients (all with NIH stroke scale scores ≥ 10) (the baseline median NIH stroke scale scores of these two groups were 19.5 and 13, respectively). There was no significant difference between the two groups with regard to the number showing early neurologic improvement within 2 hours after alteplase therapy or the number showing neurologic improvement by 24 hours ($P = .07$) nor the number showing major occlusive changes (internal carotid artery [ICA], M1, or M2) on the post-treatment arteriograms (14 of 14 vs 7 of 10; $P = .06$). Of the 18 patients with a stroke scale score under 10, 2 of 14 patients in whom arteriograms were obtained had occlusion of M1, M2, or the ICA after treatment ($P < .012$) (Fig 2).

At 3 months, the median NIH stroke scale score in the HMCAS+ patients was 9 (interquartile range, 5.8 to 14) whereas that in the HMCAS- patients with major initial deficits was 5 (interquartile range, 1 to 21) ($P = .33$). Only one of the HMCAS+ patients recovered completely compared with 5 of the 19 HMCAS- patients ($P = .09$) (Fig 3).

Radiographically, the HMCAS+ patients had a 3-month median infarct volume of 89 cm³ (interquartile range, 49 to 178 cm³) compared with 20 cm³ (interquartile range, 4 to 94 cm³) in the HMCAS- patients with major initial deficits ($P = .056$) (Fig 4). The HMCAS- patients with an NIH stroke scale score of less than 10 had a 3-month median infarct volume of 3 cm³ (interquartile range, 0 to 13 cm³), which is significantly lower than the 20 cm³ median for the HMCAS- patients with an NIH stroke scale score of 10 or more ($P = .006$) and lower than the 80 cm³ median for all patients with a stroke scale score of 10 or more.

Multiple logistic regression was used to assess the relative value of the HMCAS and the baseline stroke scale score to predict neurologic outcome. In this model, only the baseline scores dichotomized at less than 10 and at 10 or greater were significant ($P = .001$).

Three parenchymal hemorrhages occurred, all in HMCAS- patients (13). Two deaths occurred among HMCAS+ patients, both resulting

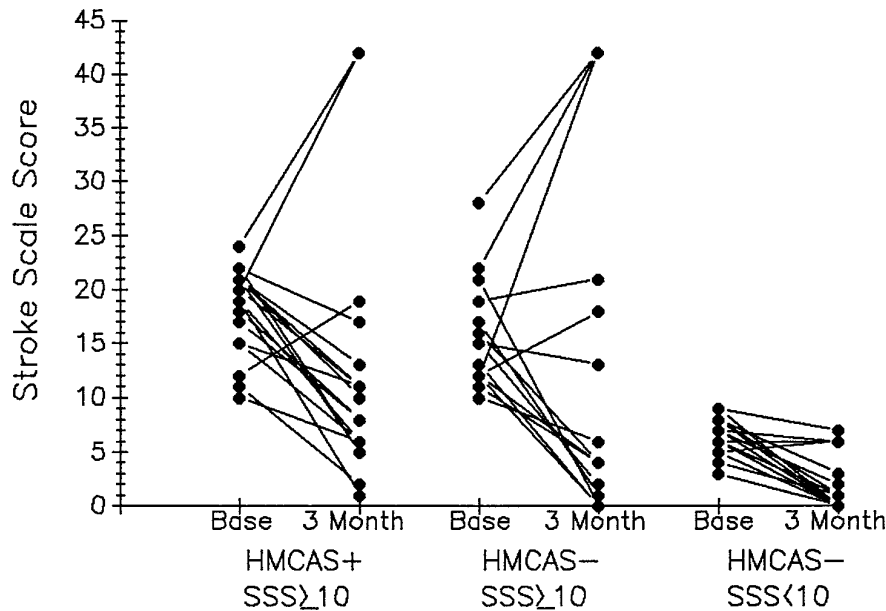


Fig 3. Graph shows changes in stroke scale score (SSS) from baseline to that at 3 months after treatment for group 1 (HMCAS+), group 2 (HMCAS-, initial score of 10 or more), and group 3 (HMCAS-, initial score of less than 10).

from the initial infarction. Six deaths occurred in HMCAS- patients, one associated with a complicating parenchymal hemorrhage, one after surgery for an asymptomatic aneurysm, one related to systemic cancer, and three resulting from the initial infarct.

Discussion

Identification of the HMCAS has been shown to have a high positive predictive value for detection of MCA thrombus on an arteriogram (6,

7, 11), although interobserver agreement in detection of the HMCAS is fair (17). The HMCAS has also been associated with volumetrically large infarcts (6, 7, 11). This study documents that the HMCAS is associated with large neurologic deficits (NIH stroke scale score ≥ 10) and a tendency toward poor response to experimental intravenous treatment with alteplase. However, the HMCAS does not occur in all patients with MCA occlusion (low sensitivity), and some patients with MCA occlusion without the sign will have equivalent deficits (Fig 2). For exam-

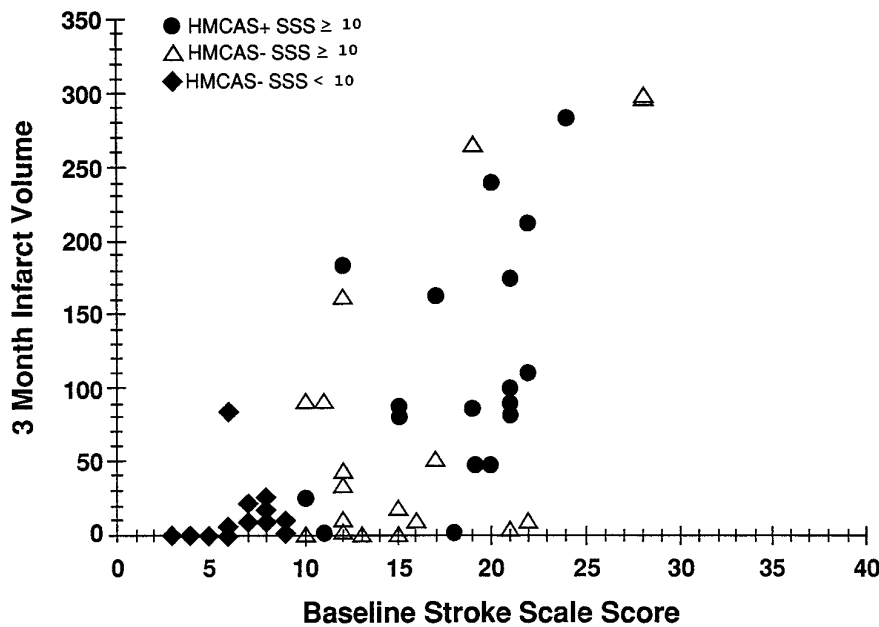


Fig 4. Graph shows initial stroke scale scores (SSS) versus infarct volume (cm³) for the three groups.

ple, in those without the sign but with major deficits, 7 (70%) of the 10 posttreatment arteriograms showed occlusion of the ICA or M1 or M2 segments of the MCA.

Insofar as 14 of 14 HMCAS+ patients who had posttreatment arteriography exhibited M1 or M2 occlusion, we believe the HMCAS is indeed a marker of MCA occlusion. There is legitimacy in identifying patients who have a stroke scale score known to be associated with MCA occlusion (HMCAS+ patients, or group 1), combining them with patients who have similar stroke scale scores (who also have a high likelihood of having MCA occlusions on arteriograms, group 2), and comparing them with patients who have lower stroke scale scores, who have a statistically significant difference ($P = .012$) in posttreatment anatomic occlusive changes of the ICA, M1, or M2 (Fig 2). In fact, our multiple logistic regression analysis confirmed that the stroke scale score was the best predictor of neurologic outcome at 3 months.

Our arteriographic data parallel the findings of Wolpert and colleagues (10), who performed arteriography before and after intravenous alteplase therapy (resulting in later treatment compared with that in our group). Their study showed immediate recanalization in only 19 (31%) of 60 MCA stems or divisions (M1 or M2), as compared with 8 (47%) of 17 recanalizations of MCA branches (M3–5).

The objection that arteriography was not performed before treatment in our study, so that the underlying pretreatment occlusive changes are unknown, is defused somewhat by the posttreatment arteriographic findings, wherein major occlusive ICA and MCA changes were still present in 23 (61%) of 38 patients, compared with 59 (66%) of the 89 patients in the study by Wolpert et al.

That the HMCAS+ patient has a less optimistic prognosis is shown by the unlikelihood of a complete recovery (NIH stroke scale score of 0 to 1) at 3 months compared with the prognosis for all HMCAS– patients ($P = .002$) and for group 2 HMCAS– patients with major initial neurologic deficits ($P = .09$) (Fig 3). In addition, the 3-month infarct volumes in the HMCAS patients were larger than those in the HMCAS– patients with baseline NIH stroke scale scores of 10 or more ($P = .056$) and the latter volumes were significantly larger than those in the HMCAS– patients with an NIH stroke scale score of less than 10 ($P = .03$) (Fig 4).

In patients with a stroke scale score of 10 or more (groups 1 and 2), intravenous alteplase therapy, in the doses studied, resulted in infrequent early neurologic recovery. All patients who had an NIH stroke scale score of 24 or more ($n = 3$) died. Patients with an NIH stroke scale score of 20 to 22 ($n = 10$) had a 20% mortality rate, and there was a large median residual neurologic deficit of 11 (interquartile range, 5 to 17) in surviving patients at 3 months. Among the patients with an NIH stroke scale score of 10 or more, neurologic recovery occurred in only 1 of 18 with the HMCAS and in only 2 of 19 without the HMCAS. Whether this differs from natural history (18) of stroke patients with major initial deficits may be learned from the ongoing randomized trials of alteplase. Preliminary results from the European acute stroke study of intravenous alteplase indicate potential benefit for carefully selected patients (19). However, a retrospective analysis of patients with subtle signs of infarction involving more than one third of the symptomatic MCA territory already evident on the pretreatment CT scan indicated that those patients did not benefit from intravenous therapy within 6 hours. The number of those patients who had either the HMCAS and/or a major neurologic deficit has not yet been reported. If results from the European study and the other randomized trials of intravenous alteplase confirm limited improvement in patients with major deficits, more aggressive intraarterial thrombolysis and/or mechanical thrombus manipulation would be justified.

HMCAS– patients with minor initial neurologic deficits (NIH stroke scale score of less than 10; group 3) make, as expected, a better neurologic recovery than do HMCAS+ patients ($P < .001$). Two thirds of the former had an NIH stroke scale score of 0 or 1 at 3 months. Arteriography was performed after treatment in 14 of these patients within days of ictus, and major posttreatment occlusions were less frequent than in patients who had major deficits ($P = .012$), indicating a lesser vascular-occlusive process. Whereas more proximal, well-collateralized thrombi may have lysed, it is also possible that smaller, more distal thrombi were present at onset (10). A recently completed NIH-sponsored double-blind study may help answer the question as to the risk-benefit ratio of intravenous alteplase in this group with modest neurologic deficits at the time of symptom

onset. Our results suggest the hypothesis that the randomized trials could show that ultraearly intravenous thrombolytic therapy may be adequate for this group.

We conclude that the HMCAS is uniformly associated with a high initial NIH stroke scale score (≥ 10) and that an NIH stroke scale score of 10 or more is associated with continuing higher scores within 24 hours or at 3 months after intravenous alteplase treatment, whether or not the HMCAS is present. HMCAS+ patients are unlikely to have recovered at 3 months, and they exhibit larger infarct volumes compared with HMCAS- patients after intravenous alteplase treatment. Patients with low NIH stroke scale scores (< 10) have either normal findings on arteriograms or small-vessel occlusions on delayed posttreatment arteriograms and recover more completely after intravenous alteplase treatment.

Stratification of patients for arteriographic diagnosis and treatment according to their NIH stroke scale score is a strategy that should be considered in future stroke treatment studies.

References

- Gacs G, Fox AJ, Barnett HJM, Vinuela F. CT visualization of intracranial arterial thromboembolism. *Stroke* 1983;14:756-762
- Pressman BD, Tourje EJ, Thompson JR. An early CT sign of ischemic infarction: increased density in a cerebral artery. *AJNR Am J Neuroradiol* 1987;8:645-648
- Schuijter G, Huk W. The unilateral hyperdense middle cerebral artery: an early CT-sign of embolism or thrombosis. *Neuroradiology* 1988;30:120-122
- Tomsick TA, Brott TG, Olinger CP, et al. Hyperdense middle cerebral artery: incidence and quantitative significance. *Neuroradiology* 1989;31:312-315
- Schuknecht B, Ratzka M, Hofman E. The dense artery sign: major cerebral thromboembolism demonstrated by computed tomography. *Neuroradiology* 1990;32:98-103
- Bastianello S, Perallini A, Colonnese C, et al. Hyperdense middle cerebral artery CT sign. *Neuroradiology* 1991;33:207-211
- Tomsick TA, Brott T, Barsan W, et al. Thrombus localization with emergency cerebral computed tomography. *AJNR Am J Neuroradiol* 1992;13:257-263
- Ricci S, Caputo N, Aija G, et al. Prognostic value of the dense middle cerebral artery sign in patients with acute ischemic stroke. *Ital J Neurol Sci* 1991;12:45-47
- Leys D, Pruvo JP, Godefroy D, Rondepierre P, Leclerc X. Prevalence and significance of hyperdense middle cerebral artery in acute stroke. *Stroke* 1992;23:317-324
- Wolpert SM, Bruckman H, Greenlee R, et al. Neuroradiologic evaluation of patients with acute stroke treated with recombinant tissue plasminogen activator. *AJNR Am J Neuroradiol* 1993;14:3-13
- von Kummer R, Meyding-Lamade U, Forsting M, et al. Sensitivity and prognostic value of early CT in occlusion of the middle cerebral artery trunk. *AJNR Am J Neuroradiol* 1994;15:9-15
- Tomsick T. Sensitivity and prognostic value of early CT in occlusion of the middle cerebral artery trunk. *AJNR Am J Neuroradiol* 1994;15:16-18
- Brott T, Haley EC, Levy DE, et al. Urgent therapy for stroke. Part I. Pilot study of tissue plasminogen activator administered within 90 minutes. *Stroke* 1992;23:632-640
- Brott T, Marler JR, Olinger CP, et al. Measurements of acute cerebral infarction: lesion size by computed tomography. *Stroke* 1989;20:871-875
- Brott T, Adams HP, Olinger CP, et al. Measurements of acute cerebral infarction: a clinical exam scale. *Stroke* 1989;20:864-870
- Saito I, Segawa H, Shiokawa Y, Taniyuchi M, Tsutsum K. Middle cerebral artery occlusion: correlation of computed tomography and angiography with clinical outcome. *Stroke* 1987;18:863-888
- Tomsick TA, Brott TG, Chambers AA, et al. Hyperdense middle cerebral artery sign on CT: efficacy in detecting middle cerebral artery thrombosis. *AJNR Am J Neuroradiol* 1990;11:473-477
- Biller J, Love BB, Marsh EE, et al. Spontaneous improvement after acute ischemic stroke: a pilot study. *Stroke* 1990;21:1008-1012
- Hacke W, Kaste M, Fieschi C for the ECASS Study Group. Intravenous thrombolysis with recombinant tissue plasminogen activator for acute hemispheric stroke: the European Cooperative Acute Stroke Study (ECASS). *JAMA* 1995;274:1017-1059