

Are your **MRI contrast agents** cost-effective?

Learn more about generic **Gadolinium-Based Contrast Agents**.



FRESENIUS
KABI

caring for life

AJNR

Induction and subsequent rupture of aneurysms of the circle of Willis after radiation therapy in Ehlers-Danlos syndrome: a plausible hypothesis.

A I Holodny, M Deck and C K Petito

AJNR Am J Neuroradiol 1996, 17 (2) 226-232

<http://www.ajnr.org/content/17/2/226>

This information is current as of April 16, 2024.

Induction and Subsequent Rupture of Aneurysms of the Circle of Willis after Radiation Therapy in Ehlers-Danlos Syndrome: A Plausible Hypothesis

Andrei I. Holodny, Michael Deck, and Carol K. Petito

Summary: Multiple aneurysms of the circle of Willis developed in a 62-year-old woman with Ehlers-Danlos syndrome (EDS) within 7 months of initiation of radiation therapy to the brain. A major response of the arterial wall to radiation damage is the formation of collagen. In patients with EDS, in whom there is a defect in collagen, this repair is incomplete. We propose that the incomplete repair of the arterial wall consequent to EDS resulted in weakness of these walls, formation of an aneurysm, and, ultimately, fatal subarachnoid hemorrhage.

Index terms: Aneurysm, cerebral; Ehlers-Danlos syndrome; Iatrogenic disease or disorder; Therapeutic radiology, complications

One of the most common uses of radiation therapy is in the treatment of head, neck, and neurologic tumors. However, this therapy often is accompanied by a number of undesirable side effects (1). Some patients are more susceptible to the damaging effects of radiation therapy than others. In these patients, the threshold for such effects is reached at a much lower dose, and if they undergo a standard course of radiation therapy, the damaging side effects may greatly outweigh the potential benefit. It is important to identify such patients and plan their therapy accordingly, modifying or perhaps even totally eliminating radiation therapy.

We present a case of a woman with metastatic breast cancer and Ehlers-Danlos syndrome (EDS) in whom a rare complication of radiation therapy to the brain developed.

Case Report

A 62-year-old woman had a right-sided radical modified mastectomy for infiltrating ductal breast carcinoma 26

months antemortem. Six months later, a metastatic nodule appeared on the right side of the chest wall above the mastectomy wound. Local radiation of approximately 10 Gy was given but was discontinued when an idiosyncratic hypersensitivity reaction developed, manifested by pericarditis, pleuritis, and mediastinitis. These symptoms resolved after the radiation therapy was discontinued. The patient was treated with tamoxifen. Seven months antemortem, occipital headaches developed. A magnetic resonance (MR) examination at that time revealed multiple enhancing lesions consistent with metastases but no abnormalities of the circle of Willis. Specifically, the basilar tip was of normal size (Fig 1A and B). Soon after, she was treated with dexamethasone and began a course of wide-beam radiation therapy, in which she received a total of 21 Gy over 14 treatments. Three months antemortem, she received an additional 10.8 Gy of wide-beam radiation therapy over six treatments without apparent complications. An MR image showed a reduction in the size of the metastases and peritumoral edema. The circle of Willis was also judged to be normal. However, when comparing this image with the previous one, a slight enlargement could be seen in the tip of the basilar artery (Fig 1C and D). Her subsequent course was complicated by recurrent pulmonary emboli and steroid myopathy.

The patient's medical history was significant for hyperextensible joints, hyperelastic skin, and a separation of the pubic symphysis during parturition. Her children have similar symptoms. The patient, who was an academic physician, postulated a diagnosis of EDS.

Three weeks antemortem, she was admitted for terminal care. Physical examination was notable for mild cognitive impairment, hyperextensible finger joints, a question of hyperelastic skin, and generalized weakness. An MR image showed further enlargement of the basilar artery tip, which measured slightly under 1 cm (Fig 1E and F). Four days after admission, the patient suffered a generalized seizure. After this, she became stuporous and over a few days progressed to a deep coma. In keeping with the wishes of the patient and her family, no further diagnostic

Received August 4, 1994; accepted after revision June 12, 1995.

From the Departments of Pathology (Neuropathology) (A.I.H., C.K.P.) and Radiology (M.D.), The New York Hospital-Cornell University Medical College, New York, NY.

Address reprint requests to Andrei I. Holodny, MD, Department of Radiology, New York University Medical Center, 550 First Ave, New York, NY 10016.

AJNR 17:226-232, Feb 1996 0195-6108/96/1702-0226 © American Society of Neuroradiology

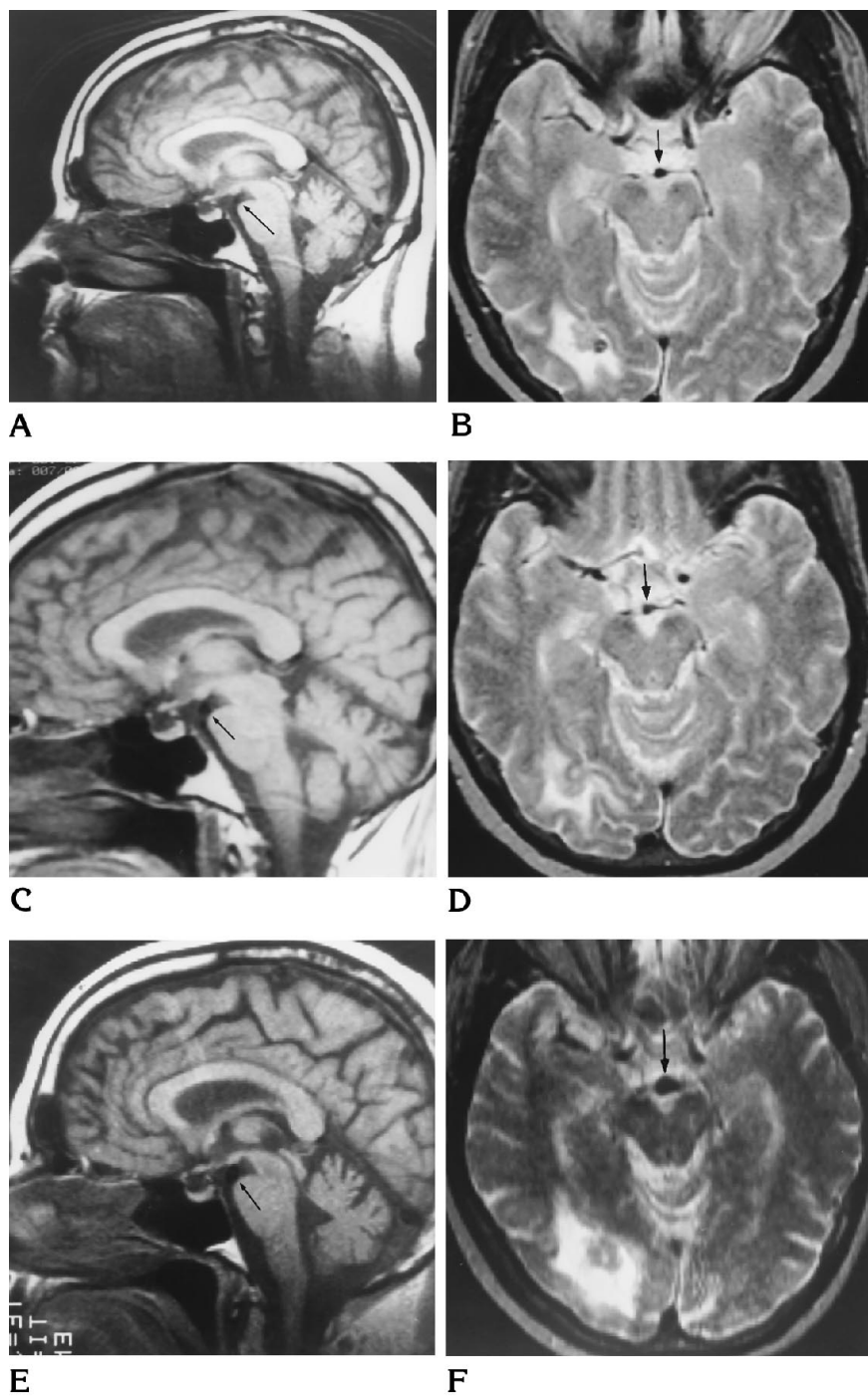


Fig 1. A and B, Sagittal T1-weighted (500/20 [repetition time/echo time]) (A) and axial T2-weighted (2000/80) (B) MR images obtained 7 months antemortem show a normal-appearing tip of the basilar artery (arrows). The T2-weighted image also shows a metastatic focus with surrounding edema in the right parietooccipital lobe.

C and D, Sagittal T1-weighted (500/20) (C) and axial T2-weighted (2000/80) (D) MR images obtained 4 months antemortem show slight enlargement of the basilar tip (arrows).

E and F, Sagittal T1-weighted (500/20) (E) and axial T2-weighted (2000/80) (F) MR images obtained 2 weeks antemortem show a basilar tip aneurysm that measures slightly under 1 cm (arrows). Figure continues.

tests or medical intervention, except supportive care, were provided. She died 16 days after the seizure.

Autopsy Findings

An autopsy revealed multiple brain metastases that were microscopically consistent with the primary breast lesion. A large, fresh subarachnoid hemorrhage was located at the base of the brain and extended over the

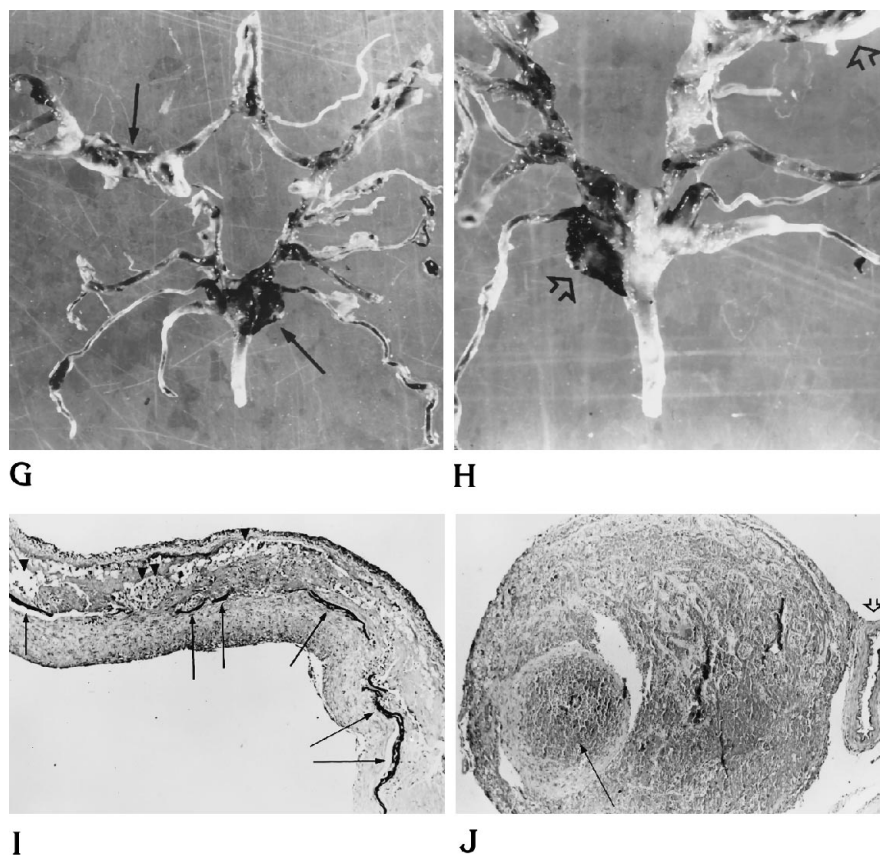
parietal and occipital lobes and the posterior cerebellum. Microscopic sections revealed fresh blood and occasional hemosiderin-laden macrophages.

The circle of Willis was complete, although the posterior cerebral arteries were continuations of the posterior communicating arteries. A focally ectatic aneurysmal dilatation measuring approximately 1 cm was present at the basilar tip. A rupture site was identified in the apical wall of this aneurysm (Fig 1G and H). The proximal right superior

Fig 1, *continued*.

G and *H*, Pathologic specimens. Ventral (*G*) and dorsal (*H*) views of the circle of Willis with aneurysmal dilatation of the tip of the basilar artery and ectasia of the right middle cerebral artery (*arrows*).

I and *J*, Photomicrographs. In *I*, the ectatic portion of the M1 segment of the right middle cerebral artery shows focal areas of necrosis (*arrowheads*) and a disrupted elastic lamina (the elastic lamina is the dark linear structure running down the middle of the arterial wall, outlined by the *arrows*). (Van Gieson's elastic stain; magnification $\times 63$.) In *J*, a thrombosed saccular aneurysm is seen adjacent to a lenticulostriate artery (*open arrow*) from which it arose. (The thrombus is pointed out by the *long arrow*.) (Hematoxylin-eosin stain; magnification $\times 63$.)



cerebellar artery and M2 segment of the right middle cerebral artery were focally ectatic. In addition, four saccular aneurysms of the circle of Willis, measuring approximately 0.2 cm, were identified. These aneurysms arose from the junctions of 1) the basilar, left posterior communicating and left superior cerebellar arteries, and 2) the right anterior cerebral and anterior communicating arteries. Two other such aneurysms arose at the junctions of the right middle cerebral and lenticulostriate arteries. Microscopic examination of the ectatic aneurysms revealed necrosis of the media with numerous lipid-laden macrophages and mononuclear inflammatory cells, focal disruption of the elastic lamina, and intimal fibrosis. The saccular aneurysms had thin collagenous walls with loss of elastica and media. The elastic stain showed focal disruption of the elastica (Fig 1I and J). Other vessels of the circle of Willis, which appeared grossly normal, also showed focal disruption of the elastic lamina, with and without calcification.

Other blood vessels in the leptomeninges and the brain parenchyma, as well as small, medium, and large systemic vessels, were histologically unremarkable. Electron microscopy of the basilar artery showed normal-appearing collagen bundles. Gross and microscopic examination of both lungs and the heart revealed mild pleural thickening but no apparent difference between the right and left sides.

Discussion

The patient presented with multiple intracranial aneurysms that were caused by a necrotizing arteritis that was confined to the large arteries at the base of the brain. Vascular changes ranged from intimal thickening and focal loss of the elastic lamina to frank necrosis of the entire arterial wall. Review of the MR images indicated that at least the basilar aneurysm appeared during the final 3 months of life.

There were two predisposing factors in this patient that, alone or in combination, may have caused the vascular changes in the circle of Willis: EDS and radiation therapy.

EDS is a disorder of the connective tissue that usually manifests as joint hyperextensibility and skin hyperelasticity. Ten subtypes have been identified, of which the biochemical defect has been identified in five (2). Nevertheless, it is thought that the clinical symptomatology of all these types is the result of some type of defect in collagen (2, 3).

Of all the types of EDS, only type IV (also known as the vascular form) has been associated with systemic or cerebral aneurysms (4–7). None of the other forms have been associated with aneurysm formation (4–7). This patient was never fully worked up for her EDS, and her type was never precisely determined during her lifetime. Nevertheless, for the purposes of this discussion, it is important to exclude the possibility that she was afflicted with EDS type IV. After a review of her chart, discussion with a number of her clinicians, and review of the autopsy findings, it is strongly believed that EDS type IV could be excluded owing to the following considerations. EDS type IV is characterized by a deficiency in type III collagen. Blood vessels and the intestines are rich in collagen type III. Therefore, a deficiency in this type of collagen results in fragility of the blood vessels and bowel. The major complications of EDS type IV are extensive systemic aneurysms, arterial dissection, and bowel rupture (3). This patient presented with multiple aneurysms restricted to the circle of Willis. Her systemic arteries were normal on both gross and histologic examination. There was no evidence of either aneurysm formation or dissection. It would seem highly unlikely that a systemic process such as EDS type IV would produce such focal findings. In addition, patients with EDS type IV almost always present with complications caused by arterial disease at a much earlier age than this patient (4–7). This patient did not have any of the other characteristics of type IV, such as readily visible veins over the trunk, abdomen, legs, and arms; ecchymosis with minor trauma; bowel rupture; or uterine rupture during pregnancy (8). Vessel necrosis, which developed in this patient, is not a characteristic of EDS type IV (9).

On the basis of the clinical history and the pathologic findings, we concluded that this patient probably had EDS type III, and possibly type II. EDS type I is characterized by “cigarette paper scars,” varicose veins, hernias, premature rupture of fetal membranes and early onset of osteoarthritis. This patient did not have any of these findings. The inheritance pattern of EDS type V is X-linked and, therefore, unlikely to appear in a woman. In addition, patients with EDS type V have a floppy mitral valve. This patient’s mitral valve was normal. Patients with EDS type VI (the ocular form) have ocular fragility, keratoconus, and scoliosis, which were

not seen in this patient. Patients with EDS type VII (arthrochalasia multiplex congenita) have marked joint hyperextensibility, congenital hip dislocation, peculiar “scooped out” facies with epicanthal folds and hypertelorism, and short stature. This woman was 162 cm tall (5 ft 4 in). She did not have congenital hip dislocation or the described facial anomalies. Patients with EDS type VIII (periodontal form) have marked skin fragility, atrophic pigmented scars, and generalized periodontitis. This patient did not have these findings. Patients with EDS type IX have bladder diverticulae and rupture, and rhizomelic shortening of the arms. The bladder and osseous structures of the arms of this patient were normal. EDS type X is extremely rare and is characterized by an abnormality in platelet aggregation (2). As far as we are aware, this patient did not have any hematologic abnormality.

The fact that the patient had normal-appearing collagen fibers in the basilar artery was not entirely unexpected. Black et al (10) reported that the ultrastructure of collagen fibers in patients with EDS is normal. Others (11–13) have reported differences in the ultrastructure of collagen between patients with EDS and control-subjects. Notwithstanding, it is generally agreed that it is impossible to make a diagnosis of a specific type of EDS by electron microscopy (11, 12). Unfortunately, these studies have been done on collagen from the skin and not from the blood vessels. The collagen composition of the skin differs from that of the arteries. As far as we are aware, studies on the ultrastructure of collagen in vessel walls of patients with EDS have not been performed.

The radiologic findings also help to exclude EDS of any type as the single cause of this patient’s aneurysms. Imaging findings showed that these aneurysms most probably developed during the last months of her life, at the age 62. As far as we know, such late development has never been reported in EDS of any type. Therefore, the pattern of development of this patient’s aneurysms is not characteristic of any type of EDS previously described. One can, therefore, almost certainly conclude that EDS was not the sole cause of the ruptured aneurysms. On the other hand, the temporal relationship between the development of the aneurysms and the radiation therapy was well established by the sequential MR images. It has been known since shortly after its discovery that radiation causes

damage to arteries (14). Classically, this damage has taken two forms: the first, and by far the most frequent, is stenosis or occlusion, histologically similar to atherosclerosis; the second is rupture.

A number of studies have characterized a pattern of response of large arteries to high doses of radiation (15–17). Initially, radiation primarily appears to affect the endothelial cells, apparently sparing the media and adventitia. Over a period of time, usually on the order of weeks to months, these changes progress to involve all the arterial wall layers. Intimal changes, first described by Sheehan (18), result in plaquelike thickening resulting from a collection of inflammatory cells, fluid, fibrin, or hyalin material located between the intimal elastic membrane and the endothelium. These plaques have been described as being indistinguishable from atherosclerosis (19). Changes in the media are characterized by fragmentation of the elastic lamina and cystic medial necrosis as well as concurrent increase in cellularity, overproduction of elastic tissue, hyalin thickening, production of collagen, and resultant fibrosis.

This combination of intimal plaques and medial thickening, resulting from fibrosis, is known to cause narrowing and even obliteration of vessel lumina. On rare occasions, strokes resulting from radiation damage to the carotid artery have been described (20). This has even been reported in a 25-year-old woman with no other evidence of atherosclerosis (21). In the vast majority of patients, the changes induced in the arterial wall by radiation damage stabilize without clinical sequelae (21–23).

The origin of aneurysms is not completely understood. Forbus (24) first proposed that aneurysms arise in areas of focal weakness in the arterial wall subsequent to congenital weakness in the media. Glynn (25) proposed that focal degeneration of the internal elastic lamina due to atherosclerosis or other factors was the most important factor in the development of aneurysms. In radiation-induced damage to the arterial wall, both of these structures—the media and the internal elastic lamina—are damaged. This is seen pathologically as cystic medial necrosis and fragmentation of the internal elastic lamina. This causes a weakening of the arterial wall that can lead to dilatation or rupture. However, both histopathologic studies (25–28) and experimental animal studies (29, 30) have shown that in non-radiation-induced aneu-

rysms, fibrosis of the intima can prevent the formation of an aneurysm even in the presence of lesions involving the media and the internal elastic lamina. In radiation-damaged vessels, Gomori et al (31) proposed a similar mechanism, in which the tendency of a vessel to dilate and form an aneurysm is held in check by the fibrotic response and the formation of a scar. Saccular aneurysm formation resulting from radiation therapy is a rare occurrence (32), probably because the fibrotic response is able to compensate for the radiation-induced weakness in the arterial wall (31). For aneurysms to develop, an additional pathologic process is necessary—one that interferes with the fibrosis and healing that normally occur, which in turn prevent the formation of an aneurysm (31). When such a pathologic process is present, aneurysm formation and rupture can occur. A number of such factors have been described.

Pence et al (33) described seven patients in whom cerebral aneurysms or cerebrovascular accidents developed 9 to 20 years after radiation therapy. These patients (ages 2½ to 13 years) all received on the order of 50 Gy whole brain radiation and 35 Gy spine radiation, as well as 10 to 45 mCi intrathecal aurum (gold)-198. It was the contention of the authors that the major cause of the vascular maladies was pooling of the radioactive gold in the basal cisterns. This pooling caused an uneven distribution of the radioisotope, which led to a much larger dose delivered to the area of the circle of Willis. The dose received by the subject of this article was at least three times smaller, yet her fatal aneurysms developed significantly earlier: 4 months as opposed to 9 to 20 years. Autopsies were done in three of the patients described by Pence et al, and the gross and microscopic findings were similar to the findings presented here (33).

Gomori et al (31) reported a case of a patient in whom an ectatic, fusiform aneurysm of the basilar artery developed 3 years after treatment with 60 Gy of external-beam radiation for squamous cell carcinoma of the sphenoid sinus. However, the authors thought the aneurysm was caused by tumor compression or invasion. The patient died of rupture of this aneurysm. Unfortunately, an autopsy was not performed to confirm the suspicions of the authors. In the patient who is the subject of this article, tumor was not identified in the area of the circle of Willis.

Azzarelli et al (34) reported a case of a 17-year-old girl who died of a ruptured aneurysm of the circle of Willis 5 years after receiving 52.2 Gy for a suprasellar germinoma. Multiple fusiform aneurysms of the circle of Willis were noted as early as 3 years 8 months after therapy. The patient had a number of hormonal abnormalities resulting from surgery in the area of the pituitary, which the authors thought contributed to aneurysm formation. In addition, these authors believed that the youth of the patient probably was also a risk factor. This contention is supported by experimental animal data that show that radiation-induced arteriosclerotic changes occurred readily in young mice, whereas older mice seemed to be unaffected (35). Again, the subject of our study had none of the risk factors mentioned; pediatric age group, pituitary abnormalities, or surgery in the immediate area. She received less radiation and yet an aneurysm developed and ruptured an order of magnitude earlier, 7 months as opposed to 44 months.

McCready et al (22) described 11 patients who suffered carotid artery "blowouts" on the order of weeks to months after radiation to the neck. These patients all had head and neck tumors and received at least 50 Gy of radiation. In addition, all had had surgery 1 to 20 weeks before the "blowout" and, perhaps most important, all had infection in the area of the ruptured artery. The authors concluded that infection plays an extremely important role in arterial rupture.

In summarizing the literature, it can be stated that a number of factors have been identified that place a patient who is undergoing radiation therapy at risk for arterial aneurysms or rupture. The subject of this article had none of these factors, yet aneurysm rupture occurred shortly after radiation therapy. Patients who have had recent surgery and an infection in the immediate area of an extracerebral artery have been reported (22) to have arterial rupture as early as this patient. Therefore, it would seem that she had a significant risk factor for the development of aneurysms.

Collagen formation is a major component of any fibrotic response (36), including the response to radiation damage (37, 38). Collagen is the major contributor to the tensile strength of a scar (36). Specifically, it has been shown in experimental animals that there is a dramatic increase in collagen in response to doses of

radiation in the range received by this patient (37, 38). As stated earlier, it has been shown that the formation of intimal fibrosis can prevent the formation of an aneurysm (24, 27-30). EDS is due to a defect in collagen. Therefore, it is hypothesized that in this patient with a defect in collagen consequent to EDS, the healing fibrotic response in arteries damaged by radiation was suboptimal. Because this patient lacked the fibrotic response and resultant tensile strength of a normal healing or healed artery, aneurysms developed much more rapidly than previously reported. Also, the patient's inherent defect in collagen may have made her vessels more sensitive to smaller doses of radiation, which are relatively well tolerated by patients with normal collagen production. It appears that patients with EDS type III (or possibly type II) are at risk for aneurysm formation and rupture if they undergo radiation therapy at tumoricidal doses.

This case warrants further investigation into the effects of radiation damage in patients with EDS.

Acknowledgments

We thank Drs Ajax E. George, Alex Berenstein, and Gleb N. Budzilovich for their helpful suggestions.

References

1. Sheline GE, Wara WM, Smith V. Therapeutic irradiation and brain injury. *J Radiat Oncol Biol Phys* 1980;6:1215-1228
2. Byers PH, Holbrook KA. Molecular basis of clinical heterogeneity in the Ehlers-Danlos syndrome. *Ann NY Acad Sci* 1986;460:298-310
3. Wagner BM, Fleischmajer R, Kaufman N. *Connective Tissue Diseases*. Baltimore: Williams & Wilkins, 1983:32-39
4. Rubinstein MK, Cohen MH. Ehlers-Danlos syndrome associated with multiple intracranial aneurysms. *Neurology* 1964;14:125-132
5. Graf CJ. Spontaneous carotid-cavernous fistula. Ehlers-Danlos syndrome and related conditions. *Arch Neurol* 1965;13:662-672
6. Schoolman A, Kepes JJ. Bilateral spontaneous carotid-cavernous fistulae in Ehlers-Danlos syndrome: case report. *J Neurosurg* 1967;26:82-86
7. Lach B, Nair SG, Russell NA, Benoit BG. Spontaneous carotid-cavernous fistula and multiple arterial dissections in type IV Ehlers-Danlos syndrome. *J Neurosurg* 1987;66:462-467
8. Gertsch P, Loup PW, Lochman A, Anani P. Changing patterns in the vascular form of Ehlers-Danlos syndrome. *Arch Surg* 1986; 121:1061-1064
9. Silver MD. *Cardiovascular Pathology*. New York: Churchill Livingstone, 1983:963
10. Black CM, Gathercole LJ, Bailey AJ, Beighton P. The Ehlers-Danlos syndrome: an analysis of the structure of the collagen fibres of the skin. *Br J Dermatol* 1980;102:85-96

11. Gertsch P, Loup PW, Lochman A, Anani P. Changing patterns in the vascular form of Ehlers-Danlos syndrome. *Arch Surg* 1986; 121:1061-1064
12. Sevenich M, Schultz-Ehrenburger U, Orfanos CE. Ehlers-Danlos Syndrom: Eine Fibroblasten- und Kollagenkrankheit: Typisierung und elecyronelektromikroskopische Befunde bei Funf Kranken. *Arch Dermatol Res* 1980;267:237-251
13. Pierard GE, Pierard-Franchimont CM, Lapiere CM. Histopathological aid in the diagnosis of Ehlers-Danlos syndrome, gravis and mitis types. *Int J Dermatol* 1983;22:300-304
14. Gassman A, Zur Histologic der Roentgenulcere. *Fortschr Geb Rontgenstr Nuklearmed Ergänzungsbd* 1899;2:199
15. Warren S. Effects of radiation on normal tissues, VI: effects of radiation on the cardiovascular system. *Arch Pathol* 1942;34: 1070-1089
16. Fonkalsrud EW, Sanchez M, Zerubavel R, Mahoney A. Serial changes in arterial structure following radiation therapy. *Surg Gynecol Obstet* 1977;145:395-401
17. Elerding SC, Fernandez RN, Grotta JC, et al. Carotid artery disease following external cervical irradiation. *Ann Surg* 1981;194: 609-615
18. Sheehan JF. Foam cell plaques in the intima of irradiated small arteries. *Arch Pathol* 1944;37:297-307
19. Moss WT, Brama WN, Battifora H. *Radiation Oncology, Rationale, Technique, Results*. St. Louis: Mosby, 1973:248-256
20. Werner MH, Burger PC, Heinz ER, et al. Intracranial atherosclerosis following radiotherapy. *Neurology* 1988;38:1158-1160
21. Conomy JP, Kellermeyer RW. Delayed cerebrovascular consequences of therapeutic radiation. *Cancer* 1975;36:1702-1708
22. McCready RA, Hyde GL, Bivins BA, et al. Radiation-induced arterial injuries. *Surgery* 1983;93:306-312
23. Wang CC. *Radiation Therapy for Head and Neck Malignancies*. Chicago: Year Book, Medical, 1990:402
24. Forbus WD. On the origin of miliary aneurysms of the superficial cerebral arteries. *Bull Johns Hopkins Hosp* 1930;47:239-284
25. Glynn LE. Medial defects in the circle of Willis and their relation to aneurysm formation. *J Pathol Bacteriol* 1940;51:213-222
26. Sekhar LN, Heros RC. Origin, growth, and rupture of saccular aneurysms: a review. *Neurosurgery* 1981;8:248-260
27. Carmichael R. Gross defects in the muscular and elastic coats of the larger cerebral arteries. *J Pathol Bacteriol* 1945;57:345-351
28. Carmichael R. The pathogenesis of non-inflammatory cerebral aneurysms. *J Pathol Bacteriol* 1950;62:1-19
29. Goetz RH, Weissberg D, Hoppenstein R. Vascular necrosis caused by application of methyl 2-cyanoacrylate (Eastman 910 monomer): 7-month followup in dogs. *Ann Surg* 1966;163:242-248
30. Troupp H, Rinne T. Methyl-2-cyanoacrylate (Eastman 910) in experimental vascular surgery: with a note on experimental arterial aneurysms. *J Neurosurg* 1964;21:1067-1069
31. Gomori JM, Levy P, Weshler Z. Radiation induced aneurysm of the basilar artery: a case report. *Angiology* 1987;38:147-150
32. Benson PJ, Sung JH. Cerebral aneurysms following radiotherapy for medulloblastoma. *J Neurosurg* 1989;70:545-550
33. Pence DM, Kim TH, Levitt SH. Aneurysm, arachnoiditis and intrathecal Au (gold). *Int J Radiat Oncol Biol Phys* 1990;18:1001-1004
34. Azzarelli B, Moore J, Gilmore R, et al. Multiple fusiform intracranial aneurysms following curative radiation therapy for suprasellar germinoma. *J Neurosurg* 1984;61:1141-1145
35. Smith C, Loewenthal LA. A study of elastic arteries in irradiated mice of different ages. *Proc Soc Exp Biol Med* 1950;75:859-861
36. Cotran RS, Kuma V, Robbins SL. *Robbins Pathological Basis of Disease*. 5th ed. Philadelphia: Saunders, 1994:86-91
37. Miller GG, Kenning JM, Dawson DT. Radiation-induced changes in collagen isotypes I, III and IV in the lung of LAF₁ mouse: effects of times, dose and WR-2721. *Radiat Res* 1988;115:515-532
38. Panizzon RG, Hanson WR, Schwartz DE, Malkinson FD. Ionizing radiation induces early, sustained increases in collagen biosynthesis: a 48-week study in mouse skin and skin fibroblast cultures. *Radiat Res* 1988;116:145-156