

Are your **MRI contrast agents** cost-effective?

Learn more about generic **Gadolinium-Based Contrast Agents**.



FRESENIUS  
KABI

caring for life

# AJNR

## **Trigeminal-cavernous fistula: Saltzman anatomy revisited.**

J D McKenzie, B L Dean and R A Flom

*AJNR Am J Neuroradiol* 1996, 17 (2) 280-282

<http://www.ajnr.org/content/17/2/280>

This information is current as  
of April 20, 2024.

---

# Trigeminal-Cavernous Fistula: Saltzman Anatomy Revisited

John D. McKenzie, Bruce L. Dean, and Richard A. Flom

**Summary:** We report a case of a carotid-cavernous fistula through a persistent trigeminal artery with endovascular treatment, and discuss the Saltzman classification of persistent trigeminal artery anatomy and its importance in treatment of this lesion.

**Index terms:** Arteries, trigeminal; Fistula, carotid-cavernous; Interventional neuroradiology

Carotid-cavernous fistulas are abnormal communications between the carotid artery and the cavernous sinus. They have been classified depending on their pathogenesis or on the arterial origin (1, 2). We present a case of a traumatic carotid-cavernous fistula originating through a persistent trigeminal artery. We review the Saltzman classification scheme and its pertinent functional implications regarding endovascular therapy.

## Case Report

A 36-year-old man presented with proptosis and chemosis of the left eye, a left sixth cranial nerve palsy, and an audible bruit 6 months after a motor vehicle accident. Angiography was requested and performed using cut-film and digital subtraction techniques. The diagnostic angiogram demonstrated a fistula between a persistent trigeminal artery off the left internal carotid artery and the cavernous sinus (Fig 1A). This was confirmed with the vertebral artery injection and concomitant left common carotid artery compression.

The exact location of the fistula was determined by superselective arteriography through a Tracker-18 catheter (Target Therapeutics, Fremont, Calif). A 1505M detachable silicone balloon was mounted on a steamed and reshaped Hieshema taper select delivery system (ITC, South San Francisco, Calif) and placed into the venous chamber of the fistula (Fig 1B). Under fluoroscopic control, the balloon was inflated and detached at this position (Fig 1C). Postembolization angiography demonstrated nonfilling of the arteriovenous fistula and preservation of

the internal carotid artery and persistent trigeminal artery (Fig 1D). At 6-month follow-up, the bruit was absent, proptosis and chemosis had resolved, and the left sixth cranial nerve palsy improved.

## Discussion

The persistence into adulthood of the presegmental dorsal artery that accompanies the first division of the trigeminal nerve was described by Quain in 1844. The angiographic anatomy and classification were described by Saltzman in 1959 (3) and Wollschlaeger in 1964 (4). The fetal anatomy was reported by Khodadad in 1976 (5). Aneurysms may form at the origin of the primitive trigeminal artery (6, 7). These patients also may have other associated vascular anomalies (8). Rupture of persistent trigeminal artery aneurysms can result in subarachnoid hemorrhage or carotid-cavernous fistulas (9, 10). Treatment of these arterial fistulas has evolved from internal carotid artery ligation to endovascular occlusion with a detachable balloon (11–13).

The trigeminal artery is the most frequent persisting carotid-basilar anastomosis and is seen in 0.3% of angiograms (6, 8, 14). We present the preferred therapy of a trigeminal artery–cavernous fistula with detachable silicone balloon occlusion. Emphasis is placed on an understanding of the Saltzman anatomy and its two predominant variants.

In Saltzman type 1 anatomy, the basilar artery proximal to the insertion of the persistent trigeminal artery may be hypoplastic, and the posterior communicating artery may be absent (Fig 2A). Thus, the persistent trigeminal artery is the main supply to the distal basilar artery, posterior cerebral artery, and superior cerebellar artery territories. The posterior communicat-

---

Received November 18, 1994; accepted after revision May 12, 1995.

From the Department of Neuroradiology, Barrow Neurological Institute, Phoenix, Ariz.

Address reprint requests to Bruce L. Dean, MD, Barrow Neurological Institute, 350 W Thomas Rd, Phoenix, AZ 85013.

AJNR 17:280–282, Feb 1996 0195-6108/96/1702-0280 © American Society of Neuroradiology

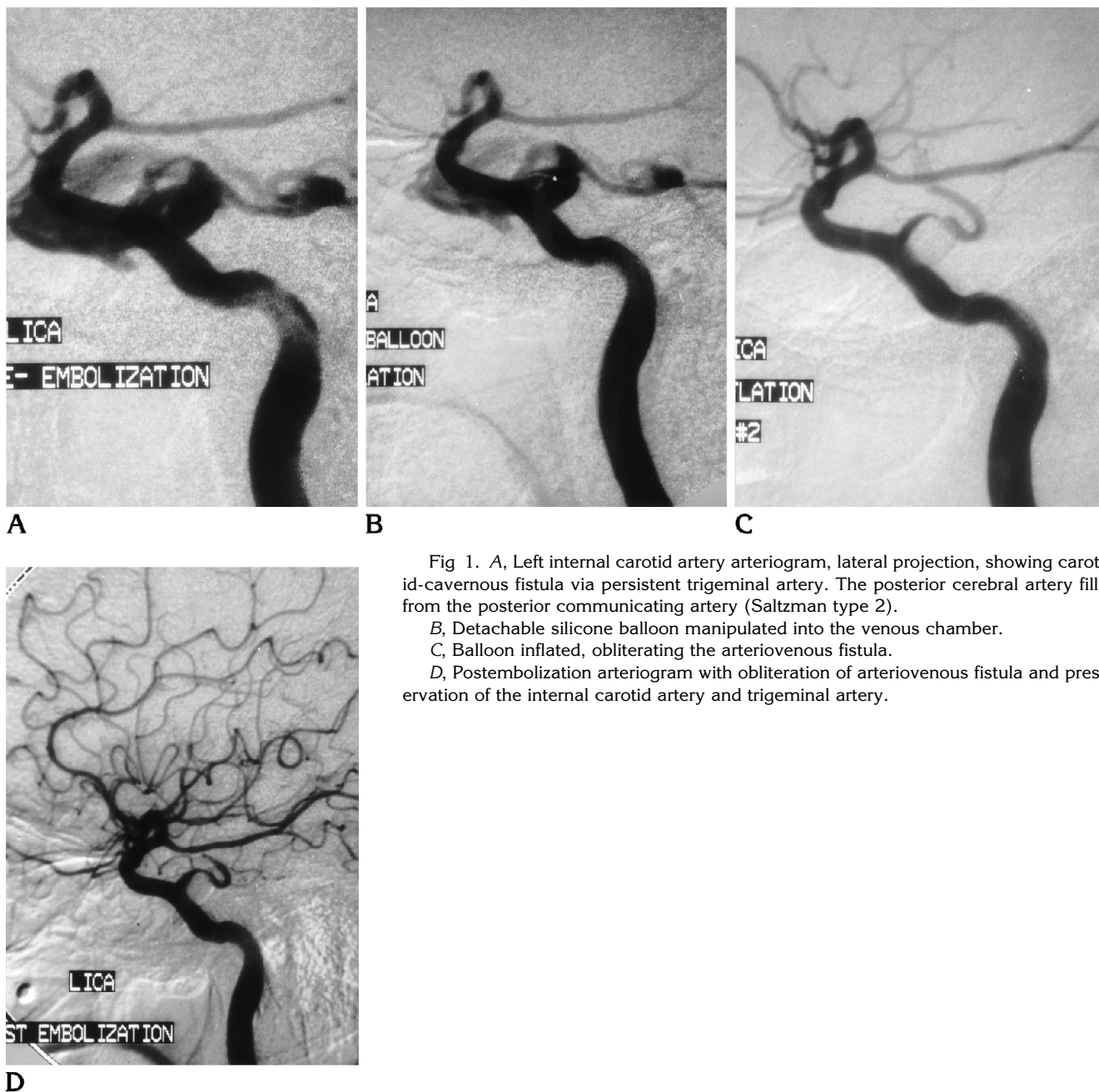


Fig 1. A, Left internal carotid artery arteriogram, lateral projection, showing carotid-cavernous fistula via persistent trigeminal artery. The posterior cerebral artery fills from the posterior communicating artery (Saltzman type 2).  
 B, Detachable silicone balloon manipulated into the venous chamber.  
 C, Balloon inflated, obliterating the arteriovenous fistula.  
 D, Postembolization arteriogram with obliteration of arteriovenous fistula and preservation of the internal carotid artery and trigeminal artery.

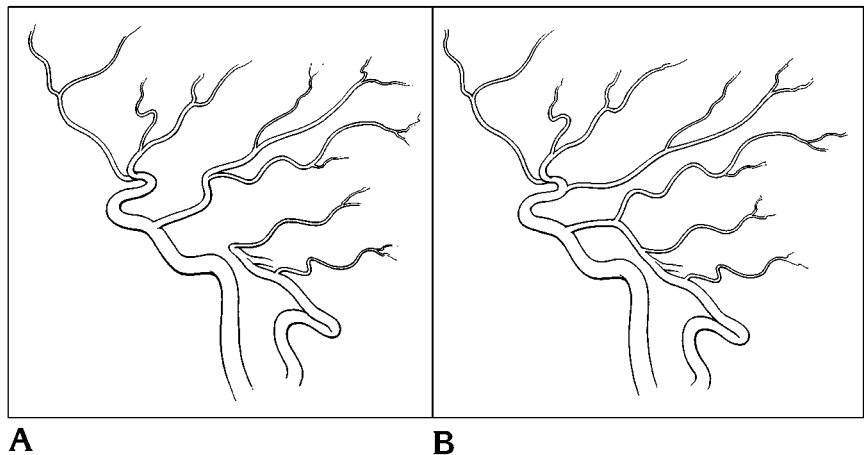
ing artery may be hypoplastic or aplastic. This patient exhibits an example of Saltzman type 2 anatomy in which the persistent trigeminal artery joins the basilar artery below the origin of the superior cerebellar arteries, and the posterior cerebral arteries receive their blood supply predominantly through patent posterior communicating arteries (3) (Fig 2B). The relative incidence of these two main types is equal. Numerous Saltzman variants, sometimes called Saltzman type 3, have been described (15-17).

An understanding of this arterial anatomy is important, especially when the parent artery (the persistent trigeminal artery) is sacrificed during treatment (14).

Traumatic carotid-cavernous fistula occurs in the cavernous portion of the internal carotid artery as a result of an arterial tear. The persistent trigeminal artery, not an uncommon incidental finding, may be the site of fistulization as in this case. As with the classic form of an arteriocavernous fistula, a trigeminal-cavernous

Fig 2. A, Saltzman type 1. The persistent trigeminal artery supplies the posterior cerebral and superior cerebellar territories. Midbasilar and posterior communicating arteries are hypoplastic.

B, Saltzman type 2. The patent posterior communicating artery supplies posterior cerebral artery territory, and the persistent trigeminal artery joins the basilar artery at the level of the superior cerebellar artery.



fistula may be treated successfully through an endovascular approach with minimal morbidity.

## References

1. Debrun G, Lacour P, Vinuela F. Treatment of 54 traumatic carotid-cavernous fistulas. *JNS* 1981;55:678-692
2. Francis PM, Flom RA, Zabramski JM, Spetzler RF. Treatment of carotid-cavernous fistulas, I: interventional neuroradiology. *Barrow Neurol Inst* 1991;7(3):2-8
3. Saltzman GF. Patent primitive trigeminal arteries studied by cerebral angiography. *Acta Radiol* 1959;51:329-336
4. Wollschlaeger G, Wollschlaeger PB. The primitive trigeminal artery as seen angiographically and at post mortem examination. *Am J Roentgenol Radium Ther Nucl Med* 1964;92(4):761-768
5. Khodadad G. Persistent trigeminal artery in the fetus. *Radiology* 1976;121:653-656
6. Freitas PE, Aquini MG, Chemaile I. Persistent primitive trigeminal artery aneurysm. *J Surg Neurol* 1986;26:373-374
7. Naruse S, Odake G. Persistent trigeminal artery associated with an ipsilateral intracavernous giant aneurysm: a case report. *JNR* 1979;17:259-264
8. Tomsick TA, Lukin RR, Chambers AA. Persistent trigeminal artery: unusual associated anomalies. *Neuroradiology* 1979;17:253-257
9. Morrison G, Hegarty WM, Brausch CC, Castele TJ, White RJ. Direct surgical obliteration of a persistent trigeminal artery aneurysm: case report. *JNS* 1974;39:249-251
10. Enomoto T, Sato A, Maki Y. Carotid cavernous sinus fistula caused by rupture of a primitive trigeminal artery aneurysm: case report. *JNS* 1977;46:373-376
11. Flandroy P, Lacour P, Marsault C, Stevenaert A, Collignon J. The intravascular treatment of a cavernous fistula caused by rupture of a traumatic carotid trigeminal aneurysm. *JNR* 1987;29:308-311
12. Kerber CW, Manke W. Trigeminal artery to cavernous sinus fistula treated by balloon occlusion: case report. *JNS* 1983;58:611-613
13. George AE, Lin JP, Morantz RA. Intracranial aneurysm on a persistent primitive trigeminal artery: case report. *JNS* 1971;35:601-604
14. Debrun GM, Davis KR, Nanta JH, Heros RE, Ahn HS. Treatment of carotid cavernous fistulae or cavernous aneurysms associated with a persistent trigeminal artery: report of three cases. *AJNR Am J Neuroradiol* 1988;9:749-755
15. Lie TA. Variations in cerebrovascular anatomy. In: Fox JL, ed. *Intracranial Aneurysms*. New York, NY: Springer-Verlag;1983(1):432-489
16. Teal JS, Rumbaugh CL, Bergeron RT, Scanlan RL, Segall HD. Persistent carotid-superior cerebellar artery anastomosis: a variant of persistent trigeminal artery. *Radiology* 1972;103(2):335-341
17. Cobb SR, Hieshima GB, Mehrhger CM, Grinnell VS, Pribram HW. Persistent trigeminal artery variant: carotid-anterior inferior cerebellar artery anastomosis. *Surg Neurol* 1983;19:263-266