

Are your **MRI contrast agents** cost-effective?

Learn more about generic **Gadolinium-Based Contrast Agents**.



FRESENIUS
KABI

caring for life

AJNR

Ipsilateral hemisphere activation during motor and sensory tasks.

A Li, F Z Yetkin, R Cox and V M Haughton

AJNR Am J Neuroradiol 1996, 17 (4) 651-655

<http://www.ajnr.org/content/17/4/651>

This information is current as
of April 16, 2024.

Ipsilateral Hemisphere Activation during Motor and Sensory Tasks

Andrew Li, F. Zerrin Yetkin, Robert Cox, and Victor M. Haughton

PURPOSE: To compare activation of the ipsilateral cerebral hemisphere during tactile sensory and motor tasks involving the right and left hands. **METHODS:** Eight volunteers had functional MR imaging to measure the extent of cerebral hemisphere activation during a motor task and a sensory task involving each hand. Hemispheric indexes (left hemisphere activation minus right hemisphere activation)/(left hemisphere activation plus right hemisphere activation) were computed for each hand and each task. The indexes for the two tasks and the two hands were compared. **RESULTS:** The left-hand motor tasks activated the ipsilateral hemisphere in right handers significantly more than did the right-hand tasks. Motor tasks produced a greater activation of the ipsilateral hemisphere than did the sensory tasks. No significant differences were found between the hemispheric indexes for the right-hand and left-hand sensory tasks. **CONCLUSION:** This study confirms findings of a previous study, showing that the left hemisphere is active in left-hand motor tasks. Activation of the ipsilateral hemisphere is significantly less pronounced during sensory tasks than during motor tasks.

Index terms: Brain, magnetic resonance; Magnetic resonance, functional; Movement

AJNR Am J Neuroradiol 17:651-655, April 1996

A functional magnetic resonance (MR) imaging study showed that left-hand finger movement activates the ipsilateral hemisphere substantially, whereas right-hand finger movement activates the ipsilateral hemisphere minimally (1). In right handers, the left hemisphere is activated nearly as much by left-hand finger movement as by right-hand finger movement. The symmetry or asymmetry of cerebral control of motor activity has been the subject of many studies (1-5). A recently reported functional MR imaging study showed that a tactile sensory task involving the hand produces activation in the contralateral rolandic cortex (6). Therefore, we tested the hypothesis that the ipsilateral cerebral hemisphere is activated to the same degree during both motor and sensory tasks.

Materials and Methods

Four right-handed subjects (one woman and three men) and four left-handed subjects (three women and one man) volunteered to participate in this study. All subjects completed the Edinburgh inventory (7) to confirm their handedness. The subjects, who ranged from 17 to 54 years old, claimed to be in good health, provided informed consent, and used ear plugs during the scanning procedure.

Images were acquired on a 1.5-T scanner equipped with an experimental three-axis local gradient coil and end-capped bird cage radio frequency transmit-receive coil (8). After localizer images were obtained, 12 to 14 (depending on the width of the subject's brain) contiguous 10-mm-thick sagittal images (600/20/1 [repetition time/echo time/excitations]) were prescribed to image the whole brain. A series of 70 images was acquired simultaneously at each section location at 2-second intervals during alternating 20-second periods of rest and task performance. A blipped gradient-echo echo-planar pulse sequence (2000/40, 24-cm field of view, 64 × 64 matrix) was used to acquire each image.

During the rest periods, the subject performed no voluntary motor activity. During the task periods, for the study of motor function, the subject tapped each finger to the thumb successively and repetitively for 20 seconds; for the study of sensory function, the investigator scratched the subject's palm from the finger tips to the wrist during the task period. The motor task and then the sensory task

Received June 15, 1995; accepted after revision October 31.

From the Department of Radiology (A.L., F.Z.Y., V.M.H.) and the Biophysics Research Institute (R.C.), The Medical College of Wisconsin, Milwaukee.

Address reprint requests to Victor M. Haughton, MD, Department of Radiology, Medical College of Wisconsin, Froedtert Hospital, 9200 W Wisconsin Ave, Milwaukee, WI 53226.

AJNR 17:651-655, Apr 1996 0195-6108/96/1704-0651

© American Society of Neuroradiology

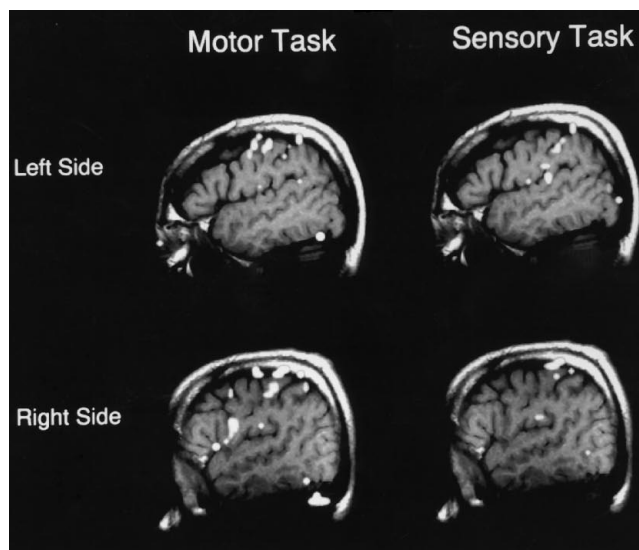
were performed first with the left hand and then with the right.

To identify pixels with significant activation, signal intensity versus time was plotted for each pixel in the matrix, and a correlation coefficient was calculated between the time course plot and a reference square-wave function (9). Pixels with a correlation coefficient of .6 or greater (activated pixels) were superimposed on the corresponding anatomic images for localization. For each task, the number of activated pixels in the posterior frontal and anterior parietal lobes was counted. Only the four most lateral sections in each hemisphere, in which most of the hand sensorimotor cortex is located, were included in the pixel tabulation. Pixels activated in each hemisphere by each task were used to calculate the hemispheric index by the formula (left hemisphere activation minus right hemisphere activation)/(left hemisphere activation plus right hemisphere activation). The indexes were calculated for motor and sensory tasks and for right-handed and left-handed subjects. Correlation coefficients and *t* values were calculated from a spreadsheet.

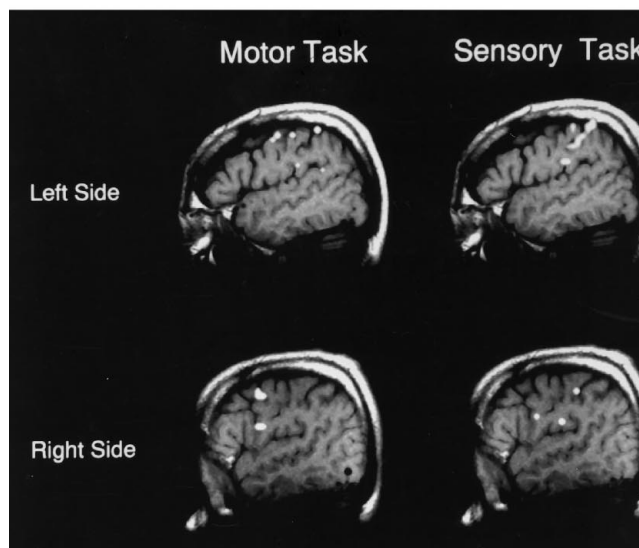
Results

Satisfactory functional MR images (fMRI) of activation for right-hand and left-hand motor and sensory tasks were obtained for each volunteer (Fig 1). Activation was identified near the central sulcus for both motor and sensory tasks. The number of activated pixels generated during each task is shown in Table 1.

The hemispheric indexes for right-hand and left-hand motor and sensory tasks varied from completely unilateral (index of 1.00) to nearly equally distributed between hemispheres (index of 0.02). The indexes (in absolute values) of each task in each of the eight volunteers are shown in Table 2. The average index for the left-hand motor task in right handers was 0.34. The average for the right-hand motor task in this group was higher (0.68), indicating less activation in the ipsilateral hemisphere for the right-hand motor task than for the left-hand motor task. The difference is significant ($P < .01$). The average index for left-hand tactile stimulation for the four right handers was 0.71, indicating less activation in the ipsilateral hemisphere for this task than for either motor task. For the right-hand tactile sensory task for right handers, the index was higher (0.82) but was not significantly different from indexes of the left-hand sensory task. Indexes for the sensory task were significantly higher than indexes for the motor tasks in right-handed subjects ($P < .04$).



A



B

Fig 1. A selected section from each hemisphere from functional MR images acquired during the motor and sensory tasks performed by the left hand (A) and the right hand (B) in a right-handed subject. Images show bilateral activation in the sensorimotor cortex for both sensory and motor tasks.

In left handers, the indexes for the left-hand motor task did not differ significantly from the right-hand task (average indexes of 0.28 and 0.20, respectively). For the sensory task in the left handers, the index was similar for left (0.62) and right (0.58) hands. In left handers, indexes for sensory tasks were significantly higher than indexes for motor tasks ($P < .004$).

TABLE 1: Number of activated pixels generated during motor and sensory tasks

Subject	Handedness	Tasks	L Hemisphere	R Hemisphere
A.A.	L	Motor L	12	29
		Motor R	30	26
		Sensory L	6	14
		Sensory R	14	6
A.B.	L	Motor L	18	42
		Motor R	53	34
		Sensory L	5	18
		Sensory R	4	1
E.R.	L	Motor L	25	34
		Motor R	1	1
		Sensory L	3	6
		Sensory R	18	0
M.S.	L	Motor L	34	49
		Motor R	28	28
		Sensory L	1	33
		Sensory R	38	14
V.H.	R	Motor L	19	23
		Motor R	14	5
		Sensory L	11	12
		Sensory R	27	5
A.L.	R	Motor L	15	17
		Motor R	28	9
		Sensory L	2	17
		Sensory R	12	3
D.R.	R	Motor L	13	27
		Motor R	15	2
		Sensory L	0	24
		Sensory R	25	0
K.S.	R	Motor L	0	10
		Motor R	2	0
		Sensory L	0	7
		Sensory R	18	0

Subjects with greater indexes for the motor tasks tended to have greater indexes for the sensory tasks. The correlation between motor and sensory indexes was significant (Fig 2; $r = .88, P < .01$).

Discussion

This study was designed to compare activation of the ipsilateral cerebral hemisphere during tactile sensory and motor tasks involving the right and left hands. An equal number of left handers and right handers was included because of the known differences in the organization of motor functions in left handers (1). Our study revealed that the degree of ipsilateral hemisphere activation was greater during the performance of left-hand tasks than during right-hand tasks. This difference was greater for right handers than for left handers. Our results

are in agreement with those of Kim et al (1) and Kawashima et al (4). Kim et al's study showed substantial left hemisphere activation during left-hand finger movements but minimal right hemisphere activation during right-hand finger movements in right handers and to a lesser extent in left handers (1). The method of identifying activated pixels in our study differed from that in Kim et al's study. Kawashima et al's study with positron emission tomography found a significant increase in ipsilateral cerebral blood flow during left-hand movement but not right-hand movement in right handers (4). The degree of ipsilateral activation may be related to the proportion of fibers in the lateral cortical spinal tracts that cross. Normally, 10% to 15% of these fibers remain uncrossed (10). The bilaterality of activation may explain ipsilateral and contralateral impairment in patients with unilateral hemispheric lesions (11-13).

Our results show ipsilateral activation in association with sensory tasks, but to a lesser degree than occurs with motor tasks. The ipsilateral sensory activation may be relevant to the clinical observation that ipsilateral sensory deficit has been found in association with unilateral cerebral lesions (14-16). The hypothesis that the ipsilateral hemisphere is activated to the same degree during both motor and sensory tasks was rejected. With a larger series of subjects, the difference between right-hand and left-hand sensory tasks in right handers might reach significance. However, the ipsilateral activation was significantly greater for the motor tasks than for the sensory tasks.

The two tasks used in the study most likely do not activate exclusively sensory or motor neu-

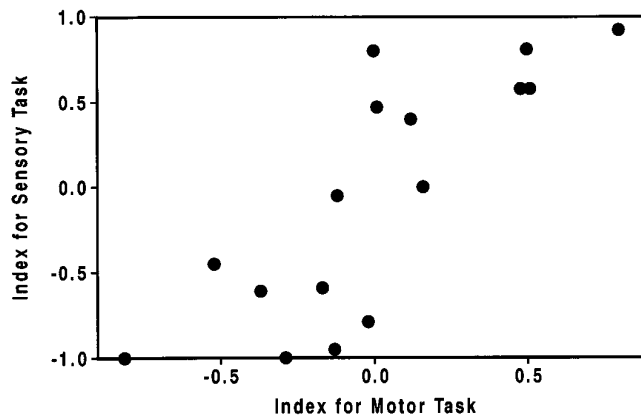


Fig 2. Distribution of activation during motor and sensory tasks. The hemispheric sensory indexes are plotted against the motor indexes for all subjects.

TABLE 2: Hemispheric indexes for right-hand and left-hand motor and sensory tasks in right and left handers

	R Handers				L Handers			
	L Task		R Task		L Task		R Task	
	Motor	Sensory	Motor	Sensory	Motor	Sensory	Motor	Sensory
	0.12	0.04	0.47	0.69	0.41	0.40	0.07	0.40
	0.06	0.79	0.49	0.60	0.40	0.60	0.20	0.40
	0.35	1.00	0.76	1.00	0.13	1.00	0.50	0.50
	0.82	1.00	1.00	1.00	0.18	0.46	0.02	1.00
Average	0.34	0.71	0.68	0.82	0.28	0.62	0.20	0.58

rons. The activation from the sensory and motor tasks overlapped in this study, as it did in previous studies (18, 19). Performance of the motor task produces some sensory input. Possibly, the sensory task produces some unconscious, imperceptible muscle changes in the hand. The significant correlation found in this study between motor and sensory indexes may be due to the fact that both tasks have motor or sensory activation.

These data must be interpreted conservatively, because functional MR imaging techniques are evolving. The indexes were calculated on the basis of activation that occurred in the sensorimotor and adjacent cortices. Midline sections that contain activation in the supplementary cortex during a motor, but not usually during a sensory, task were excluded from the tabulation. We did not attempt to distinguish the premotor cortex from the sensorimotor cortices in the pixel tabulation, although for the motor task we used, activation in the premotor cortex most likely is minimal (17). We did not control the frequency or intensity of the tasks, but variation in the stimulus would most likely produce a random, not a systematic effect. When we tabulated the indexes on the basis of pixel counts for all sections, similar statistically significant correlations resulted. We did not attempt to distinguish between precentral and postcentral gyral activation, because previous studies have shown that motor tasks and sensory tasks produce activation in both the postcentral and precentral gyri (18). Artifacts were not distinguished from true activation, but the images and the location of activation in most cases suggest that artifacts were not numerous. The threshold chosen, which maximizes the number of true positives and minimizes vari-

ance (19), may not have identified all pixels with activation.

This study suggests that motor and sensory tasks involving the right and left hands produce different degrees of activation in the ipsilateral hemisphere. The results of this study are useful in the assessment of degree of motor and sensory deficits in patients with cerebral hemispheric lesions.

References

1. Kim S-G, Alshe J, Hendrich K, et al. Functional magnetic resonance imaging of motor cortex: hemispheric asymmetry and handedness. *Science* 1993;261:615-617
2. Haaland KY, Cleeland CS, Carr D. Motor performance after unilateral hemisphere damage in patients with tumor. *Arch Neurol* 1977;34:556-559
3. Haaland KY, Harrington DL. Hemispheric control of the initial and corrective components of aiming movements. *Neuropsychologia* 1989;27:961-969
4. Kawashima R, Yamada K, Kinomura S, et al. Regional cerebral blood flow changes of cortical motor areas and prefrontal areas in humans related to ipsilateral and contralateral hand movement. *Brain Res* 1993;623:33-40
5. Colebatch JG, Gadevia SC. The distribution of motor weakness in upper motor neuron lesions affecting the arm. *Brain* 1989;112:749-763
6. Hammeke TA, Yetkin FZ, Mueller WM, et al. Functional magnetic resonance imaging of somatosensory stimulation. *Neurosurgery* 1994;35:677-681
7. Oldfield RC. The assessment and analysis of handedness: the Edinburgh inventory. *Neuropsychologia* 1971;9:97-113
8. Bandettini PA, Wong EC, Hinks RS, Tikofsky RS, Hyde JS. Time course EPI of human brain function during task activation. *Magn Reson Med* 1992;25:390-397
9. Bandettini PA, Jesmanowicz J, Wong EC, Hyde JS. Processing strategies for time-course data sets in functional MRI of the human brain. *Magn Reson Med* 1993;30:161-173
10. Nyberg-Hansen R, Rinvik E. Some comments on the pyramidal tract with special reference to its individual variations. *Acta Neurol Scand* 1963;39:1-30
11. Carmon A. Sequenced motor performance in patients with unilateral cerebral lesions. *Neuropsychologia* 1971;9:445-449

12. Haaland KY, Delaney HD. Motor deficits after left or right hemisphere damage due to stroke or tumor. *Neuropsychologia* 1981; 19:17-27
13. Jones RD, Donaldson LM, Parkin PJ. Impairment and recovery of ipsilateral sensory motor function following unilateral cerebral infarction. *Brain* 1989;112:113-132
14. Carmon A. Disturbances of tactile sensitivity in patients with unilateral cerebral lesions. *Cortex* 1971;7:83-97
15. Corkin S, Milner B, Taylor L. Bilateral sensory loss after unilateral cerebral lesion in man. *Trans Am Neurol Assoc* 1973;98:118-122
16. Semmes J, Weinstein S, Ghent L, Teuber H. *Somatosensory Changes after Penetrating Brain Wounds in Man*. Cambridge, Mass: Harvard University Press, 1960:15-28
17. Rao SM, Binder JR, Bandettini PA, et al. Functional magnetic resonance imaging of complex human movements. *Neurology* 1993;43:2311-2318
18. Yetkin FZ, Mueller WM, Hammeke TA, Morris GL III, Haughton VM. Functional magnetic resonance imaging mapping of the sensorimotor cortex with tactile stimulation. *Neurosurgery* 1995;36: 921-925
19. Yetkin FZ, McAuliffe TL, Cox R, Haughton VM. Test-retest precision of functional MR in sensory and motor task activation. *AJNR Am J Neuroradiol* 1996;17:95-98