

Are your **MRI contrast agents** cost-effective?

Learn more about generic **Gadolinium-Based Contrast Agents**.



FRESENIUS
KABI

caring for life

AJNR

Contrast-enhanced magnetization transfer saturation imaging improves MR detection of herpes simplex encephalitis.

J W Burke, V P Mathews, A D Elster, J L Ulmer, F M McLean and S B Davis

This information is current as of May 14, 2024.

AJNR Am J Neuroradiol 1996, 17 (4) 773-776
<http://www.ajnr.org/content/17/4/773>

Contrast-Enhanced Magnetization Transfer Saturation Imaging Improves MR Detection of Herpes Simplex Encephalitis

Jerry W. Burke, Vincent P. Mathews, Allen D. Elster, John L. Ulmer, Frederick M. McLean, and Steven B. Davis

Summary: Cranial MR imaging was performed in three patients in whom herpes simplex encephalitis was subsequently proved. In all cases, the postcontrast T1-weighted MR images obtained with magnetization transfer saturation showed greater central nervous system involvement than was apparent on the conventional MR images. Specifically, the postcontrast magnetization transfer images were superior at delineating generalized meningeal enhancement as well as focal areas of brain involvement not seen on noncontrast T2-weighted images or conventional postcontrast T1-weighted images.

Index terms: Encephalitis; Herpes simplex; Magnetic resonance, magnetization transfer

Recently, magnetization transfer saturation techniques have been used to show areas of contrast enhancement in a variety of central nervous system lesions not apparent on conventional magnetic resonance (MR) images (1–3). Magnetization transfer pulses suppress the signal from tissues rich in macromolecules, such as normal brain tissue, by 20% to 40% (4). Suppression of background brain tissue by magnetization transfer saturation intensifies the degree of differential signal intensity observed from nonsuppressed contrast-containing structures relative to nonenhancing adjacent tissue. We performed contrast-enhanced MR imaging with magnetization transfer saturation in patients with herpes simplex virus (HSV) encephalitis to determine if this imaging technique improved detection of abnormalities of the central nervous system that accompany this disease.

Case Reports

Case 1

A 9-month-old girl was admitted to the hospital after 8 days of fever, vomiting, and progressive lethargy. Physical

examination revealed a lethargic, moderately dehydrated infant with a mildly bulging anterior fontanel and temperature of 40°C. While in the emergency department, a generalized tonicoclonic seizure was observed. T2-weighted MR images showed abnormal hyperintense signal in the right occipital and posterior temporal lobes (Fig 1A and B). Focal petechial cortical hemorrhages were also present (not shown). Mild diffuse enhancement in the region was apparent on the routine postcontrast images (Fig 1C). Postcontrast images with magnetization transfer (Fig 1D) revealed significantly larger areas of enhancement and showed the temporal lobe involvement more clearly, allowing a more confident imaging diagnosis of HSV encephalitis. HSV-1 was cultured from the cerebrospinal fluid.

Case 2

A 3-month-old girl with a 2-day history of fever was brought to the emergency department because of focal left-sided seizure activity. Her physical and neurologic examinations were otherwise unremarkable. The EEG showed nonspecific changes. Cerebrospinal fluid cytology revealed 55 500 leukocytes per microliter, of which 90% were monocytes. The patient was taken directly to the MR imaging suite, where T2-weighted images revealed subtle signal alteration involving the cortical tissues of the right temporoparietal region (Fig 2A and B). Conventional postcontrast images showed mild enhancement predominantly on the right (Fig 2C). Postcontrast T1-weighted images with magnetization transfer displayed extensive bilateral leptomeningeal and cortical involvement underestimated on images obtained by conventional techniques (Fig 2D). Brain biopsy was declined. A presumptive diagnosis of HSV encephalitis was made on the basis of the clinical, laboratory, and imaging findings. The patient was placed on acyclovir therapy, and had a rapid, favorable response.

Received May 15, 1995; accepted after revision August 23.

From the Department of Radiology, Bowman Gray School of Medicine, Wake Forest University, Winston-Salem, NC.

Address reprint requests to J. W. Burke, MD, Department of Radiology, Bowman Gray School of Medicine, Wake Forest University, Medical Center Blvd, Winston-Salem, NC 27157.

AJNR 17:773–776, Apr 1996 0195-6108/96/1704–0773 © American Society of Neuroradiology

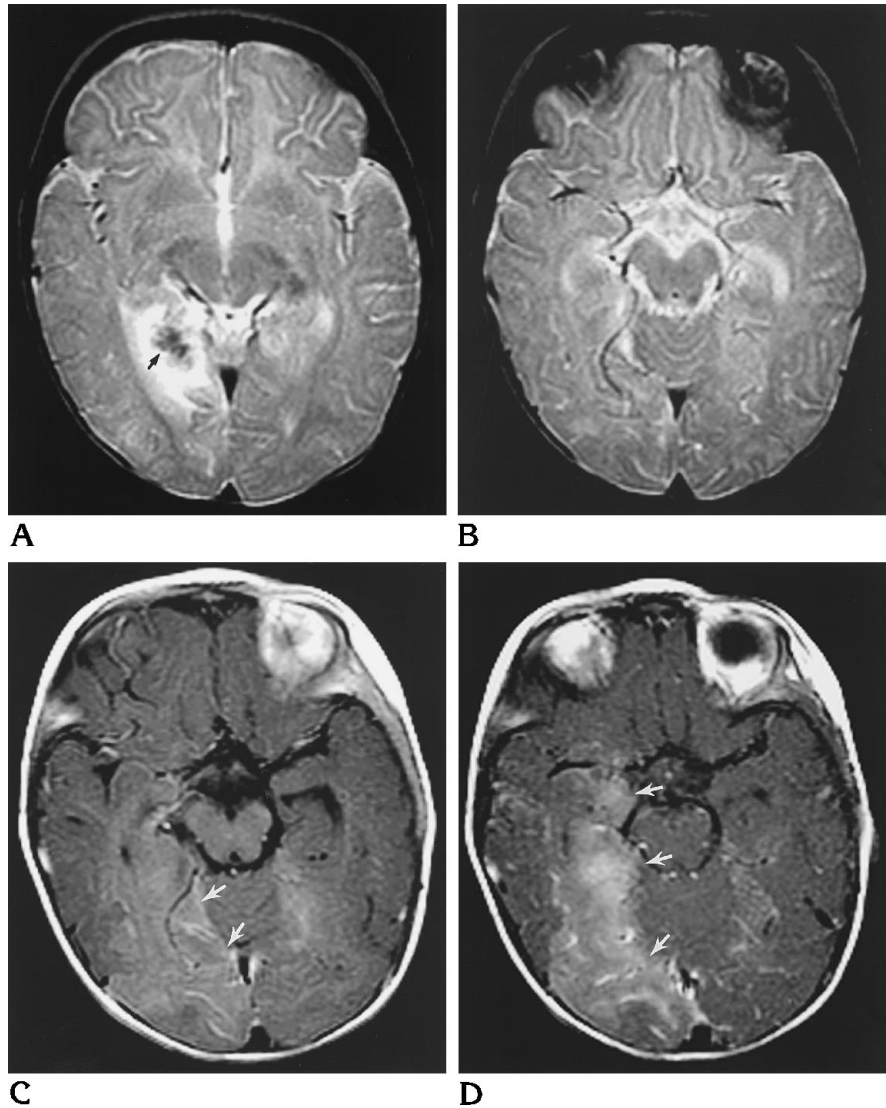
Fig 1. Case 1: 9-month-old girl with an 8-day history of fever, vomiting, and progressive lethargy.

A, T2-weighted MR image at level of maximum abnormality shows right-sided temporoparietal abnormality. High-signal edema surrounds the central hemorrhagic focus (arrow).

B, T2-weighted MR image at same level as C and D shows minimally increased signal in the right occipital and posterior temporal lobes.

C, Routine postcontrast MR image shows mild diffuse enhancement in the same region (arrows).

D, Postcontrast MR image with magnetization transfer reveals bilateral leptomeningeal enhancement and more extensive involvement of the right temporal lobe (arrows).



Case 3

A 4-year-old girl with mild cerebral palsy was admitted to the hospital with a 36-hour history of new tonicoclonic seizures and temperature of 40.3°C. Other than intermittent tonicoclonic seizure activity, the EEG was normal and no focal neurologic defects were identified. Laboratory examination showed a leukocytosis with a predominance of neutrophils. The initial cranial computed tomographic (CT) scan was equivocal for a slightly decreased attenuation in the right temporal lobe. Noncontrast MR imaging confirmed this finding, showing abnormal hyperintense signal intensity predominantly involving the cortex of the right temporal lobe and insula on the T2-weighted images. Subtle signal alterations were suggested in the left insular cortex. Routine images obtained after administration of contrast material showed little enhancement. However, postcontrast images obtained with magnetization transfer revealed diffuse leptomeningeal and possibly cortical enhancement. Brain biopsy confirmed HSV-1 encephalitis.

Discussion

HSV is the most common cause of acute sporadic viral encephalitis in temperate climates. Serologic subgroups have been identified that can be distinguished by their distinct clinical features and patterns of brain involvement (5). HSV-1 is responsible for over 95% of all cases of herpetic encephalitis. The characteristic distribution of HSV-1 encephalitis usually results from retrograde axoplasmic transport along the nerves innervating the middle cranial fossa following reactivation of latent trigeminal infection (6).

HSV encephalitis should be considered as a diagnostic possibility any time a febrile patient exhibits acute neurologic signs and symptoms. Early diagnosis is important, since mortality re-

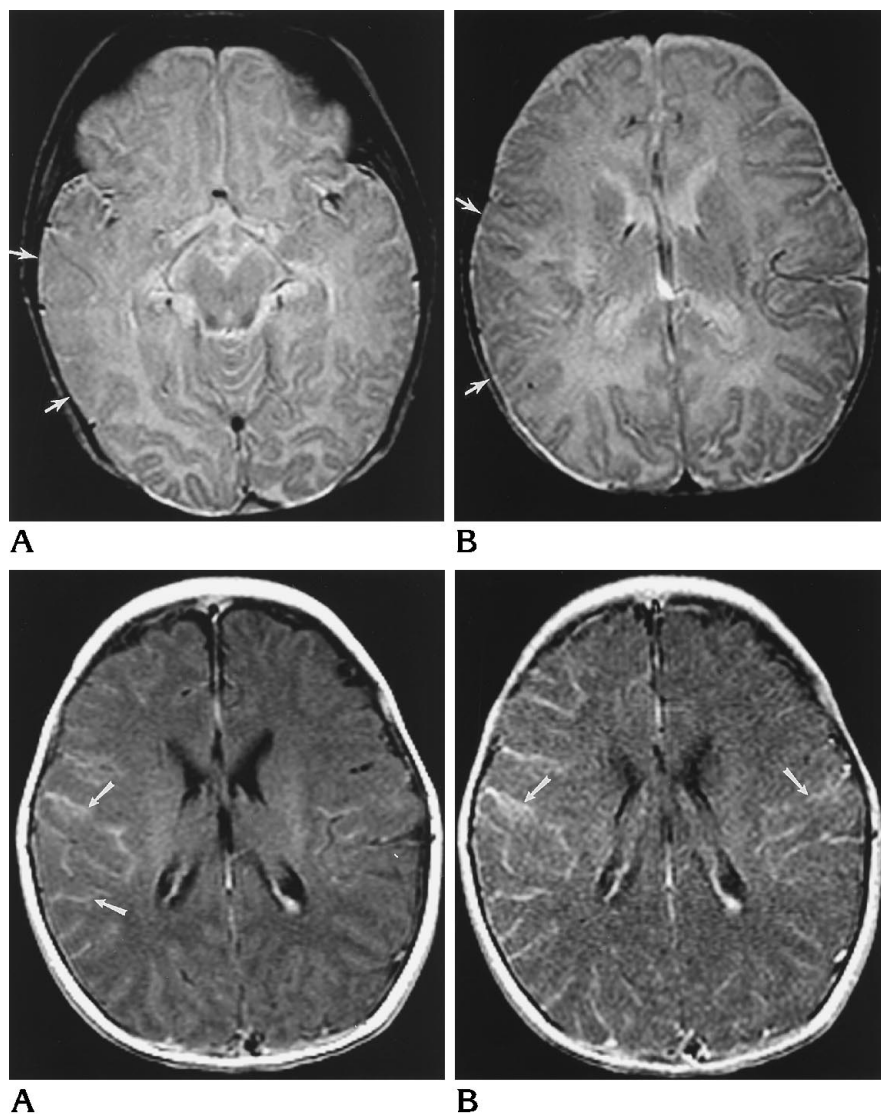


Fig 2. Case 2: 3-month-old girl with a 2-day history of fever and focal left-sided seizure activity.

A, T2-weighted MR image at level of maximum abnormality reveals loss of the cortical gray-white border and cortical signal in right temporal lobe (*arrows*).

B, T2-weighted MR image at same level as C and D shows subtle signal alteration involving the cortical tissues in the right temporoparietal region (*arrows*).

C, Conventional postcontrast image shows mild enhancement, predominantly on the right (*arrows*).

D, Postcontrast image obtained with magnetization transfer technique more clearly identifies the bilateral extent of the leptomeningeal and cortical involvement (*arrows*).

sulting from HSV encephalitis exceeds 70% without appropriate therapy, and surviving patients often have serious neurologic sequelae, including functional deficits and seizures. The importance of establishing a prompt diagnosis is accentuated by the remarkable improvement resulting from the early institution of acyclovir therapy, with prompt treatment significantly reducing patient morbidity and mortality (7).

HSV-1 encephalitis initially involves the cerebral cortex, causing neuronal destruction and cytotoxic edema. A characteristic pattern of distribution is exhibited by the pathogen, with the anterior and medial aspects of the temporal lobes and the inferior portion of the frontal lobes initially infected. When the process extends to include the insular cortex, the lentiform nucleus is typically spared (8). Loss of the gray matter-

white matter interface in the affected regions is demonstrated on imaging studies and may be confused with cerebral infarction when the pattern of involvement is unilateral. Bilateral involvement is almost pathognomonic for HSV encephalitis, particularly when asymmetric. Findings at CT are usually normal during the early stages of infection, and abnormal parenchymal or meningeal enhancement is rarely detected before the second week of clinical symptoms (9).

MR imaging has become important in the early examination of patients with HSV encephalitis, because it is more sensitive in identifying the manifestations of the disease. Prolongation of the T1 and T2 relaxation times in the areas of involvement results in decreased signal intensity on T1-weighted images and increased sig-

nal intensity on T2-weighted images. Focal areas of hemorrhage may be detected in areas of herpetic involvement by noncontrast MR imaging. The necrotizing meningoencephalitis produced by HSV infection damages the blood-brain barrier and can be detected as regions of contrast enhancement better by contrast-enhanced MR imaging than by contrast-enhanced CT. The leptomeningeal and gyral enhancement associated with HSV encephalitis typically occur along the temporal lobes, insular cortex, subfrontal area, and cingulate gyrus (10).

Recently, magnetization transfer suppression techniques and administration of contrast material have been shown to be synergistic in demonstrating enhancement of a variety of cerebral lesions by MR imaging (11–12). The magnetization transfer technique used in this study consisted of a single radio frequency pulse of 200 Hz bandwidth applied 1200 Hz downfield from the water resonance and has been described previously (4). Because contrast enhancement is caused by the direct interaction of ions of water and contrast material, and does not depend on macromolecular interactions, it is not appreciably suppressed by magnetization transfer pulses. Magnetization transfer pulses, therefore, preferentially suppress the signal from brain and render contrast-enhancing regions more conspicuous.

Although magnetization transfer suppresses the signal from all brain tissue, some structures are suppressed more than others. The cerebral white matter exhibits the greatest degree of signal suppression. Pathologic processes that preferentially affect the cerebral gray matter and cause disruption of the blood-brain barrier receive the greatest benefit from the application of magnetization transfer to postcontrast imaging with paramagnetic contrast agents, because the adjacent white matter is suppressed so well. This has already proved beneficial for the early detection and improved characterization of ischemic tissues (11) and should increase the sensitivity of postcontrast MR imaging in the detection of inflammatory involvement of the cerebral cortex.

Normal cortical vessels appear as more well-defined linear or tubular enhancing structures on postcontrast magnetization transfer images than on conventional postcontrast images (4). Familiarity with findings on images obtained with this technique will prevent misinterpretation of normal vascularity as abnormal diffuse

leptomeningeal enhancement. The inflammatory hyperemia associated with pathologic processes results in indistinct, asymmetric areas of leptomeningeal enhancement that can be readily identified by the concurrent use of magnetization transfer, thus allowing for improved detection of these processes.

Conclusion

In all three patients in this study, the postcontrast T1-weighted sequences with magnetization transfer revealed a greater degree of disease involvement than was apparent on the conventional T2-weighted or postcontrast T1-weighted images. This technique should be considered when it is desirable to maximize the available radiologic information for a patient with suspected HSV encephalitis who has been referred for MR imaging, particularly when the diagnosis is unclear from findings on noncontrast or conventional postcontrast images.

References

1. Tantt JI, Sepponen RE, Lipton MJ, Kuusela T. Synergistic enhancement of MRI with Gd-DTPA and magnetization transfer. *J Comput Assist Tomogr* 1992;16:19–24
2. Elster AD, Mathews VP, King JC, Hamilton CA. Improved detection of gadolinium enhancement using magnetization transfer imaging. *Neuroimaging Clin North Am* 1994;4:185–192
3. Mathews VP, Elster AD, King JC, Ulmer JL, Hamilton CA, Strottmann JM. Combined effects of magnetization transfer and gadolinium in cranial MR images and MR angiography. *AJR Am J Roentgenol* 1995;164:169–172
4. Elster AD, King JC, Mathews VP, Hamilton CA. Cranial tissues: appearance at gadolinium-enhanced and nonenhanced MR imaging with magnetization transfer contrast. *Radiology* 1994;190:541–546
5. Whiteley RJ. Viral encephalitis. *N Engl J Med* 1990;323:242–250
6. Damasio AR, Van Hoesen GW. The limbic system and the localization of herpes simplex encephalitis. *J Neurol Neurosurg Psychiatry* 1985;48:297–301
7. Gordon B, Selnes OA, Hart J, Hanley DF, Whitley RJ. Long-term cognitive sequelae of acyclovir-treated herpes simplex encephalitis. *Arch Neurol* 1990;47:646–647
8. Damaerel P, Wilms G, Robberecht W, et al. MRI of herpes simplex encephalitis. *Neuroradiology* 1992;34:490–493
9. Davis JM, Davis KR, Kleinman GM, Krichner HS, Taveras JM. Computed tomography of herpes simplex encephalitis with clinicopathological correlation. *Radiology* 1978;129:409–417
10. Tien RD, Felsberg GJ, Osumi AK. Herpesvirus infections of the CNS: MR findings. *AJR Am J Roentgenol* 1993;161:167–176
11. Mathews VP, King JC, Elster AD, Hamilton CA. Cerebral infarction: effect of dose and magnetization transfer saturation at gadolinium-enhanced MR imaging. *Radiology* 1994;190:547–552
12. Mehta RC, Pike GB, Haros SP, Enzmann DR. Central nervous system tumor, infection, and infarction: detection with gadolinium-enhanced magnetization transfer MR imaging. *Radiology* 1995;195:41–46