

Are your **MRI contrast agents** cost-effective?

Learn more about generic **Gadolinium-Based Contrast Agents**.



FRESENIUS
KABI

caring for life

AJNR

Preliminary report: changes in vital signs of term newborns during MR.

M K Philbin, K H Taber and L A Hayman

AJNR Am J Neuroradiol 1996, 17 (6) 1033-1036

<http://www.ajnr.org/content/17/6/1033>

This information is current as
of April 19, 2024.

Preliminary Report: Changes in Vital Signs of Term Newborns during MR

M. Kathleen Philbin, Katherine H. Taber, and L. Anne Hayman

PURPOSE: To investigate the effect of the MR environment on vital signs of term neonates. **METHODS:** We retrospectively analyzed physiological monitoring data obtained from seven term infants (20 to 22 days old) undergoing a clinically indicated MR examination. They were monitored for heart rate, blood pressure, and oxygen saturation while sedated and physically quiet. Six control infants were monitored while sedated and resting in the magnet. **RESULTS:** All of the test infants exhibited substantial changes in blood pressure, heart rate, and/or oxygen saturation during the MR examination. No such changes were observed in the control infants. **CONCLUSION:** These preliminary results suggest that undergoing an MR examination may alter the vital signs of term newborn infants.

Index terms: Infants, newborn; Magnetic resonance, in infants and children

AJNR Am J Neuroradiol 17:1033-1036, June 1996

Magnetic resonance (MR) imaging has shown great promise as an aid in the evaluation of neonatal brain damage (1-6). However, it is well established that both term and preterm newborns can exhibit autonomic instability in response to sensory stimulation (7-9) as mild as those encountered during an MR scan. This retrospective study is a preliminary evaluation of the effect of the MR environment on vital signs of term neonates.

Materials and Methods

The heart rate, noninvasive blood pressure, and oxygen saturation were monitored (Patient Monitoring System 3100, Invivo Research, Inc; Orlando, Fla) in seven term newborns undergoing MR examination. The infants were 2

to 22 days old at the time of the examination and were sedated with chloral hydrate (50 mg/kg). Standard clinical MR examinations of the brain, spine, or hip were done on a 1.5-T scanner. In addition, monitoring data were obtained in six control infants while they were sedated and resting in the magnet before undergoing MR imaging. All infants were swaddled and stabilized with foam padding around the head and ears. Ear plugs were not used. Details of the individual MR examinations are given in the Table. All procedures conformed to the Food and Drug Administration's guidelines relating to specific absorption rates. Continuous strips of monitoring tape (25 mm/s) were collected throughout the examination. Blood pressure and oxygen saturation rates were taken directly from the tape. The printed heart rate frequently did not reflect the variability observed in the analog recordings, probably as a result of the averaging algorithm used within the monitor. To obtain an accurate heart rate for each 1-minute interval, the individual R wave formations were counted for the first and fourth 10-second segments of each minute of tape. These heart rates were averaged to obtain a value for the entire minute. Some segments of data were lost when the roll of paper monitoring tape was exhausted and a new roll was installed. For comparison, all vital signs charted in the days preceding and following the MR examination were obtained to establish the normal range for each infant.

Results

All seven infants had alterations in one or more of their vital signs during the MR examination (Fig 1A and B). These changes, which

Received October 12, 1995; accepted after revision January 4, 1996.

Presented at the annual meeting of the American Society of Neuroradiology, Nashville, Tenn, May 1994.

From the Department of Target Populations, University of Texas-Houston School of Nursing (M.K.P.), and the Department of Radiology and the Herbert J. Frensky Center for Imaging Research, Baylor College of Medicine, Houston, Tex (K.H.T., L.A.H.). Work was performed in the Department of Otolaryngology Research Laboratory, University of Texas-Houston School of Medicine.

Address reprint requests to M. Kathleen Philbin, PhD, RN, University of Texas-Houston School of Nursing, 1100 Holcombe Blvd, Suite 5.500, Houston, TX 77030.

AJNR 17:1033-1036, Jun 1996 0195-6108/96/1706-1033

© American Society of Neuroradiology

Clinical and MR imaging acquisition parameters in seven term neonates

Infant	Age, d	Diagnosis	Type of Sedation	Contrast Material	Body Area Imaged	Coil	Pulse Sequences: Repetition Time/Echo Time	Field of View, cm	Section Thickness, mm
1	4	Normal brain	Chloral hydrate	None	Head	Adult head	T1:SE:500/11-20 SD:FSE:3500/18 T2:FSE:4000/85	20	3 4 5
2	2	Chiari anomaly	Chloral hydrate	None	Head	Adult head	T1:SE:500-600/12-19 SD:FSE:4500/18	18	4 5
3	5	Dandy-Walker variant	Chloral hydrate	None	Head	Adult head	T1:SE:500-700/11-19 SD:FSE:2300/18 T2:FSE:7000/90	20	4 4 4
4	4	Parenchymal hemorrhage	Natural sleep	Gadopentelate dimeglumine	Head	Adult head	T1:SE:500/11-19 SD:FSE:2300/14 T2:FSE:6300/84 T2:GE:650/14 (30° flip angle)	20	5 5 5
5	22	Osteomyelitis, femur	Chloral hydrate	None	Hips	Adult head	T1:SE:500/12-14 SD:none T2:FSE:2000-3000/96-98	18	3
6	4	Large thecal sac	Chloral hydrate	None	Lumbar spine	5-in surface coil	T1:SE:500-600/11-19 SD:none T2:FSE:4500/84	20	3 16
7	2	Normal spine	Chloral hydrate	None	Lumbar spine	5-in surface coil	T1:SE:500/11-1 SD:none T2:none	16 16 20	3 3 4

Note.—T1 indicates T1-weighted; SD, spin density; T2, T2-weighted; SE, spin echo; FSE, fast spin echo; and GE, gradient echo.

included episodes of abruptly elevated heart rate, long periods of low blood pressure, and episodes of bradycardia, occurred in term infants who had normal ($n = 3$) and abnormal ($n = 4$) brains. The changes cannot be attributed to motor activity or crying, since all the infants had MR images that were motion free. Fluctuations in vital signs during the days surrounding the MR examination were compared with those during the MR examination (Fig 1). It would be expected that the range from the chart data would be greater than that during MR examination, because the former values were obtained during a wide variety of behavioral states; however, considerably more variability was found during the MR examination, even though the infants were sedated and sleeping. Thus, as compared with either their own normal range or with the normal range reported in the literature (10-13), these infants exhibited unusually large fluctuations in their vital signs during the MR examination.

As a control, vital signs were monitored in six newborns (three with normal brains and three with abnormal brains) who were sedated and resting in the magnet before undergoing MR examination. The mean and range of values obtained were compared with the mean and

range of corresponding values obtained from the chart for the preceding days (minimum of 2 days) (Fig 1C). As we said, it would be expected that the mean and range of the chart data would be greater than those obtained during sedation in the MR scanner; and, indeed, in no infant in the control group did the mean or range of a vital sign recorded during resting in the magnet ever exceed that from the chart. In the majority of cases (4 of 6), the mean heart rate in the magnet (before MR examination) was 10 to 12 beats per minute lower (although still within the normal range), most probably as a result of sedation. Thus, exposure to transport, sedation, and static magnetic field were not sufficient to cause vital signs outside their own normal range in these infants.

Discussion

This retrospective study indicates that rapid changes in vital signs may occur during MR examination of newborns that cannot be attributed to transport, sedation, or exposure to the static magnetic field. While such changes are not likely to pose a danger to healthy term newborns, they might to the more fragile preterm infant. The current standard of care for preterm

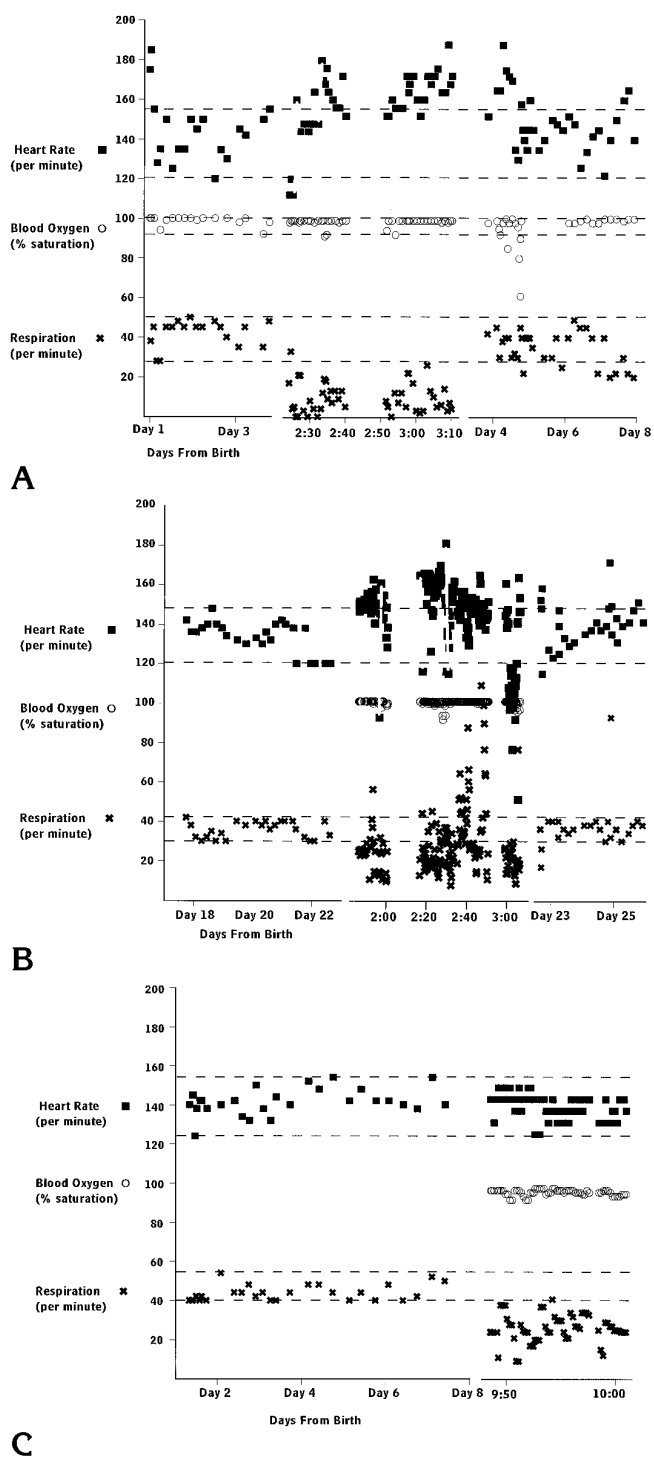


Fig 1. Vital signs obtained from chart records and monitoring strips for three representative infants are shown as a function of time from birth. The time scale during MR imaging is expanded relative to the days preceding and following the MR examination. The interval during which the patient was sedated and in the magnet is indicated by the shaded area on each graph. The range for vital signs obtained from the charted values is indicated by the solid horizontal lines. Two of the infants (A, infant 2 from the Table and B, infant 5 from the Table) underwent an MR examina-

tion. One infant (C) was exposed only to the stress of transport, sedation, and the static magnetic field. Although the infants shown in A and B were sedated and quiet while in the magnet, the majority of the time their heart rates were above the range recorded in the charts. Abrupt changes in heart rate were also seen (examples indicated by white lines). The three white lines in B draw attention to three such changes (155 to 91, 162 to 114, and 178 to 114 beats per minute, respectively). Similar changes are seen in A. The vital signs for the infant who was sedated and resting in the magnet (C) stayed within the range of normal established by the charted values, and abrupt changes were not seen.

infants requires minimization of sensory stimulation that could cause abrupt changes in vital signs (14–18). This standard is followed because the cardiovascular physiology of the preterm and full-term newborn is immature compared with that of older infants or adults. In the newborn, immature contractility of the myocardium limits the range of stroke volume of the ventricles (19, 20). As a consequence, heart rate exerts far more control over systemic blood flow/pressure in the neonate than does stroke volume (19, 20). In addition, immature autoregulation of the cerebral vasculature leaves the newborn brain subject to disruptions in perfusion (21). Lacking consistent regulation within the vessels, the cerebral blood pressure tends to be pressure-passive to the systemic blood pressure (15, 22, 23). As a consequence, heart rate is an important influence on cerebral blood flow/pressure in the neonate. Currently, the literature suggests that repeated, large fluctuations in cerebral blood pressure, along with periods of low blood flow and other conditions resulting in damage to the cerebral vasculature, can induce or worsen an intracranial hemorrhage (15, 16, 19, 22). If this is so, it would be difficult to document each of the particular events contributing to a hemorrhage, including changes in vital signs during MR imaging. Indeed, none of the infants in the present study is known to have suffered any deleterious effects from the examinations.

These findings also indicate that oxygen saturation may be a poor indicator of autonomic stability, since this measure remained stable in some of the infants when the heart rate (and, therefore, systemic blood flow/pressure) fluctuated dramatically. The most likely source of this insensitivity is the algorithm used in the monitoring equipment. It is designed to not register rapidly fluctuating extremes in heart rate, thus making it easier for the viewer to interpret the

tion. One infant (C) was exposed only to the stress of transport, sedation, and the static magnetic field. Although the infants shown in A and B were sedated and quiet while in the magnet, the majority of the time their heart rates were above the range recorded in the charts. Abrupt changes in heart rate were also seen (examples indicated by white lines). The three white lines in B draw attention to three such changes (155 to 91, 162 to 114, and 178 to 114 beats per minute, respectively). Similar changes are seen in A. The vital signs for the infant who was sedated and resting in the magnet (C) stayed within the range of normal established by the charted values, and abrupt changes were not seen.

data. The authors recommend that nursing personnel should monitor the heart rate directly from chest leads to ensure accurate measurements. Future prospective studies are planned to determine which, if any, aspects of the MR examination are responsible for the vital sign alterations observed.

These findings are offered so that clinicians and parents anticipating MR examinations of fragile newborns may be able to weigh potential risks of the procedure against its numerous benefits.

References

1. Barkovich AJ, Westmark K, Partridge C, Sola A, Ferriero DM. Perinatal asphyxia: MR findings in the first 10 days. *AJNR Am J Neuroradiol* 1995;16:427-438
2. Castillo M, Fordham LA. MR of neurologically symptomatic newborns after vacuum extraction delivery. *AJNR Am J Neuroradiol* 1995;16:816-818
3. Dubowitz LMS, Bydder GM. Magnetic resonance imaging of the brain in neonates. *Semin Perinatol* 1990;14:212-223
4. Rollins NK, Morriss MC, Evans D, Perlman JM. The role of early MR in the evaluation of the term infant with seizures. *AJNR Am J Neuroradiol* 1993;15:239-248
5. Schouman-Claeys E, Henry-Feugeas M, Roset F, et al. Periventricular leukomalacia: correlation between MR imaging and autopsy findings during the first two months of life. *Radiology* 1993;189:59-64
6. Wiznitzer M, Masaryk TJ, Lewin J, Walsh M, Stork EK. Parenchymal and vascular magnetic resonance imaging of the brain after extracorporeal membrane oxygenation. *Am J Dis Child* 1990;144:1323-1326
7. Anderssen SH, Nicholaisen RB, Gabrielsen GW. Autonomic response to auditory stimulation. *Acta Paediatr* 1993;82:913-918
8. Gorski PA, Hole WT, Leonard CH, Martin JA. Direct computer recording of premature infants and nursery care: distress following two interventions. *Pediatrics* 1983;72:198-202
9. Long JG, Lucey JF, Philip AGS. Noise and hypoxemia in the intensive care nursery. *Pediatrics* 1980;65:143-145
10. Ho SY, Angelini A, Moscoso G. Developmental cardiac anatomy. In: Long WA, ed. *Fetal and Neonatal Cardiology*. Philadelphia, Pa: WB Saunders;1990:3-16
11. Johnson GL. Clinical examination. In: Long WA, ed. *Fetal and Neonatal Cardiology*. Philadelphia, Pa: WB Saunders; 1990:223-235
12. Versmold HT, Kitterman JA, Phibbs RH, et al. Aortic blood pressure during the first 12 hours of life in infants with birth weight of 610 to 4430 grams. *Pediatrics* 1981;67:607-613
13. Adleman RD. Neonatal hypertension. *Pediatr Clin North Am* 1978;25:99-110
14. Als H, Lawhon G, Brown E, et al. Individualized behavioral and environmental care for the very low birthweight preterm infant at high risk for bronchopulmonary dysplasia: neonatal intensive care unit and developmental outcome. *Pediatrics* 1986;78:1123-1132
15. Perlman JM, Volpe JJ. Episodes of apnea and bradycardia in the preterm newborn: impact on the cerebral circulation. *Pediatrics* 1985;76:333-338
16. Perlman JM, Goodman S, Kreusser KL. Reduction in intraventricular hemorrhage by elimination of fluctuating cerebral blood-flow velocity in preterm infants with respiratory distress syndrome. *N Engl J Med* 1985;312:1353-1357
17. Perlman JM, Volpe JJ. Suctioning in the preterm infant: effects on cerebral blood flow velocity. *Pediatrics* 1983;72:329-334
18. Rigatto H. Control of breathing in fetal life and onset and control of breathing in the neonate. In: Polin RA, Fox WW, eds. *Fetal and Neonatal Physiology*. Philadelphia, Pa: WB Saunders; 1992:790-801
19. Morin FC, Weiss KI. Response of the fetal circulation to stress. In: Polin RA, Fox WW, eds. *Fetal and Neonatal Physiology*. Philadelphia, Pa: WB Saunders, 1992:620-629
20. Rudolph AM, Heyman MA. Cardiac output of the fetal lamb: the effects of spontaneous and induced changes in heart rate on right and left ventricular outputs. *Am J Obstet Gynecol* 1973;124:183
21. Hill A, Volpe JJ. Neurologic disorders. In: Avery GB, Fletcher MA, MacDonald MG, eds. *Neonatology: Pathophysiology and Management of the Newborn*. 4th ed. Philadelphia, Pa: JB Lippincott, 1994:1123-1124
22. Lou HC, Lassen NA, Friis-Hansen B. Impaired autoregulation of cerebral blood flow in the distressed newborn. *J Pediatr* 1979;94:118-121
23. Van De Bor M, Walther FJ. Cerebral blood flow velocity regulation in preterm infants. *Biol Neonate* 1991;59:329-335

Please see the Commentary on page 1037 in this issue.