

Generic Contrast Agents

Our portfolio is growing to serve you better. Now you have a *choice*.



FRESENIUS
KABI

[VIEW CATALOG](#)

AJNR

Sequential injections of amobarbital sodium and lidocaine for provocative neurologic testing in the external carotid circulation.

J P Deveikis

AJNR Am J Neuroradiol 1996, 17 (6) 1143-1147

<http://www.ajnr.org/content/17/6/1143>

This information is current as
of May 10, 2025.

Sequential Injections of Amobarbital Sodium and Lidocaine for Provocative Neurologic Testing in the External Carotid Circulation

John P. Deveikis

PURPOSE: To present the results of a protocol for embolization in the external carotid territory that includes provocative testing with amobarbital sodium and lidocaine. **METHODS:** Provocative testing with sequential intraarterial injections of amobarbital sodium and lidocaine was done before embolization of 66 vascular pedicles in 26 patients with the following pathologic disorders: 8 meningiomas, 7 paragangliomas, 5 dural arteriovenous fistulas, 3 angiofibromas, 1 endolymphatic sac carcinoma, 1 metastatic renal carcinoma, and 1 Rendu-Osler-Weber syndrome. Findings during provocative testing and any postembolization deficits were recorded. **RESULTS:** Of the 66 vascular pedicles tested, only 1 showed positive findings on an amobarbital test, in which the patient had transient numbness in the contralateral leg. Results of lidocaine tests were positive in 7 cases, in which cranial nerve deficits were suspected on the basis of anatomic findings. All deficits resolved within 15 minutes. If results of amobarbital or lidocaine tests were positive, large particles or coils were used for embolization. Otherwise, small particles or liquid agents were used. There were no complications after embolization. **CONCLUSIONS:** Provocative testing with amobarbital can reveal dangerous anastomoses. Testing with lidocaine can show vascular supply to the cranial nerves. With the use of appropriate protocols, embolization in the external carotid territory can be done with minimal risk.

Index terms: Arteries, carotid, external; Interventional neuroradiology, provocative testing

AJNR Am J Neuroradiol 17:1143-1147, June 1996

Endovascular therapy in the external carotid territory requires a thorough understanding of potential supply to the central and peripheral nervous system in order to prevent neurologic complications. Provocative testing, by injecting anesthetic agents into the vessel to be embolized, may indicate the neural tissue at risk and make it possible to avoid damaging that tissue. Horton and Kerber (1) have described a provocative test consisting of lidocaine injections into external carotid branches to be embolized as a means of predicting which patients might be at risk for cranial nerve palsies after embolization of those branches. However, it is uncertain whether these lidocaine challenges can indicate

the presence of dangerous external carotid to internal carotid or vertebral artery anastomoses. Moreover, there are serious questions regarding the safety of routinely injecting quantities of lidocaine into the cerebral circulation, since even small doses injected into the head and neck region have resulted in seizures and cardiorespiratory arrest, presumably as a consequence of intravascular injection (2).

Considerable experience with amobarbital sodium injections in the cerebral circulation has been amassed since the introduction of the Wada test for determining speech and memory dominance (3). It follows that amobarbital injections might be used to help identify anastomoses to the cerebral circulation (4). However, there have been no indications that amobarbital injections can show vascular supply to the cranial nerves. For these reasons, we developed a protocol of provocative testing that involves the use of both these agents in a sequential fashion. We hypothesized that an initial test with amobarbital could theoretically exclude anastomo-

Received June 6, 1994; accepted after revision December 29, 1995.

From the Department of Radiology, University of Michigan Hospitals, Ann Arbor.

Address reprint requests to John P. Deveikis, MD, Department of Radiology, University of Michigan Hospitals, 1500 E Medical Center Dr, Ann Arbor, MI 48109.

AJNR 17:1143-1147, Jun 1996 0195-6108/96/1706-1143

© American Society of Neuroradiology

ses to the cerebral circulation. Then, once those dangerous anastomoses were ruled out, lidocaine injections could be given to help exclude cranial nerve supply. This article describes the results of such a protocol for provocative testing in the external carotid territory.

Materials and Methods

The protocol for embolization in the external carotid territory requires that patients be awake and minimally sedated. Baseline neurologic examinations are done to determine whether there is any preexisting neurologic deficit. Guiding catheters (4F to 6F) are placed in the external carotid artery and microcatheters (1.5F to 3F) are coaxially advanced in the vessel to be embolized. A superselective digital subtraction study is performed and is carefully evaluated to ascertain the presence of any dangerous anastomoses to the cerebral circulation. If a dangerous anastomosis is found, the catheter is placed distal to the anastomosis, if possible, or the anastomosis is occluded with a microcoil to divert flow away from the cerebral circulation. This maneuver is done to minimize the potential entry of pharmacologic agents into the cerebral circulation, particularly the vertebrobasilar system, where the anesthetic agents may cause respiratory depression.

When it is confirmed that no angiographically apparent cerebral anastomoses are seen, amobarbital sodium (Amytal, Eli Lilly, Indianapolis, Ind), reconstituted to 50 mg/mL with sterile water and mixed with nonionic contrast material (Omnipaque 300, Sanofi Winthrop, NY) in a 1:1 ratio, is injected through the microcatheter, which is then flushed with sterile saline. A dose of 30 mg of amobarbital is injected for each test, and the injection is done under real-time digital subtraction angiography at rates sufficient to fill the vessel without reflux. A repeat neurologic examination is done, paying special attention to the cerebral lobe or hemisphere that is expected to be at greatest risk, given the vessel that is being tested. If no deficits occur after amobarbital injection, the results of that test are considered negative, and a lidocaine test is then done. Two percent cardiac lidocaine hydrochloride partially buffered (to reduce pain on injection) with six drops of 4.2% sodium bicarbonate injection per 10 mL of lidocaine, and mixed with nonionic contrast material in a 1:1 ratio, is also injected through the microcatheter. A dose of 20 mg of lidocaine is given for each test, and is also injected under real-time digital subtraction angiography. The patient is reexamined, testing the cranial nerves, with particular attention to the one considered at greatest risk. If no deficits are encountered, the results of the lidocaine test are considered negative and the vessel is embolized using small particles or liquid embolic agents. These tests are repeated as necessary if obvious hemodynamic changes occur during embolization or if the catheter is moved.

If neurologic changes occur with either amobarbital or lidocaine injections, the test results are considered positive. With positive amobarbital test results, lidocaine test-

ing in that vessel is not done. The catheter may be repositioned to avoid the dangerous anastomosis to the cerebral circulation, or the anastomosis may be occluded by using a microcoil. Then the vessel is retested with amobarbital. When positive results of a lidocaine test are encountered, the catheter may be repositioned and the test repeated, or embolization may be performed by using particles large enough to avoid distal occlusion of the vasa nervorum. Generally, polyvinyl alcohol particles (Contour emboli, Interventional Therapeutics, South San Francisco, Calif) at least 500 μ m in diameter were used under these circumstances.

This method was used for embolization of the external carotid territory in 26 patients with the following pathologic disorders: 8 meningiomas, 7 paragangliomas, 5 dural arteriovenous fistulas, 3 juvenile angiofibromas, 1 endolymphatic sac carcinoma of the temporal bone, 1 maxillary metastatic renal cell carcinoma, and 1 Rendu-Osler-Weber syndrome in which the patient had epistaxis. Twenty patients had embolization preoperatively; the rest were treated with embolization alone. In the 26 patients studied, a total of 66 vascular pedicles were tested as part of the embolization protocol. Patients requiring embolization under general anesthesia, or who were comatose, severely demented, or otherwise unable to cooperate for provocative testing, were not included in the study. Responses to provocative testing were recorded, and patients were followed up for a minimum of 24 hours to watch for any postembolization deficits. Patients' medical records were also reviewed to determine whether any neurologic deficits occurred after surgery in those who underwent surgery.

Results

Most patients reported mild to moderate discomfort with lidocaine injections. Generally, they experienced a burning and/or pressure sensation somewhat greater than that produced by nonionic contrast material alone. They reported no significant discomfort with amytal injections. No other appreciable problems were related to the provocative testing.

Of the 66 vascular pedicles tested, only 1 showed positive findings on an amobarbital test. In this case, the middle meningeal artery was catheterized for embolization of a cavernous dural arteriovenous fistula. Injection of amobarbital in this artery resulted in immediate numbness in the contralateral lower extremity. This deficit resolved in approximately 10 minutes. Examination of the superselective angiogram (Fig 1) showed that the sphenoidal branch filled not only the fistula but also the ophthalmic artery via the meningo/ophthalmic collateral. Via retrograde filling of the ophthalmic artery,

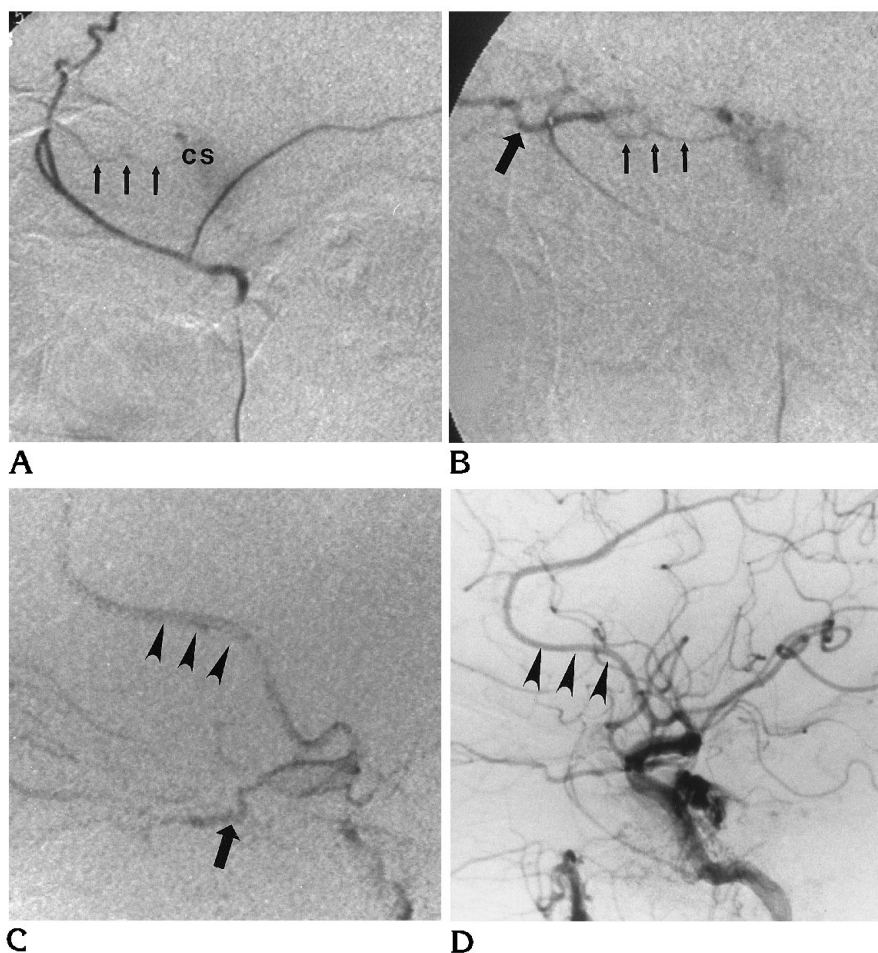


Fig 1. Sixty-two year-old woman with cavernous dural arteriovenous fistula in whom results of amobarbital testing were positive.

A, Lateral digital subtraction angiogram (DSA) of proximal right middle meningeal artery. Sphenoidal branch (arrows) fills the cavernous sinus (CS).

B, Lateral DSA of sphenoidal branch injection again shows supply to fistula (small arrows), but ophthalmic artery also fills (large arrow).

C, Lateral DSA of a more forceful hand injection fills ophthalmic artery (arrow), which then fills the anterior cerebral artery (arrowheads) via the supraclinoid internal carotid artery.

D, Lateral DSA of right common carotid arteriogram. Compare appearance of anterior cerebral artery (arrowheads) with that in C.

the supraclinoid carotid and anterior cerebral arteries could be seen to fill after a fairly forceful hand injection of contrast material through the microcatheter (Fig 1C). This collateral flow to the anterior cerebral territory was believed to explain the patients' symptoms associated with the amobarbital injection. The middle meningeal supply was later embolized with microcoils (Target Therapeutics, Fremont, Calif) without complications. This, and additional embolizations, resulted in complete angiographic and clinical cure of the lesion.

The one vessel that produced positive results on an amobarbital test was not tested with lidocaine because of concerns about the effect of lidocaine on the central nervous system. Of the remaining 65 vessels tested with lidocaine, there were 7 positive test results. Two proximal middle meningeal tests caused maxillary nerve deficits. A terminal internal maxillary test caused numbness in the ipsilateral maxillary division of the trigeminal nerve. An angular ar-

tery test caused numbness in the maxillary and mandibular divisions. An accessory meningeal artery test caused mandibular nerve deficit. A test of the stylomastoid branch of the posterior auricular artery caused ipsilateral facial nerve paralysis. When a neuromeningeal branch of the ascending pharyngeal artery was tested with lidocaine, the patient had difficulty swallowing and pharyngeal anesthesia, indicating glosso-pharyngeal and/or vagus nerve deficits.

Most of these deficits resolved within 5 minutes of the injection; all resolved within 15 minutes. Three of these positive lidocaine test results were repeated 20 minutes after the first test. The results of the lidocaine test were repeatable, with identical neurologic findings on the repeat tests. Negative lidocaine test results were also found to be repeatable in four of the vessels tested. In those cases, an additional 60 to 80 mg of lidocaine was injected to lessen the pain of alcohol embolizations in these vessels. These additional doses of lidocaine similarly

produced no neurologic deficits when the initial test result was negative.

When both the amobarbital and lidocaine test results were negative, the vessels were embolized with small particles (under 300 μm in diameter) or liquid embolic agents, such as alcohol or cyanoacrylates. There were no complications following embolization. Of the 20 patients who later underwent surgery, 3 had persistent postoperative complications. One patient with a tumor of the carotid body and another with a glomus vagale tumor (paraganglioma) suffered vagus neuropathies after surgery, with hoarseness and dysphagia, requiring long-term tube feedings. Another patient with a clival meningioma had postoperative aphasia related to left temporal lobe retraction injury.

Discussion

Embolization of the external carotid circulation is not without risk. Significant neurologic complications have been reported, including cerebrovascular ischemia related to external carotid to internal carotid or vertebral collaterals (5) (M. L. Thomas, H. L. Walters, "Hemiplegia as a Complication of Therapeutic Embolization of the Internal Maxillary Artery," *AJNR Am J Neuroradiol* 1980;1:283, abstract) as well as cranial nerve damage related to disruption of neural blood supply (6, 7). One potential way to reduce these neurologic complications is to catheterize superselectively the vessel distal to any potential extracranial-to-intracranial anastomosis or to a potential cranial nerve supply. However, it may not be technically feasible to do so in every case, and, furthermore, there may be dangerous anastomoses that, for whatever reason, are not visible on the preembolization angiographic studies. One could also embolize the lesions using only large particulate agents that could not pass through either the anastomotic channels to the cerebral circulations or through the small vasa nervorum supplying the cranial nerves. However, even though there have been few controlled studies comparing the efficacy of different embolic agents, there is evidence that larger particulate agents are more likely to lodge proximally in the vessel and less likely to reach the target lesion and, hence, less effective as devascularizing agents (8-10).

In the protocol presented here, the aim was to use the smallest particulate agents possible while avoiding neurologic complications by the

use of provocative testing. Superselective catheterization and superselective angiography certainly play a major role in allowing one to avoid inadvertent embolization of dangerous anastomoses. The one positive amobarbital test result in this series showed that the use of provocative testing can reveal at least some extracranial-to-intracranial anastomotic channels. The seven positive lidocaine test results showed that at least some cranial nerve vascular supply can be demonstrated. Whether *all* potential dangerous anastomoses or cranial nerve vascular supplies are revealed by this testing remains unknown. The fact that these lidocaine tests were done only in the face of a negative amobarbital test result shows that, at least at the doses used here, amobarbital injections do not establish cranial nerve supply. Despite the one positive amobarbital test result and the seven positive lidocaine test results, at least in this series, all vessels could be embolized in some fashion without resultant neurologic complications.

It may be true that the effectiveness of the embolization is reduced by the larger particulate agents used in the cases of positive provocative test results. However, it was decided from the outset that no neurologic deficits resulting from the embolization procedure would be acceptable. It could be argued that some of these deficits would inevitably result from the later surgical procedures. However, postoperative deficits occurred in only 3 of the 20 patients in our series who had surgery, and these postoperative deficits were not necessarily predictable even when the lidocaine test result was positive. Any additional deficits produced by the embolization procedure could also have an additive effect with postoperative injury to produce significant impairment of functional outcome.

An evaluation of this study provokes a number of unanswered questions. Would a permanent deficit inevitably result from embolization of a vessel with small particles or liquid agents in the face of a positive amytal or lidocaine test result? The controlled study needed to answer that question would most likely be ethically defensible only in an animal study, since, intuitively, one would expect that the number of neurologic deficits produced by embolization of positive-testing vessels would be unacceptably high. Are amobarbital sodium and lidocaine the ideal agents for such provocative testing? There is some evidence that sodium methohexital may have advantages over amobarbital be-

cause of its shorter action time (11). We chose amobarbital for our protocol only because of the greater experience with its use for Wada testing and preembolization provocative testing of brain arteriovenous malformation feeders. Can a similar protocol be applied to brain and spinal cord embolization procedures? Further study would be needed to determine whether lidocaine testing contributes any useful information as compared with amobarbital testing alone for embolizations in the central nervous system.

Finally, there are a number of potential complications that provocative testing cannot predict, such as those resulting from hemodynamic changes occurring during embolization, reflux of embolic material into unwanted territories, propagation of thrombus after embolization, postprocedural edema and swelling of target lesions, or complications related to catheterization of vessels. Prevention of these complications requires extensive experience, knowledge of the related anatomy and physiology, and meticulous attention to detail.

In summary, we presented a protocol for embolization in the external carotid territory that includes provocative testing with sequential intraarterial amobarbital sodium and lidocaine injections, which can reveal some dangerous anastomoses and vascular supply to the cranial nerves. With the use of appropriate protocols, external carotid territory embolizations can be performed with relative little risk of neurologic complications.

Acknowledgment

Many thanks to Peter Hedlesky for manuscript preparation.

References

1. Horton JA, Kerber CW. Lidocaine injection into external carotid branches: provocative test to preserve cranial nerve function in therapeutic embolization. *AJNR Am J Neuroradiol* 1986;7:105-108
2. *Physician's Desk Reference*. Montvale, NJ: Medical Economics; 1993; 661
3. Wada J, Rasmussen T. Intracarotid injection of sodium amytal for the lateralization of cerebral speech dominance. *J Neurosurg* 1960;17:266-282
4. Lasjaunias P, Berenstein A. *Surgical Neuroangiography: Endovascular Treatment of Craniofacial Lesions*. New York, NY: Springer-Verlag; 1987;2:54
5. Ahn HS, Kerber CW, Deeb ZL. Extra- to intracranial arterial anastomoses in therapeutic embolization: recognition and role. *AJNR Am J Neuroradiol* 1980;1:71-75
6. Metson R, Hanson DG. Bilateral facial nerve paralysis following arterial embolization for epistaxis. *Otolaryngol Head Neck Surg* 1983;91:299-303
7. DeVries N, Versluis RJJ, Valk J, Snow GB. Facial nerve paralysis following embolization for severe epistaxis. *Laryngol Otol* 1986;100:207-210
8. Flandroy P, Grandfils C, Collignon J, et al. (D,L) polylactide microspheres as embolic agent: a preliminary study. *Neuroradiology* 1990;32:311-315
9. Wakhloo AK, Juengling FD, Velthoven W, Schumacher M, Hennig J, Schwechheimer K. Extended preoperative polyvinyl alcohol microembolization of intracranial meningiomas: assessment of two embolization techniques. *AJNR Am J Neuroradiol* 1993;14:571-582
10. Latchaw RE. Commentary. Preoperative intracranial meningioma embolization: technical considerations affecting the risk-to-benefits ratio. *AJNR Am J Neuroradiol* 1993;14:583-586
11. Peters KR, Quisling RG, Gilmore R, Mickle P, Kuperus JH. Intraarterial use of sodium methohexital for provocative testing during brain embolotherapy. *AJNR Am J Neuroradiol* 1993;14:171-174