# Anatomic Moment. Hearing, I: The cochlea.

D L Daniels, J D Swartz, H R Harnsberger, J L Ulmer, K A Shaffer and L Mark

*AJNR Am J Neuroradiol* 1996, 17 (7) 1237-1241
http://www.ajnr.org/content/17/7/1237.citation

# Hearing, I: The Cochlea

David L. Daniels, Joel D. Swartz, H. Ric Harnsberger, John L. Ulmer, Katherine A. Shaffer, and Leighton Mark

The purpose of the ear is to transform mechanical energy (sound) into electric energy. The external ear collects and directs the sound. The middle ear converts the sound to fluid motion. The inner ear, specifically the cochlea, transforms fluid motion into electric energy.

The cochlea is a coiled structure consisting of two and three quarter turns (Figs 1 and 2). If it were elongated, the cochlea would be approximately 30 mm in length. The fluid-filled spaces of the cochlea are comprised of three parallel canals: an outer *scala vestibuli* (ascending spiral), an inner *scala tympani* (descending spiral), and the central *cochlear duct* (scala media) (1–7). The scala vestibuli and scala tympani contain perilymph, a substance similar in composition to cerebrospinal fluid. Indeed, there is perilymphatic communication from the scala tympani to the subarachnoid space via the cochlear aqueduct, which lies inferior to the internal auditory canal.

The cochlear duct contains endolymph, which has a significantly higher potassium content and lower sodium content than cerebrospinal fluid. The cochlear duct is separated from the scala vestibuli by the *vestibular (Reissner's) membrane* and from the scala tympani by the *basilar membrane*. The organ of Corti resides within the cochlear duct on the basilar membrane. The tectorial membrane is adherent to the roof of the organ of Corti, interposed between this structure and the endolymph. The ductus reuniens allows for endolymphatic communications between the cochlear duct and saccule.

Movement of the stapes results in transmission of fluid waves into the scala vestibuli via the cochlear recess, which lies on the medial wall of the vestibule (Fig 3). As these sound waves enter the perilymph of the scala vestibuli, they are transmitted through the vestibular membrane into the endolymph of the cochlear duct, causing displacement of the basilar membrane, which stimulates the hair cell receptors of the organ of Corti (Figs 4–7) (4, 5). It is the movement of hair cells that generates the electric potentials that are converted into action potentials in the auditory nerve fibers. The basilar membrane varies in width and tension from base to apex. As a result, different portions of the membrane respond to different auditory frequencies (2, 5). These perilymphatic waves are transmitted via the apex of the cochlea (helicotrema) to the scala tympani and eventually dissipated at the round window (Figs 3 and 4). The flexible nature of the round window diaphragm is necessary for fluid propagation. Occlusion of the round window by otosclerotic plaques may render prosthetic stapedectomy ineffective because of the incompressible nature of the labyrinthine fluid. It is interesting that the entire fluid volume of the perilymphatic spaces of the inner ear is only 0.2 mL, yet without it hearing would not be possible.

The cochlea contains a central bony axis (*modiolus*) through which the cochlear nerve travels (Figs 5, 6, 8–10). Projecting outward from the modiolus throughout its length, similar to the head of a screw, is a thin bony plate referred to as the *osseous spiral lamina* (5). These structures provide an important supportive function and allow for organized transmission of fibers of the cochlear nerve to each segment of the cochlea.

From the Section of Neuroradiology, Department of Radiology, Medical College of Wisconsin, Milwaukee (D.L.D., J.L.U., K.A.S., L.M.), the Department of Radiology, Germantown Hospital and Medical Center, Philadelphia, Pa (J.D.S.), and the Section of Neuroradiology, Department of Radiology, University of Utah Medical Center, Salt Lake City (H.R.H.).

Address reprint requests to David L. Daniels, MD, Section of Neuroradiology, Department of Radiology/DH 151, Doyne Clinic, Medical College of Wisconsin, 8700 W Wisconsin Ave, Milwaukee, WI 53226.

**Index terms:** Anatomic moments; Hearing; Temporal bone, anatomy

AJNR 17:1237–1241, Aug 1996 0195-6108/96/1708–1237 

Fig 1. Coronal computed tomography (CT) image of anterior (*A*) and middle (*M*) turns of the cochlea. *C* indicates carotid canal.

Fig 2. Coronal CT image (4 mm posterior to Figure 1). *B* indicates basal turn of the cochlea (bony covering is called the *promontory*).

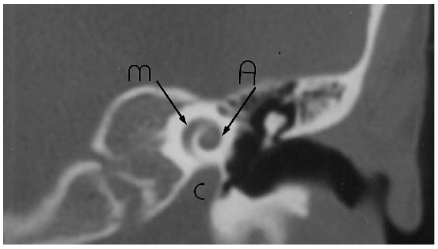


1

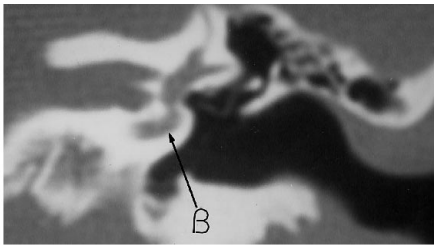


2

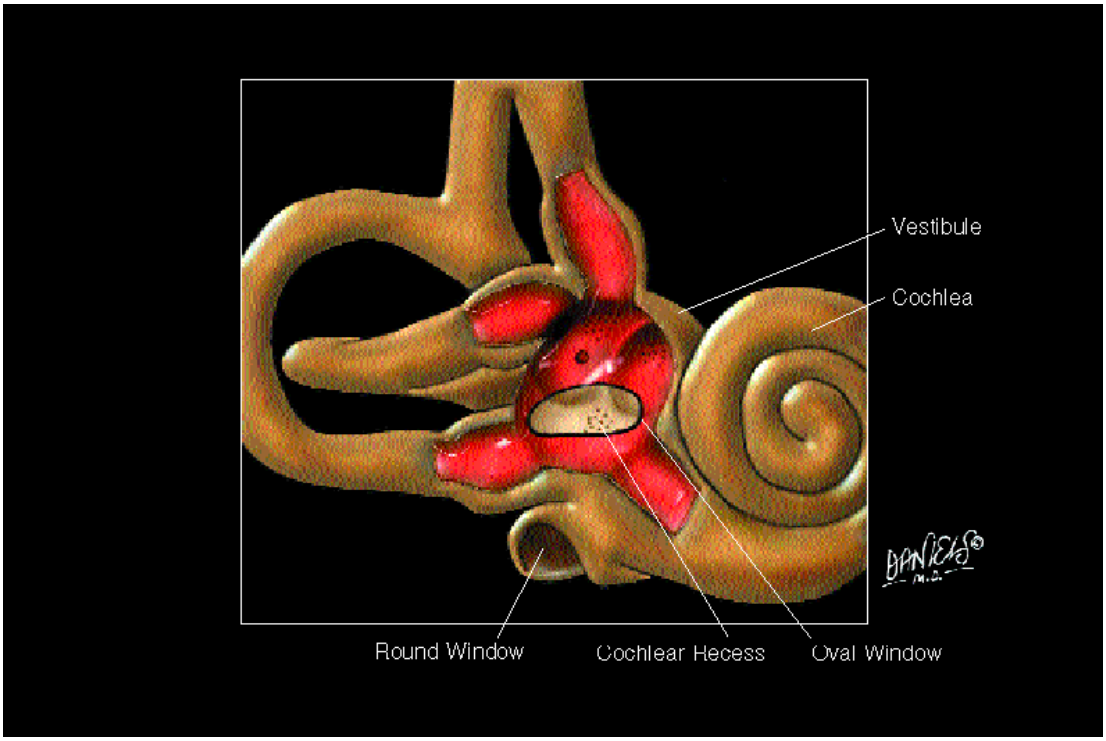


Fig 3. Lateral view of the osseous labyrinth with a transparent part of its wall. Demonstrated is the oval window at the vestibule, positioned above the round window at the posterior-inferior part of the basal turn of the cochlea. Illustrated through the oval window is the cochlear recess, which contains the posterior part of the cochlear duct (not shown) (modified from Williams et al [9], Ferner [10], Proctor [11], and Netter and Colacino [12]).

The cochlea diminishes in size from base to apex. The cochlear duct (scala media) appears triangular in cross section (5). The endosteum at the level of the cochlear duct is greatly thickened to form the spiral ligament of the cochlea. Subjacent to the ligament, in direct apposition to the endolymph of the cochlear duct, lies the stria vascularis, which contains stratified epithelium carrying a rich plexus of capillaries. Note that the basilar membrane receives it support from the osseous spiral lamina as it extends to the endosteum (spiral ligament). Sensorineural hearing loss may be categorized audiometrically into sensory (cochlear) loss and neural (retrocochlear) loss (8). Retrocochlear hearing loss implies involvement of the cochlear nerve or cochlear nuclei, as will be discussed in an upcoming Anatomic Moment. Defective function of the cochlea results in sensory (cochlear) loss. Lesions in this vicinity can be congenital, developmental (otosclerosis), inflammatory (labyrinthitis), traumatic, or erosive/destructive (cholesteatoma).

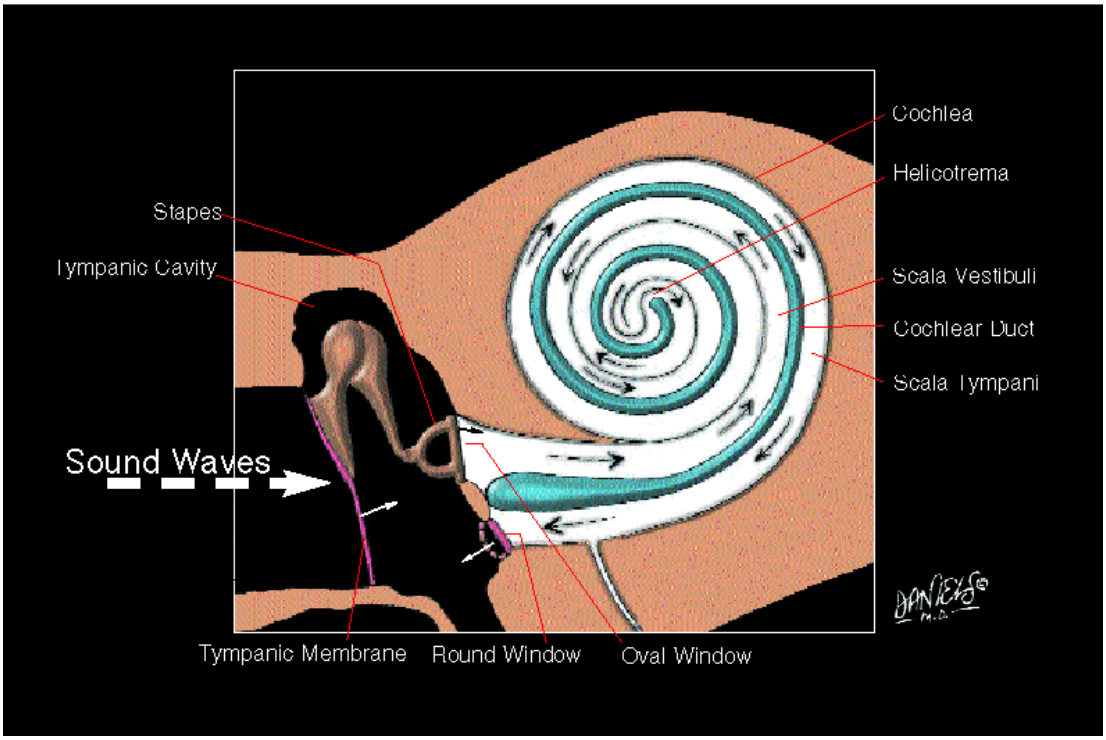


Fig 4. Frontal schematic of the tympanic cavity and cochlea. Sound waves cause tympanic membrane vibrations and ossicular movements. Movement of the stapes in the oval window produces pressure waves that travel in the perilymph from the oval window to the round window, where they are dissipated by the flexible round window diaphragm (modified from Netter and Colacino [12] and Krstic [13]).

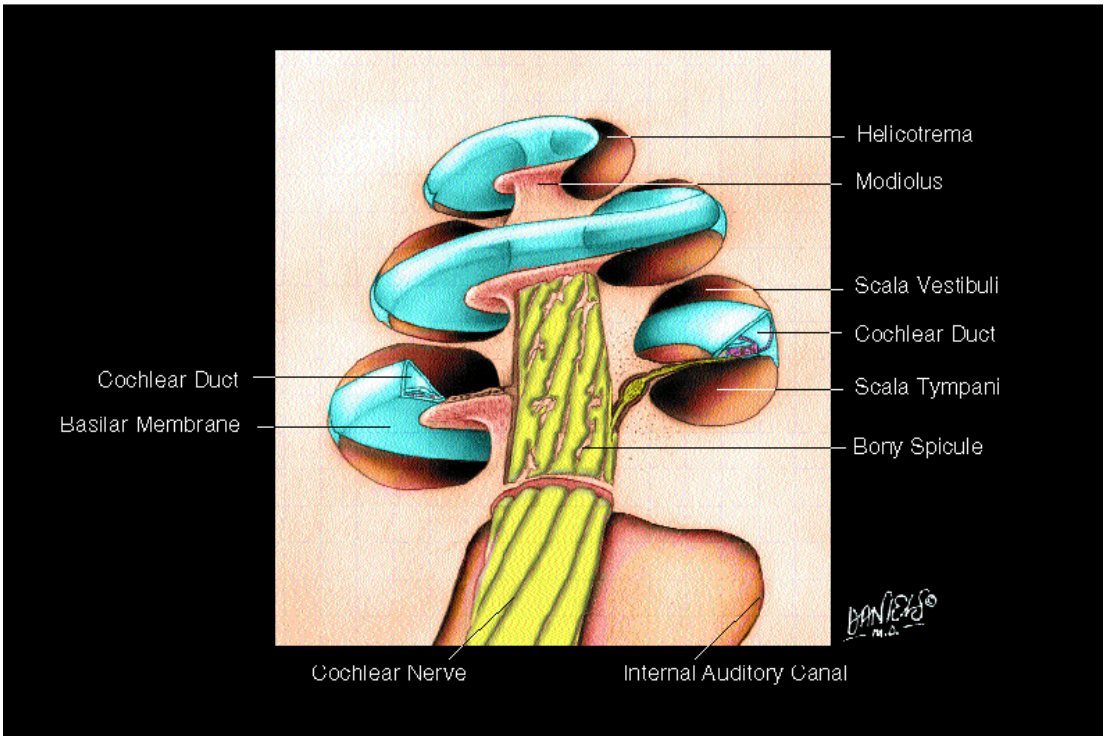


Fig 5. Dissected view of the cochlea showing its central osseous axis (modiolus) through which the cochlear nerve extends to reach the internal auditory canal. Shown is the spiraling cochlear duct within the turns of the cochlea (modified from Ferner [10] and Krstic [13]).

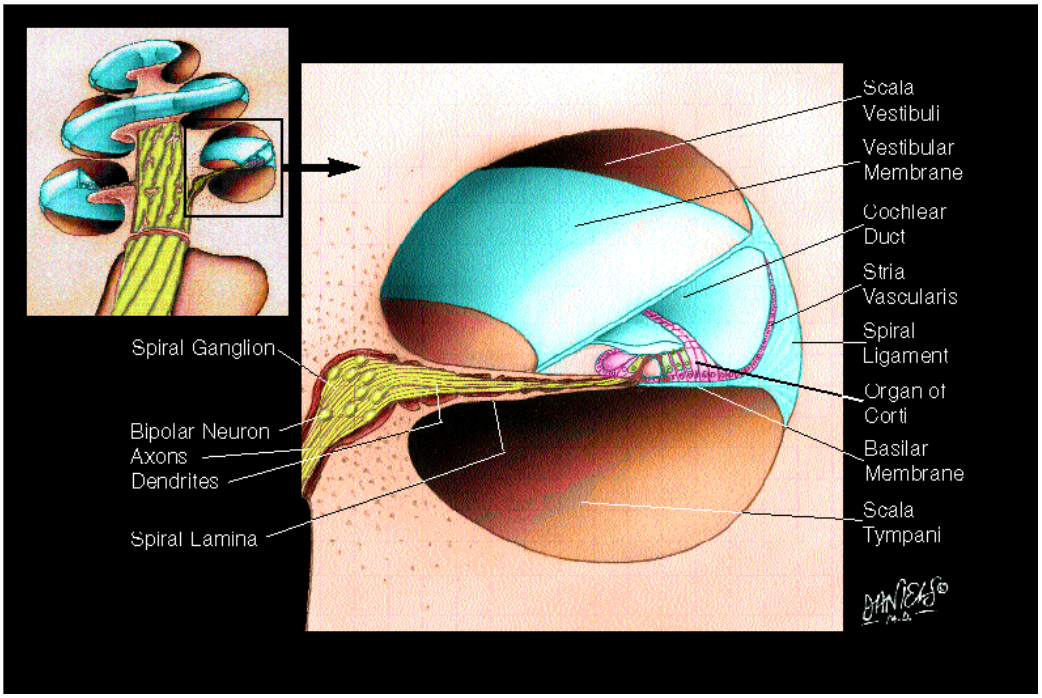


Fig 6. Magnified view of a portion of the cochlea from Figure 5 shows the cochlear duct between the scala vestibuli and the scala tympani, containing the organ of Corti positioned on the basilar membrane. The spiral ganglion is formed by bipolar neurons, whose dendrites synapse with hair cells in the organ of Corti and extend through the osseous spiral lamina. Axons of the bipolar neurons form the cochlear nerve (modified from Ferner [10], Krstic [13], and Netter [14]).

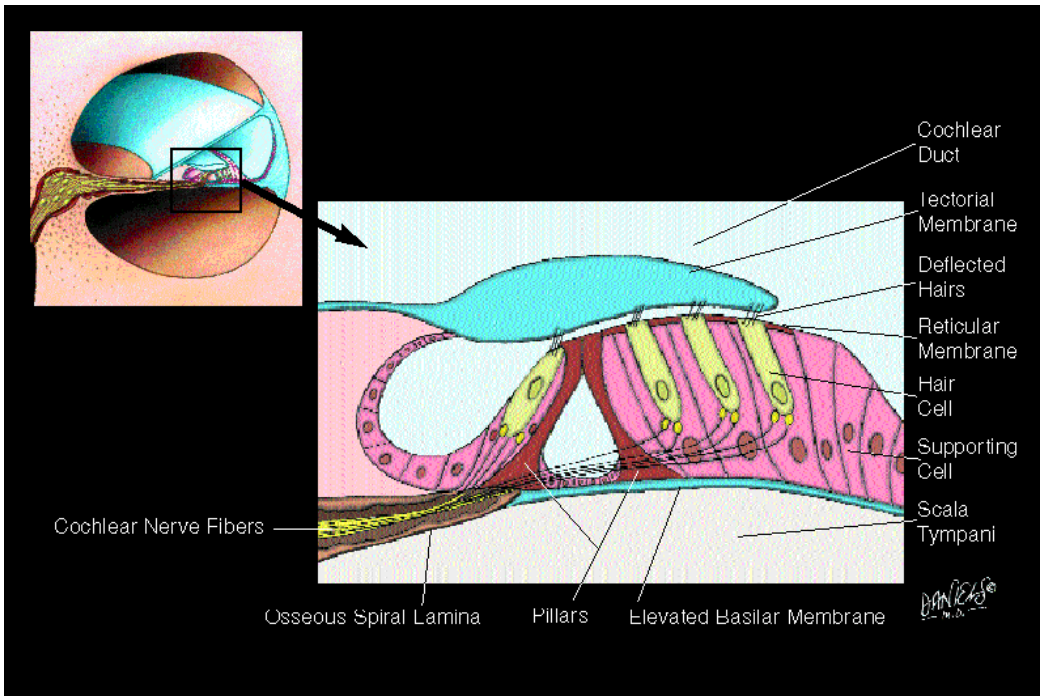


Fig 7. Magnified schematic of the organ of Corti from Figure 6. Pressure waves in the perilymph cause the vestibular membrane and, in turn, cochlear duct endolymph and then basilar membrane, to vibrate. Specific areas of the basilar membrane are displaced in response to specific sound frequencies (ie, high-frequency sounds at the basal region and low-frequency sounds toward the apex of the cochlea). When the specific part of the basilar membrane is displaced upward, the immobile tectorial membrane slides across the surface of hair cells, deflecting hairs embedded in the tectorial membrane. The resulting hair cell excitation causes cochlear nerve fiber excitation (modified from Krstic [13] and Netter [14]).

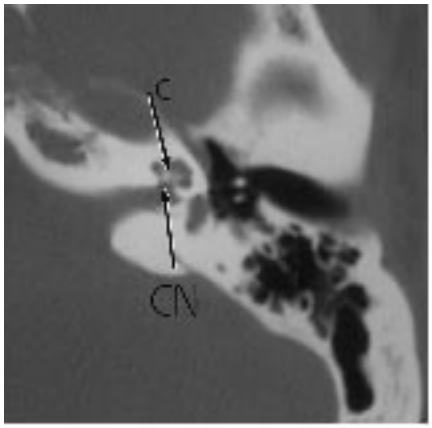


8

Fig 8. Axial CT image at level of oval window. *C arrow* indicates modiolus/osseous spiral lamina within apex of the cochlea; *CN arrow*, foramen for cochlear nerve (at fundus of internal auditory canal). Compare with Figure 5.

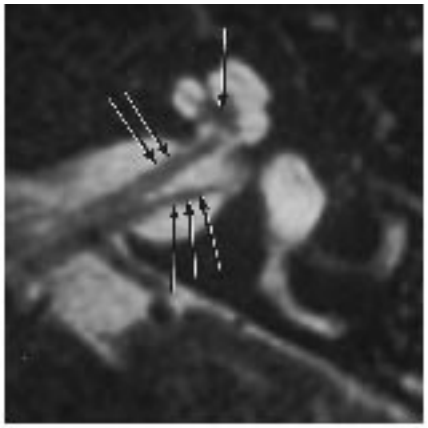

9

Fig 9. Axial thin-section T2-weighted fast spin-echo magnetic resonance image obtained with phased-array coil. *Single arrow* indicates modiolus/osseous spiral lamina; *double arrows*, cochlear nerve within internal auditory canal; and *triple arrows*, inferior vestibular nerve within internal auditory canal. Note that this image is obtained within the inferior half of the internal auditory canal.

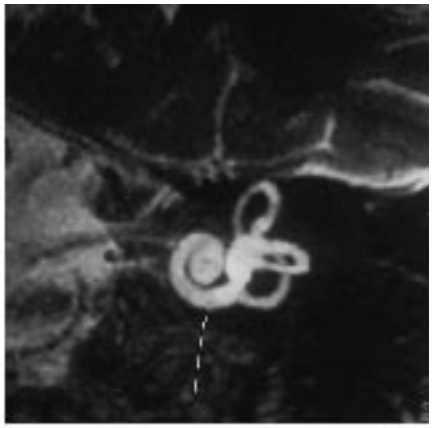

10

Fig 10. Coronal maximum intensity projection reconstruction of T2-weighted thin-section fast spin-echo magnetic resonance images obtained with phased-array coil reveals the entirety of the normally coiled cochlea (*arrow* indicates basal turn) as well as the three semicircular canals.

## References

1. Bergeron RT. In: Bergeron RT, Som PM, eds. *Head and Neck Imaging*. St Louis, Mo: Mosby; 1992:chap 13, sec 1
2. Wilson-Pauwels L, Akesson EJ, Stewart PA, eds. *Cranial Nerves: Anatomy and Clinical Comments*. Toronto, Canada: BC Decker Inc; 1988:97–112
3. Schuknecht H. *Pathology of the Ear*. 2nd ed. Philadelphia, Pa: Lea & Febiger; 1993:45–66
4. Montgomery RL. *Head and Neck Anatomy with Clinical Correlations*. New York, NY: McGraw-Hill Book Co; 1981:302–311
5. Berkovitz BKB, Moxham BJ. *A Textbook of Head and Neck Anatomy*. St Louis, Mo: Yearbook Medical Publishers; 1988:362–388, 471–473
6. Daube JR, Reagan TJ, Sandok BA, Westmoreland BF. *Medical Neurosciences: An Approach to Anatomy, Pathology and Physiology by Systems and Levels*. New York, NY: Little Brown & Co; 1986:357–365
7. Heimer L. *The Human Brain and Spinal Cord: Functional Neuroanatomy and Dissection Guide*. 2nd ed. New York, NY: Springer-Verlag
8. Swartz JD. Contemporary imaging approach to sensorineural hearing loss. *Radiographics* 1996;16:561–574
9. Williams PL, Warwick R, Dyson M, Bannister LH, eds. *Gray's Anatomy*. 37th ed. London, England: Churchill Livingstone; 1989: 1229–1234
10. Ferner H, ed. *Pernkopf Atlas of Topographical and Applied Human Anatomy*. Baltimore, Md: Urban & Schwarzenberg; 1980: 162, 163, 167, 168
11. Proctor B. *Surgical Anatomy of the Ear and Temporal Bone*. New York, NY: Thieme Medical Publishers Inc; 1989:90, 136, 137
12. Netter FH, Colacino S, eds. *Atlas of Human Anatomy*. Summit, NJ: Ciba-Geigy Corp; 1989: plates 90, 91
13. Krstic RV. *Human Microscopic Anatomy: An Atlas for Students of Medicine and Biology*. Berlin, Germany: Springer-Verlag; 1991: 547, 572, 573
14. Netter FH. In: Brass A, ed. *The CIBA Collection of Medical Illustrations: Nervous System*. CIBA 1986;1:176