AJNR

Calcified amyloidoma of the larynx.

R Rodríguez-Romero, B Vargas-Serrano, B Cortina-Moreno, J M Fernández-Gallardo and J L Cervera-Rodilla

AJNR Am J Neuroradiol 1996, 17 (8) 1491-1493
http://www.ajnr.org/content/17/8/1491

This information is current as of October 12, 2024.

Calcified Amyloidoma of the Larynx

Rafael Rodríguez-Romero, Blanca Vargas-Serrano, Begoña Cortina-Moreno, Juan M. Fernández-Gallardo, and Juan L. Cervera-Rodilla

Summary: We describe a case of laryngeal amyloidoma in a 39-year-old man in whom CT examination disclosed a calcified soft-tissue mass arising in the epiglottis. The presence of focal calcifications suggested a cartilaginous tumor.

Index terms: Larynx, neoplasms; Amyloidosis

Amyloidosis is not a single entity but rather a group of diseases characterized by the presence of extracellular deposition of insoluble, fibrillar, proteinaceous material with a well-defined, β-pleated sheet ultrastructure (1).

Clinically, amyloidosis is categorized into two main forms, systemic and localized (2). Systemic amyloidosis is usually related to plasma cell dyscrasias or chronic inflammatory conditions. Familial amyloidosis, an uncommon autosomal recessive disorder, presents clinically with systemic manifestations. Localized amyloidosis includes organ-limited and focal amyloidosis. Neither is associated with systemic disease. Focal amyloidosis (amyloidomas) are localized amyloid deposits and have been described in a variety of sites in the head and neck, including the orbit, nasopharynx, lips, floor of the mouth, tongue, larynx, and tracheobronchial tree (3–5).

Although calcification is not an unusual finding in head and neck amyloidomas (4, 5), the detection of a laryngeal calcified mass has been considered characteristic or even pathognomonic of chondrosarcoma (6–8). We describe a patient with a calcified amyloidoma of the epiglottis.

Case Report

A 39-year-old man, a smoker, presented with a 1-month history of dysphagia and hoarseness. He was in good health with no history of previous illness. Physical examination and routine laboratory test results were normal.

A computed tomographic (CT) scan revealed a well-defined, homogeneous, soft-tissue mass arising in the epiglottis, without extension to the aryepiglottic folds, the false vocal cords, or the preepiglottic space (Fig 1A). The mass showed no enhancement on contrast-enhanced scans and contained scattered foci of stippled calcification (Fig 1B and C).

A magnetic resonance (MR) study, performed on a superconductive 0.5-T imager, showed a homogeneous mass of the epiglottis that was isointense with surrounding neck muscles on T1-weighted (Fig 1D) and proton density–weighted images. Several foci of low-intensity signal that could represent calcifications were detected within the mass (Fig 1E). The T2-weighted images were degraded by motion artifacts.

At direct laryngoscopy a smooth, firm, yellowish mass was seen on the laryngeal side of the epiglottis. A biopsy specimen was obtained.

Histologic examination showed normal stratified squamous epithelium. Under the epithelial layer, an acellular, amorphous, eosinophilic material was present. Apple green birefringence of a Congo red–stained section at polarized light examination confirmed the presence of amyloid. Additional laboratory studies performed to rule out systemic amyloidosis or plasma cell dyscrasias were negative. The patient declined any surgical intervention and follow-up CT studies at 6 and 12 months showed no enlargement of the laryngeal mass.

Discussion

Approximately 9% to 15% of amyloid tumors are localized (1, 2), with involvement of the bladder, lung, skin, and larynx accounting for more than half the cases, although they have been identified in nearly every tissue in the body.

Amyloidosis occurs twice as frequently in the larynx as in any other part of the head and neck, and takes the form of tumorlike or diffuse infiltrates (9); however, it is estimated that fewer

Received August 23, 1995; accepted after revision December 12.

From the Servicio de Radiodiagnóstico, Hospital Severo Ochoa, Av Orellana s/n, 28914 Leganés, Madrid, Spain. Address reprint requests to Rafael Rodríguez-Romero, MD.

AJNR 17:1491–1493, Sep 1996 0195-6108/96/1708–1491 © American Society of Neuroradiology

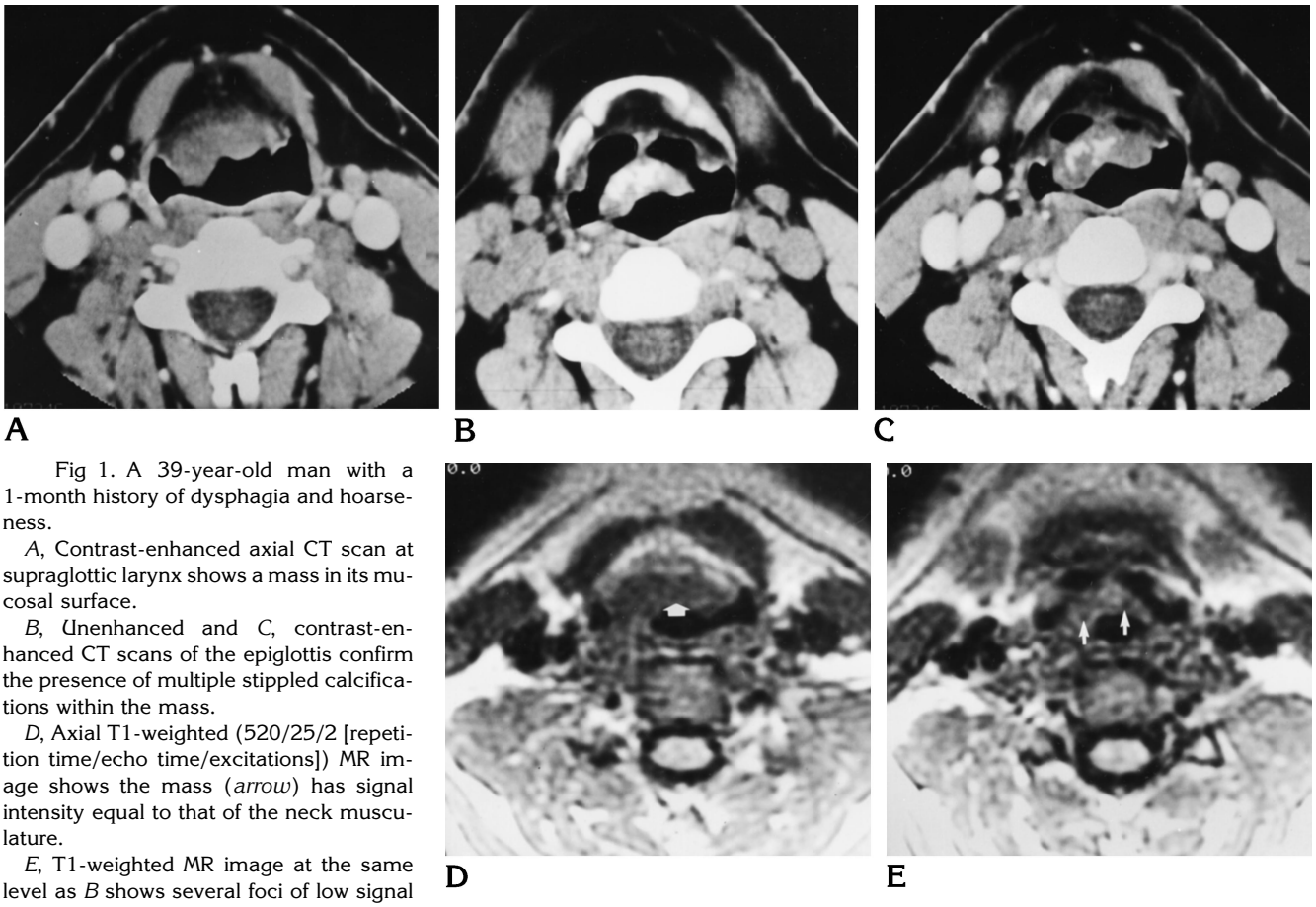

Fig 1. A 39-year-old man with a 1-month history of dysphagia and hoarseness.

A, Contrast-enhanced axial CT scan at supraglottic larynx shows a mass in its mucosal surface.

B, Unenhanced and *C*, contrast-enhanced CT scans of the epiglottis confirm the presence of multiple stippled calcifications within the mass.

D, Axial T1-weighted (520/25/2 [repetition time/echo time/excitations]) MR image shows the mass (*arrow*) has signal intensity equal to that of the neck musculature.

E, T1-weighted MR image at the same level as *B* shows several foci of low signal intensity within the mass (*arrows*) that might be calcifications.

than 1% of the benign tumors in the larynx are amyloidomas. The supraglottic larynx, especially the false vocal cords, is the most commonly involved region (4).

The cause of amyloidosis is not known. Some investigators believe that amyloid deposition stems from a derangement in immunoregulation after protracted antigenic challenge that results in an immunoglobulin precursor protein that polymerizes in the extracellular space, producing amyloid (3). Others believe that amyloid tumors arise from isolated clones of plasma cells, producers of immunoglobulin light chains that through enzymatic degradation form amyloid fibrils in connective tissues (1). Still others have suggested that localized amyloidosis may arise from burnt-out extramedullary plasmacytomas (2).

Clinically, laryngeal amyloidoma produces local signs and symptoms. Patients usually have hoarseness, breathing difficulty, and pain (4). Hemoptysis is an uncommon but potentially fatal complication caused by mucosal ulceration (10). Peak occurrence is between the ages of 40 and 60 years. Men are affected three times as often as women (4).

Laryngeal amyloidomas are usually benign masses, but in extralaryngeal locations (ie, spine, orbit, and skull base) they are aggressive, slow-growing lesions that often produce osteolysis, cranial nerve deficits, or exophthalmos and diplopia (3, 5). Development of generalized amyloidosis after laryngeal amyloidomas has not been reported in the literature to our knowledge, but medical workup to rule out systemic amyloidosis and plasma cell dyscrasias is recommended (1).

Amyloidomas are diagnosed by means of tissue biopsy. Amyloid typically stains with Congo red and produces a characteristic green birefringence and dichroism under polarized light (11).

The CT appearance of laryngeal amyloidoma is nonspecific. The lesion looks like a relatively well defined, submucosal, homogeneous mass.

Contrast enhancement is absent or minimal. Although bone erosion has been described in skull base and spine lesions (5), head and neck amyloidomas rarely produce osteolysis. The presence of areas of localized calcification within the mass is not uncommon; it was reported in all cases of head and neck amyloidomas in one series (3), but was not present in laryngeal amyloidomas in another series (4). Our patient had focal and multiple calcifications.

The differential diagnosis of a laryngeal mass includes benign and malignant tumors and nonneoplastic masses; however, the presence of focal calcifications within a laryngeal mass has been considered by several authors as highly suggestive or even pathognomonic of chondrosarcoma (6–8). The presence of calcification also has been reported in chronic infectious diseases of the larynx, as in tuberculosis (11).

Chondrosarcomas of the larynx typically originate in hyaline cartilage. The epiglottis consists of elastic cartilage, but the observation of cases of chondrosarcoma originating from the epiglottis (8) disproves the assertion that this neoplasm does not occur in elastic cartilage.

MR imaging could play an important role in the differential diagnosis of laryngeal calcified masses, specifically between amyloidomas and cartilaginous tumors. The MR signal characteristic of amyloidoma reveals an intensity equal to that of surrounding muscles on T1-weighted images and remains isointense or slightly hyperintense on T2-weighted images (5). MR signal of laryngeal chondrosarcoma is hypointense or isointense relative to muscle on T1-weighted and proton density–weighted images, and is definitely hyperintense on T2-weighted images, which parallels the appearance of mature hyaline cartilage (6, 12). Therefore, T2 signal characteristics might help differentiate calcified amyloidoma from calcified chondrosarcoma of the larynx.

Although the CT presence of a focal laryngeal mass with multiple coarse or stippled calcifications within it suggests a cartilaginous tumor, amyloidoma should be included in the differential diagnosis. MR findings may help differentiate the two conditions.

References

1. Kyle RA, Greipp PR. Amyloidosis. *Mayo Clin Proc* 1983;58:665–683
2. Glenner GG. Amyloid deposits and amyloidosis. *N Engl J Med* 1980;302:1283–1292, 1333–1343
3. Gean-Marton AD, Kirsch CFE, Vezina LG, Weber AL. Focal amyloidosis of the head and neck: evaluation with CT and MR imaging. *Radiology* 1991;181:521–525
4. Godbersen GS, Leh JF, Hansmann ML, Rudert H, Linke RP. Organ-limited laryngeal amyloid deposits: clinical, morphological, and immunohistochemical results of five cases. *Ann Otol Rhinol Laryngol* 1992;101:770–775
5. Hegarty JL, Rao VM. Amyloidoma of the nasopharynx: CT and MR findings. *AJNR Am J Neuroradiol* 1993;14:215–218
6. Mishell JH, Schild JA, Mafee MF. Chondrosarcoma of the larynx: diagnosis with magnetic resonance imaging and computed tomography. *Arch Otolaryngol Head Neck Surg* 1990;116:1338–1341
7. Wippold FJ, Smirniotopoulos JG, Moran CJ, Glazer HS. Chondrosarcoma of the larynx: CT features. *AJNR Am J Neuroradiol* 1993;14:453–459
8. Cheung W, Leong LLY, Chan FL. Case report: chondrosarcoma of the epiglottis. *Br J Radiol* 1993;66:471–474
9. Raymond AK, Sneige N, Batsakis JG. Amyloidosis in the upper aerodigestive tracts. *Ann Otol Rhinol Laryngol* 1992;101:794–796
10. Chow LT, Chow W, Shum BS. Fatal massive upper respiratory tract haemorrhage: an unusual complication of localized amyloidosis of the larynx. *J Laryngol Otol* 1993;107:51–53
11. Aspestrand F, Kolbenstvedt A, Boysen M. CT findings in benign expansions of the larynx. *J Comput Assist Tomogr* 1989;13:222–225
12. Stiglbauer R, Steurer M, Schimmerl S, Kramer J. MRI of cartilaginous tumors of larynx. *Clin Radiol* 1992;46:23–27