

Are your **MRI contrast agents** cost-effective?

Learn more about generic **Gadolinium-Based Contrast Agents**.



FRESENIUS
KABI

caring for life

AJNR

Orbital fat edema in anorexia nervosa: a reversible finding.

P Demaerel, M C Daele, S De Vuysere, G Wilms and A L Baert

AJNR Am J Neuroradiol 1996, 17 (9) 1782-1784

<http://www.ajnr.org/content/17/9/1782>

This information is current as
of May 2, 2024.

Orbital Fat Edema in Anorexia Nervosa: A Reversible Finding

Philippe Demaerel, Maria Casteels-Van Daele, Sofie De Vuysere, Guy Wilms, and Albert L. Baert

Summary: Orbital fat edema was found in a patient with long-standing severe anorexia nervosa. The changes disappeared after the patient gained weight. The underlying mechanism remains unexplained, but the changes most likely coincide with the disappearance of fat tissue and the appearance of edema following disturbance of the electrolyte/fluid balance.

Index terms: Anorexia nervosa; Eyes, periorbital fat; Orbits, abnormalities and anomalies

Cranial computed tomography (CT) and magnetic resonance (MR) imaging have been widely used in the assessment of patients with anorexia nervosa. The most common findings are cortical and central atrophy. Changes in the subcutaneous fat have also been described. We report abnormalities in the orbital fat seen on CT scans in a patient with long-standing illness.

Case Report

A 28-year-old-woman presented with severe anorexia nervosa. Because of several treatment failures, she was referred to a pediatric department with extensive experience in the treatment of this disorder. The duration of the illness was 8 years. Her weight was 36.2 kg for a height of 165.5 cm. At 18 years of age she had weighed approximately 60 kg. On clinical examination, the skin appeared extremely atrophic and the absence of subcutaneous fat was striking. All laboratory examinations, including total serum protein and serum albumin concentration, were normal.

A brain CT scan disclosed an enlarged ventricular system and widening of the sulci. The orbital fat and the subcutaneous fat over the temporalis muscle appeared homogeneously hyperdense (Fig 1). The globes were retracted inward. Therefore, pseudotumor was not considered a likely diagnosis.

The patient was seen weekly on an outpatient basis and her weight increased to 44.3 kg over a period of 6 months. At that time, she was involved in a road traffic accident as a cyclist. Brain and orbital CT scans, obtained to exclude hematoma or fracture, showed that the orbital fat had a normal density and the globes were normal in position (Fig 1).

Discussion

Anorexia nervosa is characterized by aversion to food and a progressive weight loss to the point of emaciation. Cortical and central atrophy have been reported in several series of patients with anorexia nervosa (1, 2). Both CT and MR findings have been described, but the origin of the morphologic changes remains unexplained. A smaller mean height of the pituitary gland has been noted on MR images (2).

During early fasting, fat mobilization is promoted by falling levels of insulin and increased sympathetic nerve activity to the adipose tissue. Early rapid proteolysis occurs, with amino acid mobilization from muscle gluconeogenesis and production of urinary urea nitrogen. As part of the life-saving adaptation to total starvation, the body gradually converts from glucose and amino acid economy to a fat-derived fuel economy (3). CT has been used to measure the body fat distribution in patients with anorexia nervosa. Mayo-Smith et al (4) found a fivefold decrease in subcutaneous fat and only a twofold decrease of intraabdominal fat. It is accepted that the failure to ingest sufficient calories may lead to the complete disappearance of gross adipose tissue from the subcutaneous fat depot (3).

The mechanism of these alterations remains unknown, but the normal lipid metabolism is a dynamic biological steady state, including synthesis and deposition/mobilization and degradation of body lipids.

In one study (5), subcutaneous fat edema was described in nine of 14 patients with a known disease affecting the mesentery and mesenteric edema. Hypoalbuminemia was seen in 11 of these patients and may have led to a drop in osmotic pressure and the appearance of edema.

Received August 28, 1995; accepted after revision February 8, 1996.

From the Departments of Radiology (P.D., S.D.V., G.W., A.L.B.) and Pediatrics (M.C.V.D.), University Hospitals KU Leuven (Belgium).

Address reprint requests to Philippe Demaerel, MD, Department of Radiology, University Hospitals KU Leuven, Herestraat 49, B-3000 Leuven, Belgium.

AJNR 17:1782-1784, Oct 1996 0195-6108/96/1709-1782 © American Society of Neuroradiology

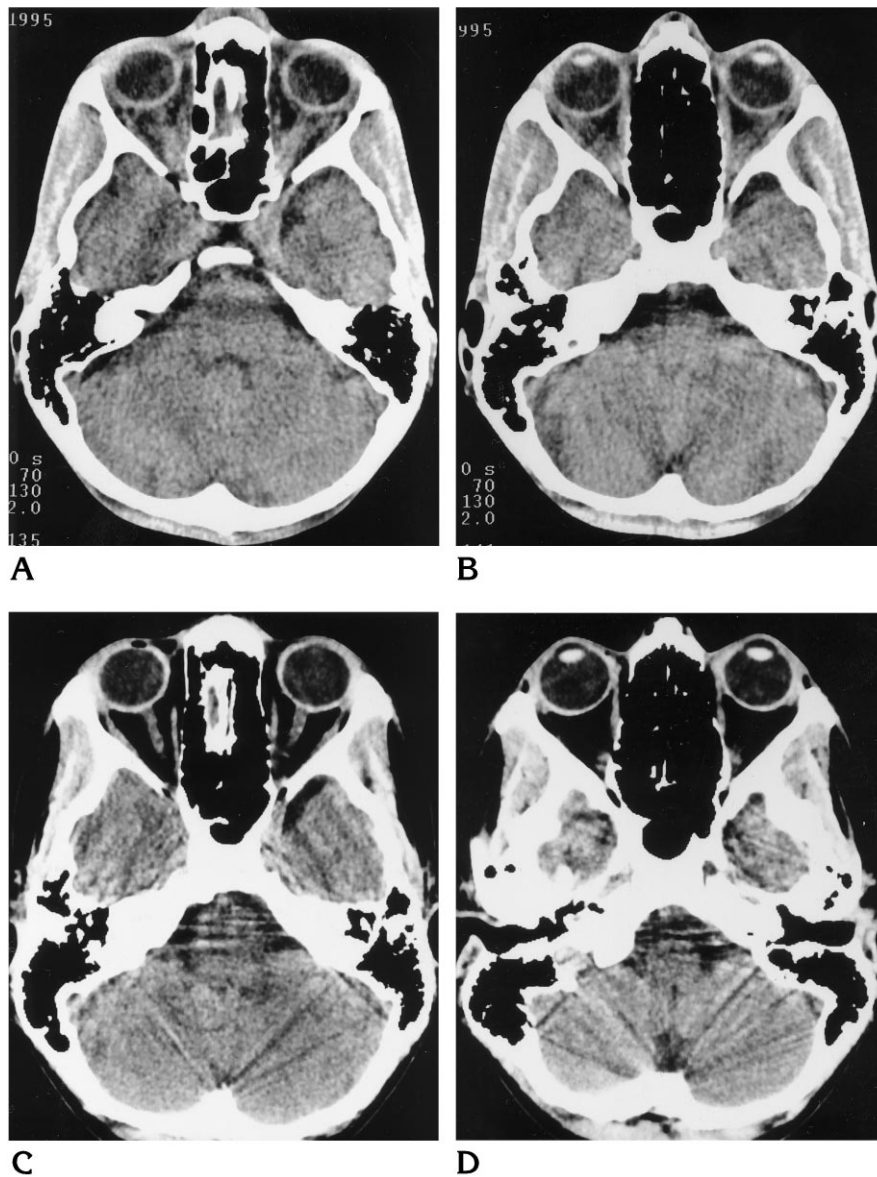


Fig 1. CT in a 28-year-old woman with severe anorexia nervosa.

A and B, Axial unenhanced brain CT scans show the diffuse increase in attenuation of the orbital and facial subcutaneous fat. The abnormalities disappeared 6 months later as the weight increased from 36.2 to 44.3 kg.

C and D, Posttreatment brain CT scans at the same level show the normal appearance of the orbital and subcutaneous fat.

The CT findings seen in our patient with anorexia nervosa were not associated with hypoalbuminemia. It is known that edema can occur without a fall in albumin concentration in cases of adult starvation. This could be explained by disturbances in electrolyte/fluid balance, but this remains hypothetical (1).

Our patient appeared marasmic with marked wasting of subcutaneous tissue and musculature. This was evident on the CT scan, where, apart from the orbital fat edema, there was also significant edema in the subcutaneous tissue over the temporalis muscle. In addition to inadequate intake of protein, the intake of carbohydrates and fat is also deficient in anorexia ner-

vosa. This type of starvation is called *marasmus*. The process of starvation varies in severity and clinical manifestation. Marasmus is at one end of the spectrum and kwashiorkor (long-standing inadequacy of protein intake in children) is at the other, and many patients fall between the two (6).

Neuroimaging findings in anorexia nervosa have been described previously; the reason orbital fat edema was observed in our patient is most likely due to the severity (40% loss of weight) and length of the illness. This report raises two questions: What is the underlying biochemical mechanism of orbital fat edema in anorexia nervosa and how can its reversibility be explained?

References

1. Palazidou E, Robinson P, Lishman WA. Neuroradiological and neuropsychological assessment in anorexia nervosa. *Psychol Med* 1990;20:521-527
2. Kornreich L, Shapira A, Horev G, Danziger Y, Tyano S, Mimouni M. CT and MR evaluation of the brain in patients with anorexia nervosa. *AJNR Am J Neuroradiol* 1991;12:1213-1216
3. White A, Handler P, Smith EL, Hill RL, Lehman IR. *Principles of Biochemistry*. 6th ed. New York, NY: McGraw-Hill; 1978
4. Mayo-Smith W, Hayes CN, Biller BMK, Klibanski A, Rosenthal DI. Body fat distribution measured with CT: correlations in healthy subjects, patients with anorexia nervosa, and patients with Cushing syndrome. *Radiology* 1989;170:515-518
5. Silverman PM, Baker ME, Cooper C, Kelvin FM. CT appearance of diffuse mesenteric edema. *J Comput Assist Tomogr* 1986;10:67-70
6. Godfrey S, Baum JD. Nutrition. In: *Clinical Pediatric Physiology*. Oxford, England: Blackwell Scientific Publications; 1989:92-133