

Are your MRI contrast agents cost-effective?

Learn more about generic Gadolinium-Based Contrast Agents.



**FRESENIUS
KABI**

caring for life

AJNR

**CT demonstration of periorbital
graft-versus-host disease.**

J W Cole, D J Quint, R J Hutchinson and G A Yanik

AJNR Am J Neuroradiol 1997, 18 (4) 730-732

<http://www.ajnr.org/content/18/4/730>

This information is current as
of April 18, 2024.

CT Demonstration of Periorbital Graft-versus-Host Disease

James W. Cole, Douglas J. Quint, Raymond J. Hutchinson, and Gregory A. Yanik

Summary: A 13-year-old boy who had undergone allogenic bone marrow transplantation for treatment of acute lymphocytic leukemia presented with bilateral periorbital rash and swelling. A CT scan showed bilateral symmetric periorbital swelling, subconjunctival fluid collections, and lacrimal gland enlargement. The patient was initially treated for presumed cellulitis. However, persistently negative regional cultures (eye, nasopharynx), a rapid response to immunosuppressive therapy after several days of nonresponse to intravenous antibiotic therapy, and, ultimately, results of a skin biopsy confirmed the diagnosis of acute graft-versus-host disease.

Index terms: Bone marrow transplantation; Orbits, diseases

Between 25% and 75% (depending on several independent variables) of patients who have undergone allogenic bone marrow transplantation for treatment of lymphoma, leukemia, or aplastic anemia contract acute graft-versus-host disease (GVHD) (1), a condition in which immunocompetent donor cells react against host tissues. Typically, GVHD manifests as an erythematous, maculopapular rash on the face, trunk, and extremities (1). Liver enzymes and bilirubin can become elevated, and, in severe cases, liver failure can occur. We present a case of GVHD mimicking periorbital cellulitis on computed tomography (CT).

Case Report

Twenty-one days after allogenic bone marrow transplantation from a matched, unrelated donor, a 13-year-old boy with a history of acute lymphocytic leukemia had severe bilateral periorbital soft-tissue swelling, which had developed over the preceding 24 hours.

He reported no fever, chills, insect bites, environmental exposures, or new drug therapy. Physical examination revealed a periorbital, erythematous, macular rash extending over both cheeks. The eyes were swollen shut and a yellowish discharge was present. The patient's temperature was 38.3°C. The white blood cell count was 9.2 (65%

polymorphonuclear cells, 8% band forms, 18% monocytes, no primitive or blastic forms).

A thin-section, unenhanced and contrast-enhanced orbital CT study (Fig 1) revealed bilateral symmetric preseptal soft-tissue swelling, bilateral water-density periconjunctival fluid collections, and symmetric enlargement and enhancement of the lacrimal glands. The abnormality extended into the soft tissues lateral to the frontozygomatic arch. While minimal postseptal inflammatory changes were noted lateral to the lateral rectus muscles bilaterally, no intraorbital abscess formation or frank bone destruction was noted. Mild sinonasal mucosal thickening was noted, but there were no sinonasal effusions.

A presumptive diagnosis of cellulitis was made and multiagent intravenous antibiotic therapy was begun. Despite this therapy, there was no significant improvement in the periorbital region and, in fact, the extent of the rash worsened over the next 48 hours, to eventually involve approximately 50% of the patient's body surface area in a patchy distribution. A punch biopsy of representative rash along the left flank revealed findings consistent with grade I GVHD. Since all bacterial, fungal, and viral cultures remained negative, high-dose steroid therapy was instituted with rapid, essentially complete resolution of the rash over the next 5 days. At discharge from the hospital (on day 8), only minimal periorbital erythema persisted and the residual rash involved less than 5% of the body surface area.

Discussion

GVHD is a major cause of morbidity and mortality among patients undergoing bone marrow transplantation (1). Hyperacute, acute, and chronic forms exist. Acute GVHD generally develops between 2 and 8 weeks after the introduction of marrow cells into a nonidentical recipient. It usually occurs after signs of engraftment (ie, rising peripheral cell counts) appear. The most commonly involved areas are the skin, gastrointestinal tract, liver, and lymphatic organs (1). Involvement of other organ systems—including conjunctivae, mucous

Received April 11, 1996; accepted after revision July 24.

From the Department of Radiology (J.W.C., D.J.Q.) and the Pediatric Bone Marrow Transplant Service, University of Michigan Hospitals, Ann Arbor.

Address reprint requests to Douglas J. Quint, B1D520, Neuroradiology, Department of Radiology, University of Michigan Medical Center, 1500 E Medical Center Dr, Ann Arbor, MI 48109.

AJNR 18:730-732, Apr 1997 0195-6108/97/1804-0730 © American Society of Neuroradiology

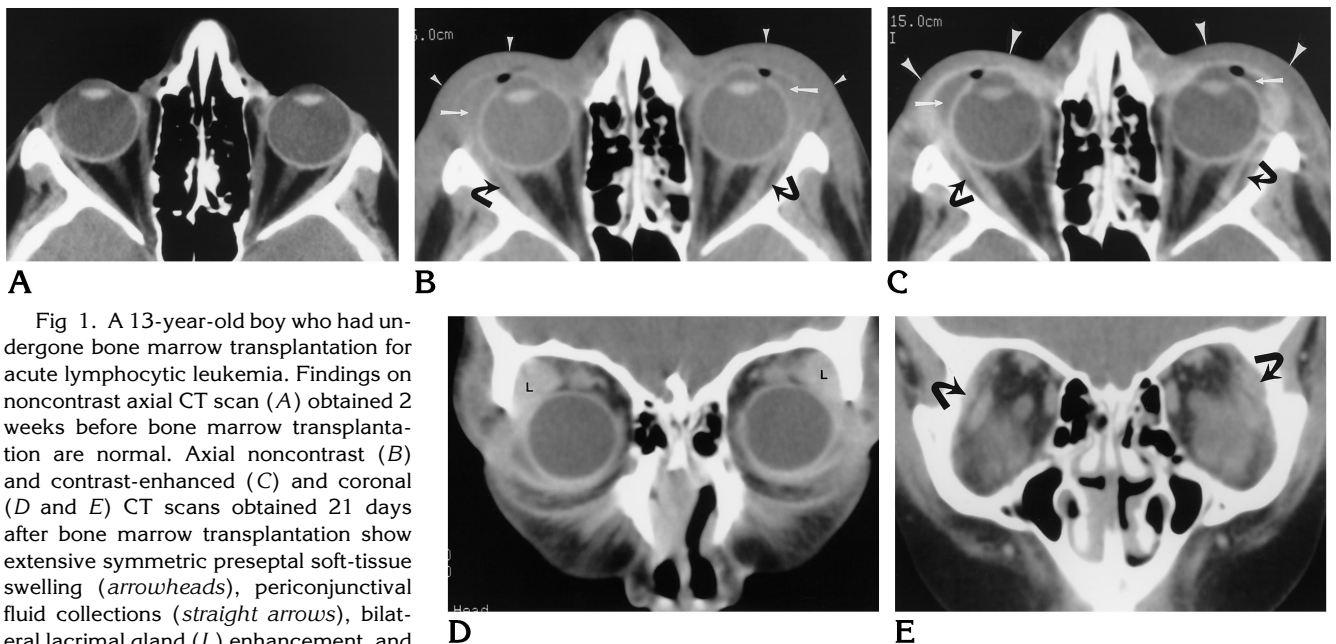


Fig 1. A 13-year-old boy who had undergone bone marrow transplantation for acute lymphocytic leukemia. Findings on noncontrast axial CT scan (A) obtained 2 weeks before bone marrow transplantation are normal. Axial noncontrast (B) and contrast-enhanced (C) and coronal (D and E) CT scans obtained 21 days after bone marrow transplantation show extensive symmetric preseptal soft-tissue swelling (*arrowheads*), periconjunctival fluid collections (*straight arrows*), bilateral lacrimal gland (L) enhancement, and minimal postseptal lateral extraconal inflammatory changes (*curved arrows*).

membranes, exocrine glands, and bronchial tree—has been described (1). The first clinical sign is usually the development of an erythematous maculopapular rash involving the volar surfaces of the hands and feet. Ears, face, shoulders, and back can also be involved initially. The rash may spread to involve the entire skin surface and is typically pruritic. Low-grade fever is common. In severe or untreated cases, blistering can occur, leading to desquamation and superinfection (1).

Grading of GVHD is done on a clinical or histopathologic basis. Clinically, cases are graded from I to IV on the basis of the percentage of body surface area involved by rash, the serum bilirubin level, and the presence or absence of abdominal symptoms (diarrhea, pain) (2). Pathologic grading is more complex and criteria vary depending on the organ in which a biopsy was done.

The pathophysiology of GVHD is quite complex, and a full discussion is beyond the scope of this article. Briefly, there are three requirements for the development of GVHD, as described by Billingham (3): introduction of immunocompetent cells, histocompatibility differences between donor and host, and inability of the recipient to destroy the donor cells. The main culprits are donor helper cells (CD4), which react to nonself antigens, elaborate cyto-

kines, including IL-2, and initiate an attack on the host tissues. To initiate an immune response, donor T cells require the presentation of nonself (recipient) antigens by cells bearing class II (or I) major histocompatibility complexes (macrophages, Langerhans cells, microglia, etc) (1). It has been theorized that the high numbers of antigen-presenting cells in the skin, liver, and gastrointestinal tract may explain the predilection of these organ systems to develop GVHD (4).

Involvement of the conjunctival tissues by GVHD is well described in the ophthalmologic literature (5), and may be the result of antigen-presenting mucosa-associated lymphatic tissues (MALT) in the recipient. Organized MALT-type tissue is found in approximately 30% of unselected conjunctival autopsy specimens obtained in patients with no history of ocular or conjunctival disease (6). West and coworkers found histology consistent with GVHD on conjunctival biopsy samples in 41 of 44 patients who had undergone bone marrow transplantation, including six patients with histologic features considered specific for GVHD who had no systemic evidence of GVHD (7). They concluded that subclinical changes of GVHD are common in the periocular tissues.

In our patient, periorbital involvement was the initial presentation, with later involvement of

more commonly affected areas. Certainly, on an immunologic basis, greater severity of disease in one tissue type versus another is easily explained on the basis of variable availability and presentation of tissue-specific minor histocompatibility antigens. Sale et al (8) have discussed this concept in explaining their observations regarding preferential involvement of perifollicular bulges in acute GVHD of the skin. The vanishing bile duct syndrome that is seen in severe GVHD has recently been reported as occurring in isolation, showing that rather severe involvement of a specific tissue type is not necessarily associated with more typical features of GVHD (9).

While it may be included in the differential diagnosis of an isolated inflammatory process of the head and neck, acute GVHD should be considered only after the exclusion of infectious causes, since patients who have had bone marrow transplantation are typically profoundly immunocompromised and infections can be quite fulminant if not treated early and aggressively. Furthermore, since the treatment of GVHD itself frequently requires aggressive immunosuppressive therapy with high intrinsic morbidity, the

diagnosis should be established by biopsy whenever possible.

References

1. Deeg H, Cottler-Fox M. Clinical spectrum and pathophysiology of acute graft-versus-host disease. *Hematology* 1990;12:311-335
2. Przepiorka D, Weisdorf D, Martin P, et al. 1994 consensus conference on acute GVHD grading. *Bone Marrow Transplant* 1995;15:825-828
3. Billingham R. The biology of graft-versus-host reactions. *Harvey Lect* 1966-1967;62:21-78
4. Ford W, Deeg H. Bone marrow transplantation, with emphasis on GVH reactions. *Transplant Proc* 1983;15:1517-1519
5. Jabs D, Wingard J, Green W, Farmer E, Vogelsang G, Saral R. The eye in bone marrow transplantation, III: conjunctival graft-versus-host disease. *Arch Ophthalmol* 1989;107:1343-1348
6. Wotherspoon A, Hardman-Lea S, Isaacson P. Mucosa-associated lymphoid tissue (MALT) in the human conjunctiva. *J Pathol* 1994;174:33-37
7. West R, Szer J, Pedersen J. Ocular surface and lacrimal disturbances in chronic graft-versus-host disease: the role of conjunctival biopsy. *Aust N Z J Ophthalmol* 1991;19:187-191
8. Sale G, Beauchamp M, Akiyama M. Perifollicular bulges, but not hair bulb keratinocytes, are attacked in graft-versus-host disease of human skin. *Bone Marrow Transplant* 1994;14:411-413
9. Yeh K, Hsieh H, Tang J, Lin M, Yang C, Chen Y. Severe isolated acute hepatic graft-versus-host disease with vanishing bile duct syndrome. *Bone Marrow Transplant* 1994;14:319-321