

Are your **MRI contrast agents** cost-effective?

Learn more about generic **Gadolinium-Based Contrast Agents**.



**FRESENIUS  
KABI**

caring for life

**AJNR**

**The developing anterior skull base: CT appearance from birth to 2 years of age.**

C J Belden, A A Mancuso and I M Kotzur

*AJNR Am J Neuroradiol* 1997, 18 (5) 811-818

<http://www.ajnr.org/content/18/5/811>

This information is current as  
of May 6, 2024.

# The Developing Anterior Skull Base: CT Appearance from Birth to 2 Years of Age

Clifford J. Belden, Anthony A. Mancuso, and Ilona M. Kotzur

**PURPOSE:** To describe the normal CT appearance of the developing anterior skull base in children 24 months of age and younger. **METHODS:** A retrospective review of the CT examinations of a healthy population of 61 subjects newborn through 24 months of age was performed. Two investigators independently reviewed the examinations, making measurements and observations regarding the length of the skull base, ossification pattern, and development of the crista galli, perpendicular plate of the ethmoid bone, and fovea ethmoidalis. **RESULTS:** At birth, the anterior skull base is largely cartilaginous. Ossification begins in the roof of the ethmoidal labyrinth laterally and spreads toward the midline. By 6 months of age, 50% of the anterior skull base has completely ossified. This percentage steadily increases over the first 2 years of life, and by 24 months, 84% of the anterior skull base is completely ossified, with a cartilaginous gap anteriorly in the region of the foramen cecum, the residual unossified portion. Ossification of the crista galli and perpendicular plate of the ethmoid bone begins around 2 months of age, shows a steady increase in ossification to 14 months of age, then increases little to 24 months of age. The fovea ethmoidalis begins development by 6 months of age, with the anterior portion the most developed in 82% of the population. **CONCLUSION:** The timing and pattern of ossification we observed differ somewhat from that reported in prior radiologic and anatomic studies, with the earliest bony bridging of the ethmoidal complex to the crista galli seen as early as 2 months of age. Development of the anterior skull base follows a predictable and orderly pattern that is important for understanding how to avoid errors in interpreting CT examinations through this region.

**Index terms:** Skull, anatomy; Skull, base; Skull, growth and development

*AJNR Am J Neuroradiol* 18:811-818, May 1997

At birth, the anterior skull base consists primarily of the central, unossified cartilage of the perpendicular plate of the ethmoid bone and crista galli, a largely unossified roof of the nasal cavity, and partially ossified ethmoidal labyrinths (1). By 2 years of life, though, the majority of the cartilage of the anterior skull base has ossified. Imaging of this region in infants and young children can be confusing because of the multiple ossification centers and because the

majority of the anterior skull base begins as cartilage. From a practical standpoint, an understanding of the appearance of the normal developing anterior skull base is important for several reasons. First, it prevents misinterpreting normal development for a pathologic state. Second, it reveals the limitations of computed tomography (CT) in evaluations of the anterior skull base in young patients. Finally, it may allow further insight into the underlying mechanism for the development of anomalies of the anterior skull base. The precise sequence of ossification and the CT appearance of the anterior skull base during the first 2 years of life are the subjects of this study.

An understanding of the development of the anterior skull base begins with a brief review of skull base embryology. The skull base is formed primarily of cartilage, with only small contributions from membranous bone (2). Development begins as a mesenchymal condensation along-

---

Received July 18, 1996; accepted after revision November 26.

Presented at the annual meeting of the American Society of Head and Neck Radiology, Los Angeles, Calif, April 1996, where Dr Belden received the Radiologist-in-Training Award.

From the Department of Radiology, University of Florida, Gainesville.

Address reprint requests to Clifford J. Belden, MD, Department of Radiology and Radiologic Science, Division of Neuroradiology, Johns Hopkins University, 600 N Wolfe St, Baltimore, MD 21287.

*AJNR* 18:811-818, May 1997 0195-6108/97/1805-0811

© American Society of Neuroradiology

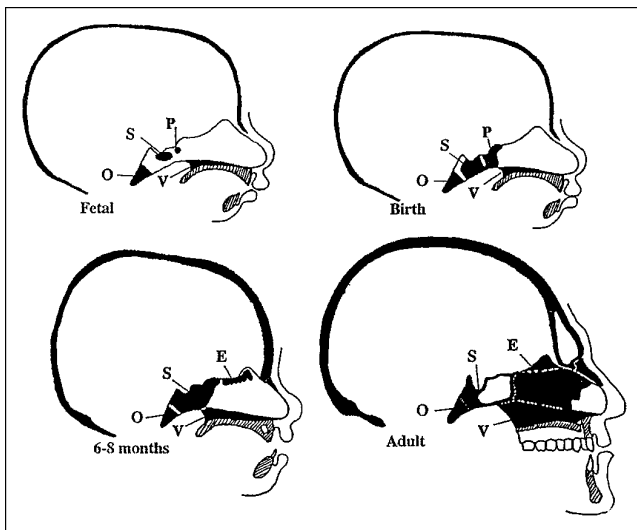


Fig 1. Skull base development. *Top left:* A midline-sagittal representation of a 5- to 6-month-old fetus shows ossification of the basioccipital (O), basisphenoidal (S), and presphenoidal (P) centers, as well as the vomer (V). *Top right:* At birth, the ossification centers are further developed, but mesethmoidal ossification has not begun. *Bottom left:* By 6 to 8 months, the presphenoidal and basisphenoidal centers have fused, and the mesethmoidal center (E) has begun to ossify. *Bottom right:* In the adult, these centers are well developed. The septal cartilage in the anterior nose remains unossified (adapted from Ford [7]).

side and in front of the notochord during the fifth and sixth fetal weeks, forming the desmocranium (3–5). Chondrification of this mesenchyme occurs around the seventh fetal week, giving rise to a platelike mass of chondroid tissue between the brain stem and notochord (the chondrocranium) (6). During the second fetal month, enchondral ossification of the chondrocranium forms the basioccipital, basisphenoidal, and presphenoidal centers (5, 7) (Fig 1). Anterior to these centers, portions of the presphenoidal cartilage give rise to the mesethmoidal cartilage, which forms the central structures of the anterior skull base, the perpendicular plate of the ethmoid bone, and the crista galli (1, 5). Cartilage derived from the nasal capsule forms the lateral portions of the anterior skull base (the ethmoidal labyrinths and roof of the nasal cavity) (1, 7, 8, 9).

## Materials and Methods

A computerized search of all CT studies performed at our institution between November 1, 1989, and December 31, 1995, revealed 2300 examinations performed in children 24 months old and younger. Of these, 124 (5%) were dedicated maxillofacial or orbital examinations. These CT scans were reexamined and a review of the subjects' med-

ical records was done, revealing 61 that met the following criteria for inclusion in our study: patients were 24 months of age or younger with no known disease or disorder that would affect skull base development or ossification, and direct axial and coronal CT scans with 3 mm or less collimation and wide window (bone) settings were available for evaluation. In reviewing the medical records, every attempt was made to exclude children who had metabolic and developmental abnormalities, microcephaly, macrocephaly, synostosis, or any other condition that could conceivably affect development of the anterior skull base. The CT scans were acquired on GE Advantage or 9800 series scanners (Milwaukee, Wis).

The 61 scans that met our requirements constitute the basis for our study. Two of the authors independently reviewed the scans, making observations and measurements as outlined below. Measurements were made with hand calipers, and significantly discrepant measurements were reviewed a second time and a consensus reached. This investigation is one part of a larger study that also includes the development of the nasal cavity and sinuses (C. J. Belden, I. M. Kotzur, A. A. Mancuso, "Development of the Nasal Cavity and Choana: CT Appearance from Birth to 2 Years of Age," presented at the annual conference of the American Society of Head and Neck Radiology, Los Angeles, Calif, April 25, 1996).

The age distribution of the subjects appears in the Table. The mean age was 11.6 months, the median was 13 months. Forty (66%) of the subjects were male and 21 (34%) female. The subjects were grouped in 2-month age intervals for the purpose of analysis. There was a minimum of three and maximum of eight subjects in each group.

## Measurements and Observations

*Anterior Skull Base Length.*—The length of the anterior skull base was measured on coronal images by multiplying the number of images from the nasoethmoidal junction to the sphenothmoidal recess by the section thickness. This would be expected to approximate the length of the cribriform plate.

*Ossification of the Skull Base.*—The extent of ossification of the anterior skull base was graded on each coronal image from the nasoethmoidal junction to the sphenothmoidal recess using a three-level system of not ossified, partially ossified, and completely ossified (Fig 2). A grade of not ossified signified that no ossification of the anterior skull base was present between the orbital plates of the frontal bones. When a complete, uninterrupted bony bridge was seen between the orbital plates of the frontal bones, complete ossification of the skull base was said to have occurred.

*Ossification of the Perpendicular Plate of the Ethmoid Bone.*—The vertical extent of ossification of the perpendicular plate of the ethmoid bone below the cribriform plate was measured on the coronal image at the level of the nerve-globe junction.

## Anterior skull base development in a population of 61 healthy subjects, newborn to 24 months old

Age, mo	No. in Group	Length, mm (SD)	Percentage Complete	Percentage Partial	PP, mm (SD)	Crista Galli, mm $\pm$ SD	Fovea Ethmoidalis, mm (SD)		
							Anterior	Middle	Posterior
0-1	4	19.5 (1.5)	0	33.9	0 (0)	0 (0)	0 (0)	0 (0)	0 (0)
2-3	6	20.0 (2.06)	16.1	88.0	0.3 (0.6)	8.8 (4.2)	0.2 (0.6)	0 (0)	0 (0)
4-5	6	23.6 (2.8)	40.6	96.5	1.4 (1.5)	10 (2.1)	0.4 (0.5)	0.4 (0.5)	0.1 (0.1)
6-7	5	22.2 (1.5)	52.9	100	2.4 (0.6)	13.5 (2.3)	1.8 (0.3)	0.4 (0.4)	0.1 (0.1)
8-9	4	23.6 (4.3)	59.4	98.2	3.8 (2.0)	13.0 (3.5)	2.0 (1.1)	1.6 (1.1)	0.2 (0.6)
10-11	4	27.4 (1.2)	67.4	98.6	3.1 (0.6)	17.3 (4.4)	2.5 (1.2)	1.4 (1.0)	0.6 (0.71)
12-13	3	24.2 (0.4)	69.1	100	3.2 (1.0)	15.0 (3.2)	2.3 (0.57)	1.6 (1.0)	0.2 (0)
14-15	7	25.5 (2.7)	75.8	100	4.7 (1.5)	16.1 (2.1)	2.2 (1.1)	2.2 (0.7)	0.5 (0.6)
16-17	6	26.3 (2.4)	73.2	99.0	4.8 (1.3)	16.5 (1.5)	1.9 (1.0)	1.4 (0.9)	0.6 (0.7)
18-19	8	26.3 (2.7)	78.8	100	4.5 (1.7)	17.0 (4.0)	3.2 (0.7)	2.6 (0.6)	0.8 (0.6)
20-21	5	27.9 (2.0)	84.0	100	4.0 (1.3)	18.3 (1.1)	3.6 (1.4)	2.8 (0.9)	0.5 (0.3)
22-24	3	31.0 (1.4)	83.9	100	4.7 (1.7)	17.4 (2.9)	3.4 (1.0)	2.7 (0.5)	1.0 (0.5)

Note.—PP indicates perpendicular plate of the ethmoid bone.

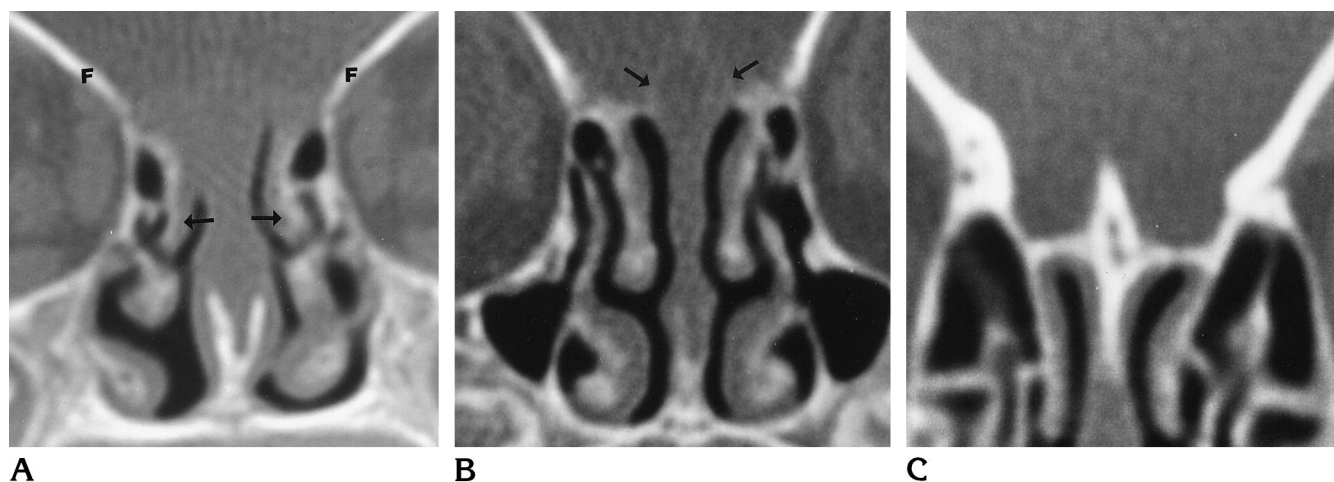


Fig 2. Grading ossification of the anterior skull base.

A, There is no ossification of the anterior skull base between the orbital plates of the frontal bones (F). The turbinates are ossified (arrows).

B, There is partial ossification of the anterior skull base between the orbital plates of the frontal bones, but gaps remain (arrows).

C, There is a complete bony bridge (complete ossification) between the orbital plates of the frontal bone.

*Ossification of the Crista Galli.*—The length of the crista galli was measured by counting the number of coronal images with either partial or complete ossification of the crista galli and multiplying by the section thickness.

*Development of the Fovea Ethmoidalis.*—The extension of ethmoidal air cells above the cribriform plate was measured on coronal images at three locations: the midglobe, the nerve-globe junction, and the posterior orbit.

## Results

### Ossification Pattern

At birth, the anterior skull base measured an average of 19.5 mm (range, 18 to 21 mm; SD, 1.50), and this increased to an average of 31.0 mm (range, 30 to 33 mm; SD, 1.4) in subjects

22 to 24 months of age (Table). Ossification of the anterior skull base was very limited in the newborn, but developed rapidly during the first 6 months. All subjects younger than 2 months old had areas of partial ossification, and none had complete ossification. By 4 months of age, nearly the entire anterior skull base showed at least partial ossification; at most, only one coronal image in each subject showed no ossification. At 6 months and older, 42 (93%) of 45 subjects had at least partial ossification on every coronal image through the anterior skull base. The earliest image with complete ossification was obtained at 2 months of age. The percentage of the anterior skull base that was

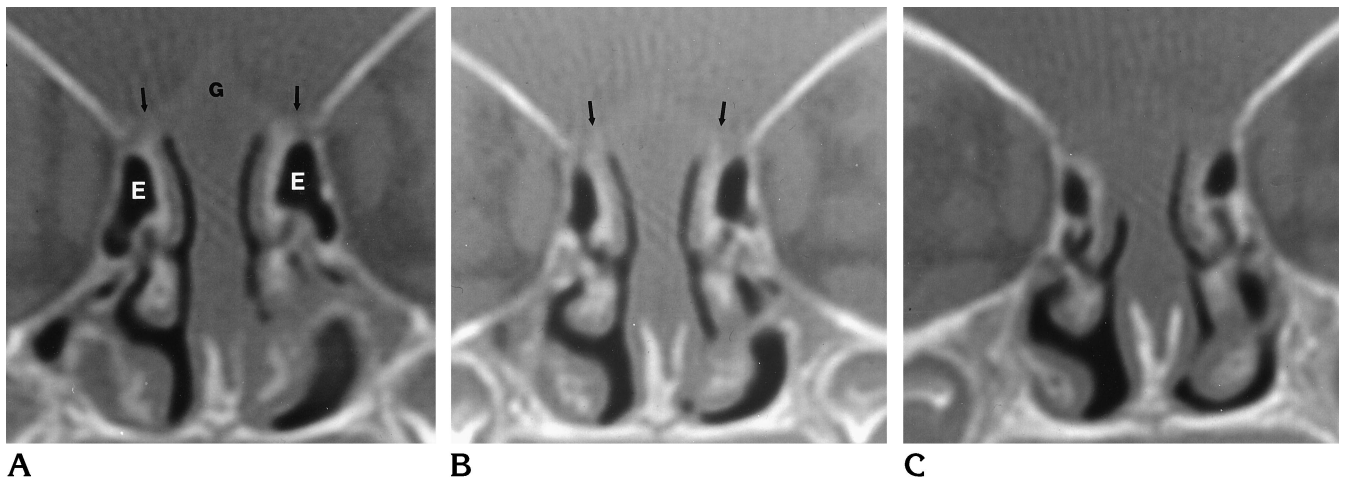


Fig 3. Ossification pattern of the anterior skull base at birth.

A-C, Coronal CT scans through the anterior, middle, and posterior portions of the anterior skull base, respectively. The anterior skull base has little ossification. The outline of the crista galli is just barely visible (*G*). There is very early ossification (*arrows*) of the roof of the ethmoidal labyrinth. Some ethmoidal air cells have formed (*E*), but they are below the plane of the cribriform plate. The orbital plates of the frontal bones extend to the lateral margin of the ethmoidal complex.

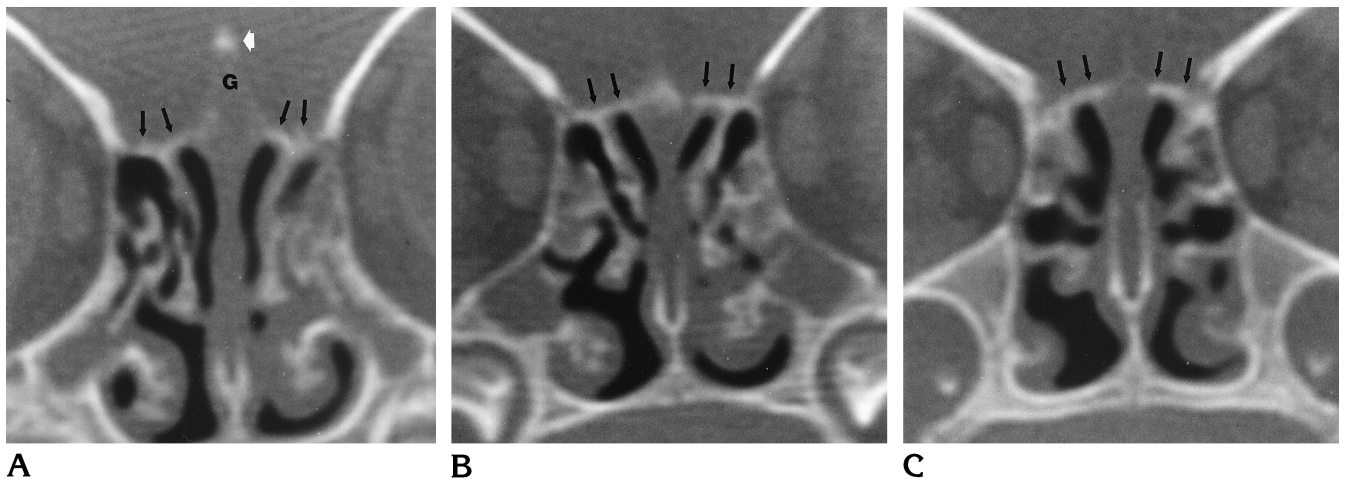


Fig 4. Ossification pattern of the anterior skull base at 3 months.

A-C, Coronal CT scans through the anterior, middle, and posterior portions of the anterior skull base, respectively. Ossification of the anterior skull base has progressed significantly. The roof of the ethmoidal complex is largely ossified (*black arrows*) and the ossification extends across the roof of the nasal cavity. The tip of the crista galli (*G*) is ossified (*white arrow*). At the plane of the nerve-globe junction (*B*), ossification of the crista galli is most advanced. The ethmoidal air cells are better developed, but still below the plane of the cribriform plate.

completely ossified steadily increased over the first 2 years of life, with 84% of the skull base completely ossified by 2 years of age (Table).

The pattern of ossification of the anterior skull base is depicted in Figures 3 through 8. At birth (Fig 3), the frontal bones were well ossified and extended to the medial edge of the orbit. Ossification of the cribriform plate began in the region of the vertical attachments of the superior and middle turbinates and spread along the surface of the cribriform plate to reach the crista

galli at approximately 2 months of age. A separate ossification center at the tip of the crista galli was identified in two of four subjects at 3 months of age (Fig 4), but at no other age. Ossification was generally most advanced on coronal images in the region of the nerve-globe junction and, from this central portion of the cribriform plate, proceeded in both an anterior and posterior direction. Complete ossification to the posterior margin of the cribriform plate was seen as early as 7 months of age in one subject.

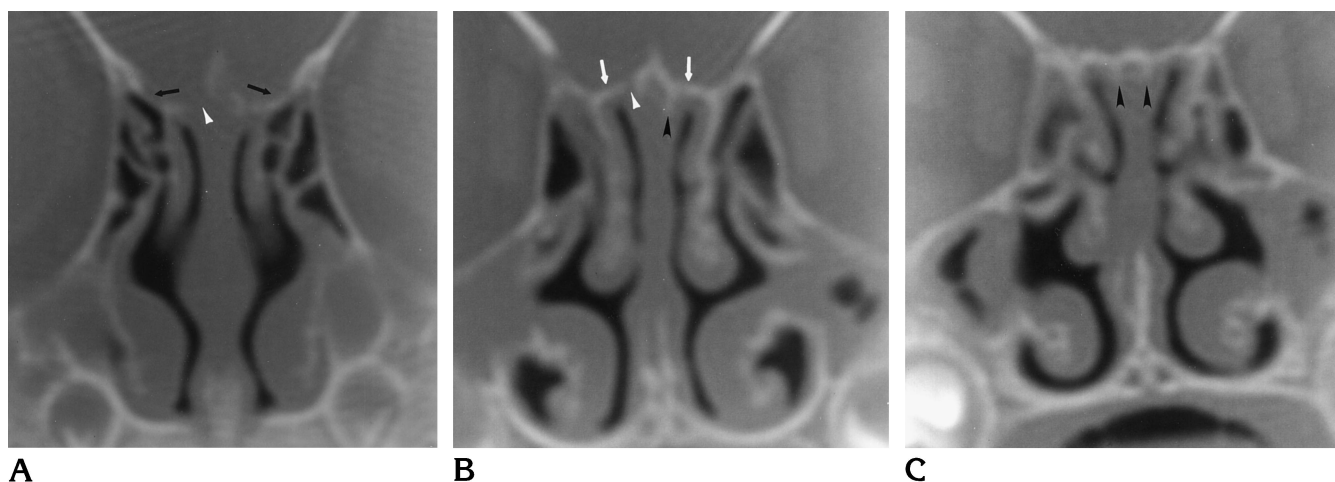


Fig 5. Ossification pattern of the anterior skull base at 7 months.

A–C, Coronal CT scans through the anterior, middle, and posterior portions of the anterior skull base, respectively. Ossification of the anterior skull base continues to progress. Anteriorly, gaps in ossification of the midline structures remain (*white arrowhead*). The ethmoidal air cells now begin to project above the plane of the cribriform plate (*black arrows*). The roof of the nasal cavity is well ossified (*white arrows*). The perpendicular plate of the ethmoid bone has begun to ossify (*black arrowheads*).

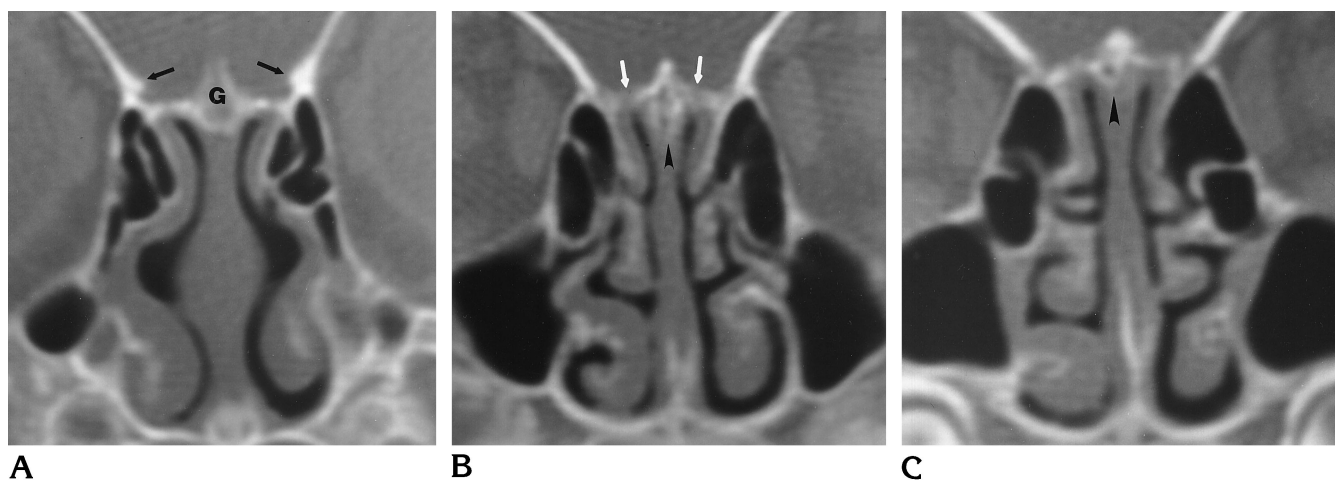


Fig 6. Ossification pattern of the anterior skull base at 13 months.

A–C, Coronal CT scans through the anterior, middle, and posterior portions of the anterior skull base, respectively. The crista galli (G) is well ossified. The orbital plates of the frontal bones extend over the lateral ethmoidal air cells, beginning to form the fovea ethmoidalis (*black arrows*). The perpendicular plate of the ethmoid bone continues to ossify (*arrowheads*). Small gaps in ossification between the crista galli and ethmoid bone can still be seen (*white arrows*).

In subjects over 12 months of age, 22 (71%) of 31 had complete ossification to the posterior cribriform plate. Anteriorly, a gap persisted between the ethmoid and nasal bones in most subjects through 24 months of age. Only five (8%) of the 61 subjects studied had complete ossification anteriorly to the margin of the cribriform plate, the earliest at 14 months of age. In those subjects over 18 months of age, three (25%) of 12 had complete ossification anteriorly, and of the five who had complete anterior

ossification, four (80%) also had complete posterior ossification.

#### *Perpendicular Plate of the Ethmoid Bone and Crista Galli*

Ossification of the crista galli began in all subjects between 1 and 2 months of age. There was a rapid increase in length of ossification of the crista galli to 14 months of age, when the average ossified length was 16.1 mm (range, 12

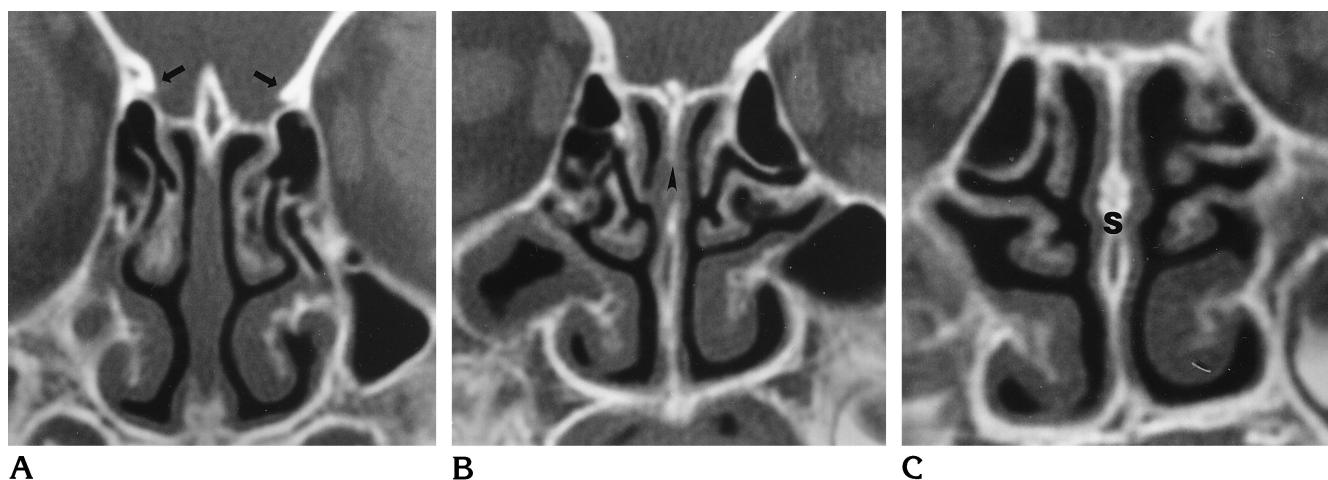


Fig 7. Ossification pattern of the anterior skull base at 19 months.

A-C, Coronal CT scans through the anterior, middle, and posterior portions of the anterior skull base, respectively. Nearly the entire anterior skull base is ossified. The fovea ethmoidalis is further developed (*arrows*). The perpendicular plate of the ethmoid bone is well ossified (*arrowhead*) and meets the ossified vomer in the posterior septum (*S*).

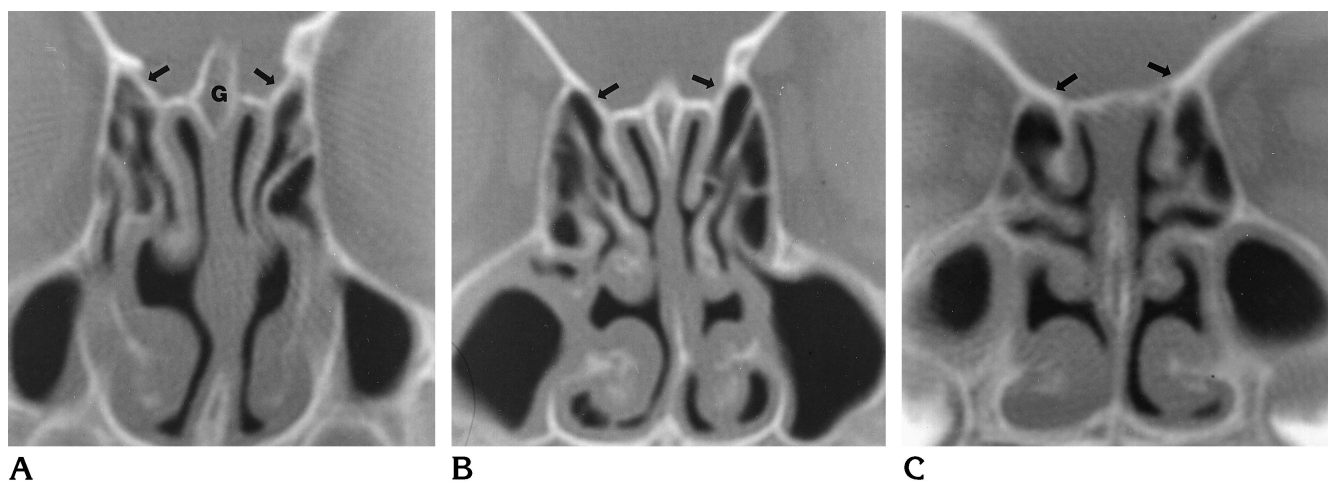


Fig 8. Ossification pattern of the anterior skull base at 24 months.

A-C, Coronal CT scans through the anterior, middle, and posterior portions of the anterior skull base, respectively. The anterior skull base appears more mature. The crista galli (*G*) is completely ossified and has fused with the ethmoidal labyrinths. Ethmoidal air cells extend above the plane of the cribriform plate, even posteriorly (*arrows*). Even at this age, gaps in the midline anterior to the crista galli are normal.

to 18 mm; SD, 2.1) (Table). Only slight further ossification occurred after 14 months, with subjects aged 22 to 24 months having a crista galli that averaged 17.4 mm (range, 13.5 to 20.5 mm; SD, 2.9).

Ossification of the perpendicular plate of the ethmoid bone approximately paralleled that of the crista galli (Table). The perpendicular plate of the ethmoid bone was also unossified at birth. Ossification began as early as 2 months of age, and by 5 months of age, all subjects had some evidence of ossification of the perpendicular plate. Ossification progressed rapidly to ap-

proximately 14 months of age, averaging 4.7 mm (range, 3.5 to 7.5 mm; SD, 1.5). There was essentially no further ossification to 24 months, with average ossification of 4.7 mm (range, 3 to 7 mm; SD, 1.7).

#### *Fovea Ethmoidalis*

The fovea ethmoidalis forms as the ethmoidal air cells begin to extend above the plane of the cribriform plate. There was no extension of ethmoidal air cells above the cribriform plate in subjects 2 months of age and younger. By 6

months, all subjects studied showed extension of ethmoidal air cells above the cribriform plate. Of the 51 subjects in our series with extension of the ethmoid bone above the cribriform plate, 42 (82%) were most developed in the anterior portion, eight (16%) were most developed in the middle portion, none (0%) were most developed in the posterior ethmoid, and one (2%) showed equal development of the anterior and middle ethmoid bone. All subjects 6 months of age and older showed anterior ethmoid bone extension above the cribriform plate. All subjects except one had middle ethmoid bone extension by 8 months of age (one subject did not have extension on one side at 17 months of age); posterior ethmoid bone extension was not a constant finding until 18 months of age and older (Table).

## Discussion

Radiologists are infrequently asked to image the anterior skull base in neonates. It is important to understand the appearance of the developing anterior skull base to avoid interpretive errors in this complex region. Prior anatomic studies have described the embryologic and fetal development of the anterior skull base in detail, but few studies have detailed the postnatal development of the anterior skull base as evaluated on CT scans in infants and young children (3, 10).

Our results demonstrate that the ethmoidal labyrinth and turbinates (derived from the primitive nasal capsule) serve as the nidus for ossification of the anterior skull base. Ossification proceeds from this area toward the midline over the first few months of life, accounting for the midline gaps normally seen on coronal CT scans. As a child matures, ossification of the anterior skull base proceeds in a fairly constant pattern, with fusion of the cribriform plate and lateral ethmoid bone masses beginning as early as 2 months of age. This is earlier than the 3 to 6 years suggested in anatomic studies (1, 11, 12).

Our observations also show that ossification of the paired ethmoidal labyrinths spreads to the crista galli and perpendicular plate rather than the opposite pattern of ossification suggested by Ford (7).

Ford (7) reported that in the first year after birth the mesethmoidal center appears in the septum and extends to ossify the crista galli and

posterior half of the nasal septum, and then spreads across the roof of the nasal cavity to unite with the ethmoidal labyrinths. His measurements on 19 skulls under 2 years of age are in good agreement with our findings. His direct measurements of the cribriform plate in 11 infant skulls 0 to 6 months of age showed an average length of 20.8 mm; this figure is confirmed in our 18 subjects in that age range, in whom the cribriform length averaged 21.2 mm. In the skulls of eight infants aged 7 to 24 months, Ford found the average length of the cribriform plate to be 24.5 mm, again agreeing with our measurements in 43 infants showing an average cribriform length of 26.2 mm. Ford also noted that the mesethmoidal center unites with the ethmoidal labyrinths as early as 1 year of age (7). This is supported by our observations of a complete bony union between the crista galli and ethmoidal labyrinths as early as 2 months.

Nadich et al (3) conducted a large study of the use of CT to examine the anterior skull base in this age group, although the full results of that study were not published. Our results agree with most of their reported observations and further refine some of the details. Whereas that study reported ossification of the perpendicular plate to occur after 5 months, it is clear from our data that ossification occurs as early as 2 months. Nadich reports 14% of subjects under 1 year to have "no midline ossification of the anterior fossa or septum. . ." (3) whereas our study shows that essentially all subjects aged 2 months and older have at least early ossification of the crista galli, and that osseous bridging of the ethmoidal complex to the cribriform plate and crista galli may occur as early as 2 months. These discrepancies may be explained by differences in technique. Our study relies solely on direct coronal sections, 3 mm or thinner, to judge ossification of the anterior skull base.

Van Loosen et al (10) looked at 16 fetuses 18 through 32 weeks of age and three children 1, 2, and 6 years of age, respectively. The results of his analysis of the fetuses showed cartilage in the anterior midline, as would be expected. The 1- and 2-year-old infants both had cartilage persistent in the midline, but the 6-year-old did not, leading the author to conclude that ossification of the lamina cribrosa occurs between 2 and 6 years of age (10). Our study shows that although portions of the anterior skull base may be cartilaginous at 2 years of age, the majority



of the cribriform plate would be expected to be ossified by that age.

The information supplied by this study is of value for one main reason: the cartilage of the skull base is of similar attenuation to surrounding soft-tissue structures on CT scans, giving the appearance of a gap in the anterior skull base, and this normal appearance can make exclusion of an anterior encephalocele or other lesion involving the anterior skull base difficult. In cases in which a visible craniofacial mass suggests an encephalocele, CT findings may be equivocal in this age range. Moreover, since nasal dermoids may track intracranially, either anterior to the crista galli (via the foramen cecum) or posterior to it, the lack of ossification in this region can make it difficult to exclude an intracranial extension of these developmental lesions. Subjects with craniofacial anomalies and no obvious facial or sinonasal mass may have occult dermoid or epidermoid tumors or a meningoencephalocele; in these patients, such an associated finding must be excluded with a high degree of confidence before the craniofacial deformities can be corrected. Because of the potential fallibility of CT related to the normal developmental variants described in this article, magnetic resonance (MR) imaging has replaced CT as the primary means of examining such patients at our institution. MR imaging is also more definitive for detecting other anomalies of the central nervous system that may be associated with craniofacial malformations. The potentially more informative MR study may also be useful in genetic counseling. CT is now held in reserve for patients in whom skeletal data are necessary to plan repair, or when MR findings are not definitive. Perhaps a combination of CT and MR imaging will become the means for completely evaluating the more complex of these craniofacial anomalies. Optimally, a

study of this region should be done with sections no thicker than 3 mm (with CT or MR imaging) in at least two orthogonal planes. Our MR protocol includes surface-coil imaging of the anterior skull base with survey, standard head-coil imaging of the remainder of the brain.

### Acknowledgment

We acknowledge the assistance of Suresh Mukherji during the initial planning stages of this project.

### References

1. Scott JH. The cartilage of the nasal septum (a contribution to the study of facial growth). *Br Dent J* 1953;95:37-43
2. Moore KL. The skeletal system. In: *The Developing Human: Clinically Oriented Embryology*. 4th ed. Philadelphia, Pa: Saunders; 1988:340-343
3. Nadich TP, Zimmerman RA, Bilaniuk LT. Midface: embryology and congenital lesions. In: Som PM, Curtin HD, eds. *Head and Neck Imaging*. 3rd ed. St Louis, Mo: Mosby-Year Book; 1996: 17-22
4. Bosma JF. Introduction to the symposium on development of the basicranium. In: *Symposium on the Development of the Basicranium*. US Dept of Health, Education, and Welfare publication 76-989. Bethesda, Md: Public Health Service, National Institute of Health; 1976:3-28
5. Sperber GH. The cranial base. In: *Craniofacial Embryology*. 2nd ed. Dorchester, England: Wright; 1976:78-87
6. Hamilton WJ, Mossman HW. Skeletal system. In: *Human Embryology*. Baltimore, Md: Williams & Wilkins; 1972:532-540
7. Ford EHR. Growth of the human cranial base. *Am J Orthodont* 1958;44:498-506
8. Fairbanks DNF. Embryology and anatomy. In: Bluestone CD, Stool SE, Scheetz MD, eds. *Pediatric Otolaryngology*. 2nd ed. Philadelphia, Pa: Saunders; 1990:605-631
9. Schaeffer JP. The clinical anatomy and development of the paranasal sinuses. *Pa Med* 1936;39:395-404
10. Van Loosen J, Klooswijk AIJ, van Velzen D, Verwoerd CDA. Computed tomography of the human developing anterior skull base. *Eur J Radiol* 1990;10:211-214
11. Scott JH. Growth at facial sutures. *Am J Orthodont* 1956;42:381-387
12. Schaeffer JP. General embryology and development. In: *Nose, Paranasal Sinuses, Nasolacrimal Passageways, and Olfactory Organ in Man*. Philadelphia, Pa: Blakinston's Son; 1920:40-41