

Are your **MRI contrast agents** cost-effective?

Learn more about generic **Gadolinium-Based Contrast Agents**.



**FRESENIUS
KABI**

caring for life

AJNR

Magnetization transfer study of HIV encephalitis and progressive multifocal leukoencephalopathy. Groupe d'Epidémiologie Clinique du SIDA en Aquitaine.

This information is current as of April 19, 2024.

V Dousset, J P Armand, D Lacoste, S Mièze, L Letenneur, J F Dartigues and J M Caill

AJNR Am J Neuroradiol 1997, 18 (5) 895-901
<http://www.ajnr.org/content/18/5/895>

Magnetization Transfer Study of HIV Encephalitis and Progressive Multifocal Leukoencephalopathy

Vincent Dousset, Jean-Pierre Armand, Denis Lacoste, Stéphane Mièze, Luc Letenneur, Jean-François Dartigues, Jean-Marie Caillé, and the Groupe d'Epidémiologie Clinique du SIDA en Aquitaine

PURPOSE: To ascertain whether the use of magnetization transfer (MT) in MR imaging can characterize tissue destruction in human immunodeficiency virus (HIV)-positive patients with presumed progressive multifocal leukoencephalopathy (PML) or HIV encephalitis. **METHODS:** Brain MR studies that included MT were obtained in three groups: 11 healthy control subjects, 10 HIV-positive patients with clinical and radiologic findings of PML, and 13 HIV-positive patients with HIV encephalitis. MT ratios (MTRs) were calculated in PML and HIV encephalitis lesions and in normal-appearing white matter in the patients and control subjects. **RESULTS:** PML lesions revealed a dramatic decrease in MTR ($22\% \pm 2.3$). HIV encephalitis lesions had statistically significantly higher MTR values ($40\% \pm 3.8$) than PML lesions. The MTR of normal-appearing white matter was significantly higher in the control subjects ($47\% \pm 2.3$) than in the PML group ($46\% \pm 3.3$) or the HIV encephalitis group ($44\% \pm 2.6$). **CONCLUSION:** MTR determinations suggest the possibility of distinguishing PML from HIV encephalitis and of indicating whether HIV encephalitis is involved in white matter that appears normal on conventional MR images.

Index terms: Magnetic resonance, magnetization transfer; Encephalitis; Brain, diseases; Acquired immunodeficiency syndrome (AIDS)

AJNR Am J Neuroradiol 18:895-901, May 1997

Among magnetic resonance (MR) imaging techniques that have been proposed to improve in vivo tissue characterization, magnetization transfer (MT) has appeared to be particularly sensitive to tissue destruction. MT effects are due to dipole-dipole interactions between water protons and protons at the surface of macromolecules (1). Proteins or lipids in cell membranes are the molecules that probably participate in this exchange (2). In normal white matter, the exchange rate of MT is high (1, 3, 4),

whereas in experimentally induced lesions of the central nervous system and in multiple sclerosis lesions, the decrease in the lesion MT ratio (MTR) was found to be proportional to the degree of macromolecular destruction (myelin and axonal loss) (4-9). Furthermore, the MTR of multiple sclerosis lesions and normal-appearing white matter of patients seem to correlate with the clinical disability score (4, 6, 7, 10). The aim of this work was to evaluate the ability of MT to differentiate a pure demyelinating process, progressive multifocal leukoencephalopathy (PML), from a much less destructive disease, human immunodeficiency virus (HIV) encephalitis. We also investigated the normal-appearing white matter of HIV-positive patients with or without PML in order to determine whether there is a widespread diffusion of HIV infection in the central nervous system.

Subjects and Methods

Imaging was performed with a 1.5-T MR unit and a transmit-receive head coil. The MT imaging sequence was

Received June 22, 1996; accepted after revision November 14.

Presented at the annual meetings of the American Society of Neuroradiology, Seattle, Wash, June 1996, and the Society of Magnetic Resonance, Nice, France, August 1995.

From the Service de Neuroradiologie, Hôpital Pellegrin-Tripode (V.D., J.-P.A., S.M., J.-M.C.), CHU de Bordeaux (D.L., G.E.C.S.A.), and the Département d'Epidémiologie et Statistique Médicale, INSERM U330, Université de Bordeaux II (L.L., J.-F.D.), Bordeaux, France.

Address reprint requests to Vincent Dousset, MD, Service de Neuroradiologie, Hôpital Pellegrin-Tripode, 33076 Bordeaux, France.

AJNR 18:895-901, May 1997 0195-6108/97/1805-0895

© American Society of Neuroradiology

performed using the pulsed saturation method (11). Images were acquired with a gradient-echo sequence with parameters of 600/12/2 (repetition time/echo time/excitations) and a 60° flip angle. An off-resonance pulse was applied before each excitation in order to achieve MT by saturating the macromolecular matrix in the steady state. The frequency off-set was established at 1.5 kHz below the water frequency, the duration of the gaussian pulse was 8.192 milliseconds and the power was 15.5×10^{-6} T. A reference image was also obtained with the amplitude of the off-resonance pulse set at zero. Both the reference image and the image with the MT saturation pulse were obtained with the gain and image scale maintained constant. An MTR was calculated for a given region of interest (ROI) using the equation

$$\text{MTR} = (1 - M_s/M_o) \times 100$$

where M_s is the ROI measurement on the saturation image and M_o is the ROI measurement on the unsaturated image (4). For seeing MTR directly pixel by pixel, the two sets of images were transferred to a workstation where a home-made application made it possible to calculate an MTR map with a color-encoding scale of 10% from cold colors (black, 0% to 10%; purple, 11% to 21%) to hot colors (yellow, 22% to 32%; orange, 33% to 43%; red, 44% to 54%).

Other conventional imaging acquisitions included a T2-weighted spin-echo sequence (2500/22-90/1) and a T1-weighted spin-echo sequence (500/22/2) after intravenous injection of 0.1 mmol/kg gadopentetate dimeglumine. For each of the sequences, the section orientation was axial and the section thickness was 5 mm, with a gap between sections of 1 mm. The overall duration of the examination was 17 minutes.

HIV-positive patients included in this study were selected by physicians who specialize in infectious diseases. For the purpose of the study, diagnosis of HIV encephalitis and PML were based on the following criteria. For group 1 (HIV encephalitis), criteria were cognitive impairment (without any other concurrent brain infection) associated with atrophy and deep symmetric white matter hyperintensities on MR images. For group 2 (PML), criteria were a focal neurologic deficit that slowly worsened over several weeks (without any other concurrent brain infection), positive polymerase chain reaction for JC papovavirus within the cerebrospinal fluid, and focal subcortical hyperintensity, of which the location on the MR studies correlated with the clinical deficit. If one of the criteria was missing, PML diagnosis was confirmed by histologic examination after cerebral biopsy. Healthy volunteers (group 3) constituted the control group. They were neither high-risk people for HIV infection nor had a history of any neurologic disease, and their MR studies appeared normal. In this group, the postcontrast sequence was not performed.

According to the criteria described above, groups were composed as follows: group 1 included 13 HIV-positive patients (mean age, 36 ± 8 years) with presumed HIV encephalitis; group 2 included 10 HIV-positive patients (mean age, 39 ± 14 years) with presumed PML; and group 3 comprised 11 healthy volunteers (mean age, 35 ± 14 years).

Imaging Analysis

Sites of HIV encephalitis and PML lesions were identified on T2-weighted images by two trained neuroradiologists. The HIV encephalitis was seen as diffuse bilateral and symmetric high signal intensity located in the periventricular areas and as focal subcortical high signal intensity for PML lesions. On contrast-enhanced T1-weighted images, there was an absence of enhancement in these lesions. None of the patients with PML lesions had evidence of HIV encephalitis, and vice versa. For both HIV encephalitis and PML lesions, two MTR values were calculated and averaged at the sites of hyperintense white matter signal (Figs 1 and 2). MTR values were compared by using a Mann-Whitney nonparametric test with type 1 error risk $\alpha = .05$ to assess significant differences.

In the control group, mean MTR values of normal white matter were calculated from nine ROIs in the pons, centrum semiovale, internal capsule, and frontal and occipital white matter (Fig 3). Each ROI included 32 pixels. The mean MTR of lesion-free normal-appearing white matter was calculated for each of the patients from groups 1 and 2 by using the same protocol as for group 3. MTR values of the normal-appearing white matter of the three groups were compared by using the Kruskal-Wallis analysis of variance.

Results

All HIV-positive patients with HIV encephalitis had cognitive dysfunction and deep white matter hyperintensities on MR images (Table 1). The clinical, biological, and imaging features of HIV-positive patients with PML are summarized in Table 2. In one patient, PML was confirmed histologically, although clinical and MR images were highly suggestive of PML. The typical MR characteristics of HIV encephalitis and PML lesions are displayed in Figures 1 and 2, respectively.

The mean MTR value of hyperintensities in the deep white matter in HIV encephalitis was $40\% \pm 3.8\%$ (mean \pm standard deviation). The highest MTR value of an HIV encephalitis lesion was 45% (patient 9, group 1). The lowest value found was 36% (patient 8, group 1). For PML lesions, the mean MTR value was $22\% \pm 2.3\%$. Highest and lowest MTR values in PML lesions were, respectively, 29% (patient 2, group 2) and 14% (patient 7, group 2). The difference between the MTR of HIV and PML lesions was significant, with $P = .0001$. Figure 4 shows color-encoding MTR maps in both HIV encephalitis and PML lesions.

The mean MTR value of the normal-appearing white matter from group 3 (healthy volun-

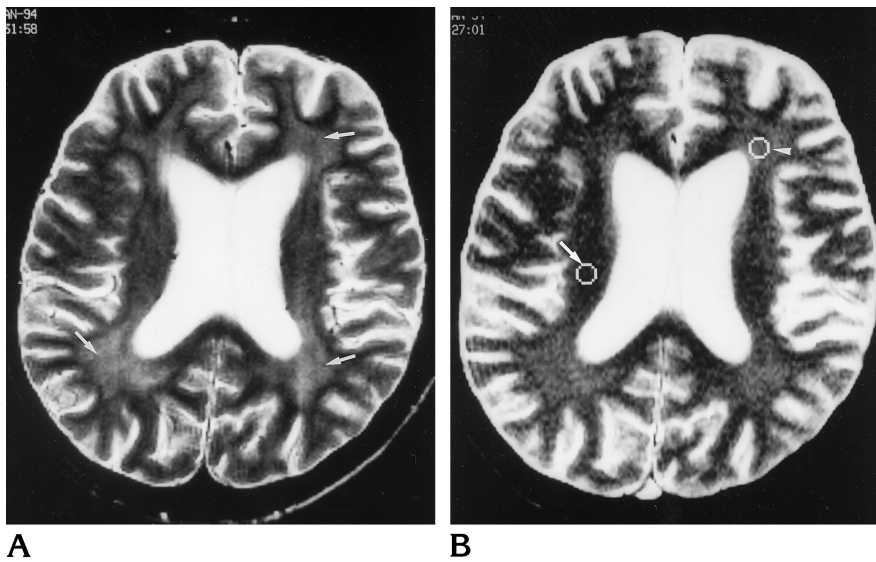


Fig 1. HIV encephalitis (patient 4).

A, T2-weighted image shows deep white matter hyperintensity in the periventricular areas (*arrows*).

B, Magnetization transfer image with cursors indicating ROI in one lesion site (*arrowhead*) and normal-appearing white matter (*arrow*).

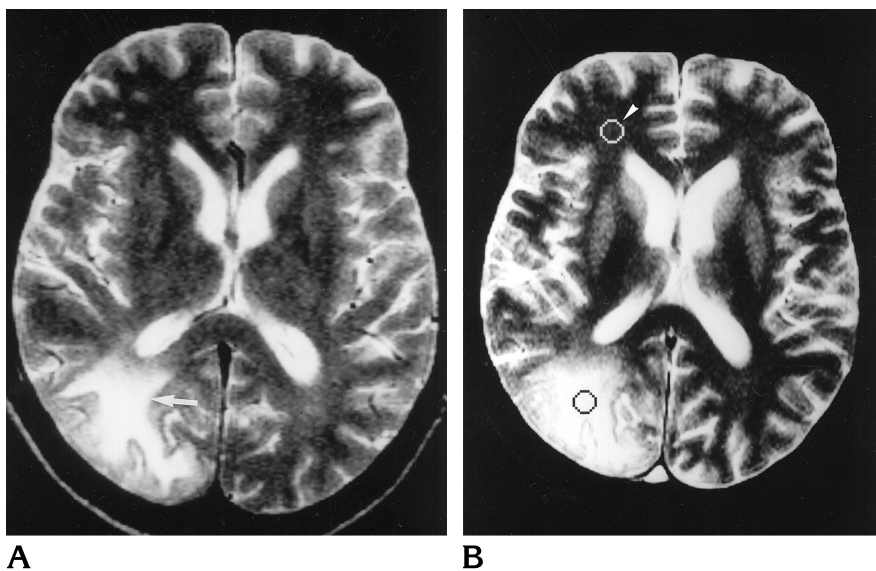


Fig 2. PML (patient 8).

A T2-weighted image shows a parietooccipital lesion attributed to PML (*arrow*).

B, Magnetization transfer image with one cursor at the lesion site and one cursor in normal-appearing white matter (*arrowhead*).

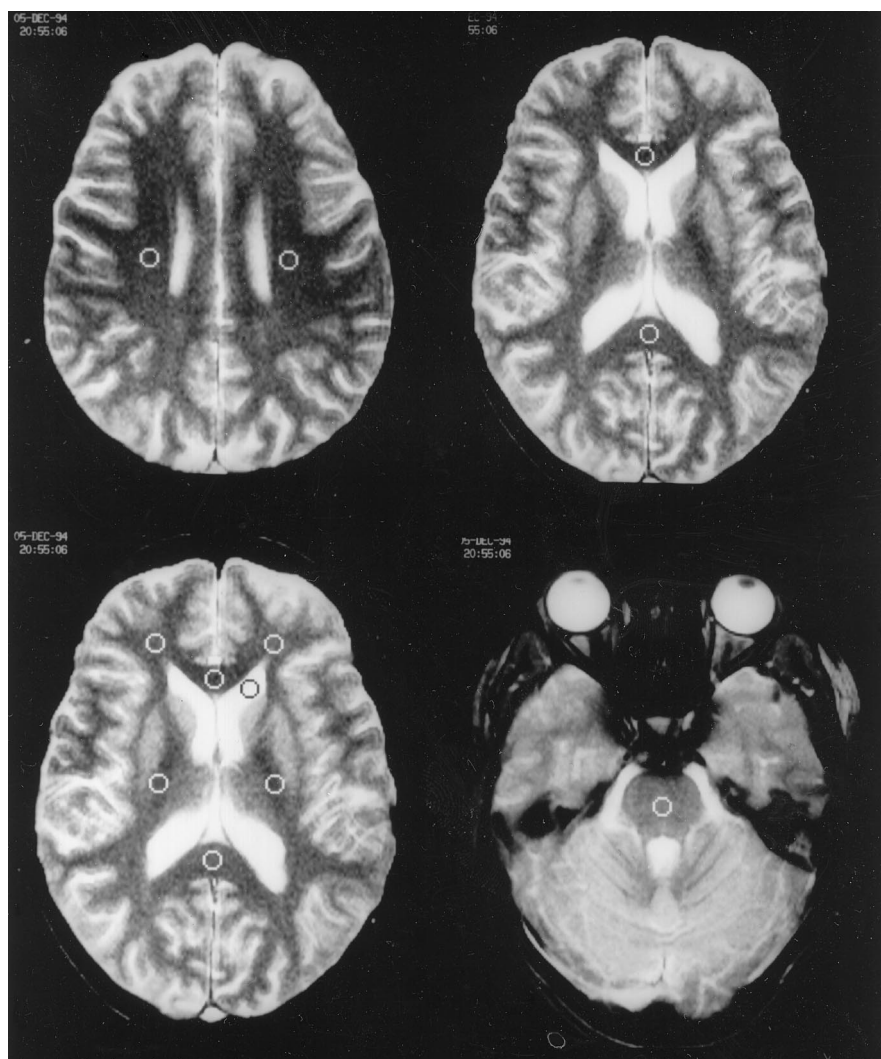
teers, 99 sites) was $47\% \pm 2.3\%$. For group 1, the mean MTR value of normal-appearing white matter averaged from 110 sites, because seven sites were involved by HIV encephalitis, was $44\% \pm 2.6\%$. For group 2, the mean MTR value calculated in 82 sites, eight sites being involved by PML, was $46\% \pm 3.3\%$. Statistical analysis with Kruskal-Wallis analysis of variance revealed a difference between the three groups, with $P = .009$.

Discussion

The imaging features of HIV encephalitis and PML lesions in HIV-positive patients have been

described extensively (12–16). Usually, such lesions are detected by MR imaging and do not require histologic confirmation by cerebral biopsy (16). Nevertheless, there are cases of atypical presentation and, in addition, superimposed disease processes are frequently present in infected patients. In our series, we obtained pathologic proof in only one patient with PML; however, in both groups, the clinical and imaging features of these diseases were typical. For the purpose of this study, we ensured the diagnosis of PML with a polymerase chain reaction test for the JC virus either in the cerebrospinal fluid or in blood. All patients from group 2 died of PML, whereas four patients in group 1 died of

Fig 3. Magnetization transfer images in healthy volunteer. Cursors indicate the ROIs for MTR measurement in the normal-appearing white matter.



cachexia or nonneurologic infections. Differentiating between PML and HIV encephalitis is critical because the prognosis is much better for the latter and there is the possibility of reversal of neurologic dysfunction with the use of zidovudine. In PML, on the other hand, there is no treatment and death usually occurs within 6 months.

The pathogenesis of PML and HIV encephalitis is very distinct. PML, which has a prevalence of 4% among patients with the acquired immunodeficiency syndrome (AIDS), is due to an opportunistic agent, JC papovavirus, that grows in oligodendrocytes. The virus destroys oligodendroglial cells and therefore the myelin sheaths. Demyelination develops first at the junction of the cortex and white matter and, in most cases, in the posterior areas of the brain, in the parietal, occipital, and cerebellar lobes

TABLE 1: Magnetization transfer ratio (MTR) values for sites of HIV encephalitis lesions and normal-appearing white matter in 13 HIV-positive patients (group 1)

Patient	Sex/Age, y	MTR Values, %	
		HIV Encephalitis Lesions	Normal-Appearing White Matter
1	F/52	43	45
2	M/35	40	45
3	M/40	39	42
4	F/32	41	46
5	F/31	41	43
6	F/26	39	42
7	M/30	40	43
8	M/47	36	43
9	M/31	45	47
10	F/39	40	46
11	F/47	38	42
12	M/26	39	44
13	M/37	43	46

TABLE 2: Clinical and imaging features and magnetization transfer ratio (MTR) values for sites of HIV encephalitis and normal-appearing white matter in 10 progressive multifocal leukoencephalopathy (PML) (group 2)

Patient	Sex/Age, y	Neurologic Deficit	CSF JC Virus PCR*	PML Lesion Site	MTR Values, %	
					PML Lesions	Normal-Appearing White Matter
1	F/34	R hemiparesia	+	L frontal parietal	17	48
2	M/50	L hemiparesia L hemianopsia	+	R parietal occipital	28	48
3	M/61	R hemiparesia	+	L frontal parietal	25	44
4	M/34	L hemianopsia Sensitive disturbance	+	R occipital	23	41
5	M/30	Gait disturbance Sensitive disturbance	+	L parietal	18	44
6	M/30	R hemiparesia Sensitive disturbance	+	L parietal occipital	29	44
7	M/24	Ataxia Sensitive disturbance	+	Cerebellum	14	48
8	M/63	L hemianopsia	+	R parietal occipital	22	48
9	M/32 [†]	L hemiparesia	-	R frontal parietal	22	44
10	M/31	R hemianopsia	+	L occipital temporal	26	47

* Polymerase chain reaction for JC papovavirus within the cerebrospinal fluid.

[†] Patient with biopsy-proved PML.

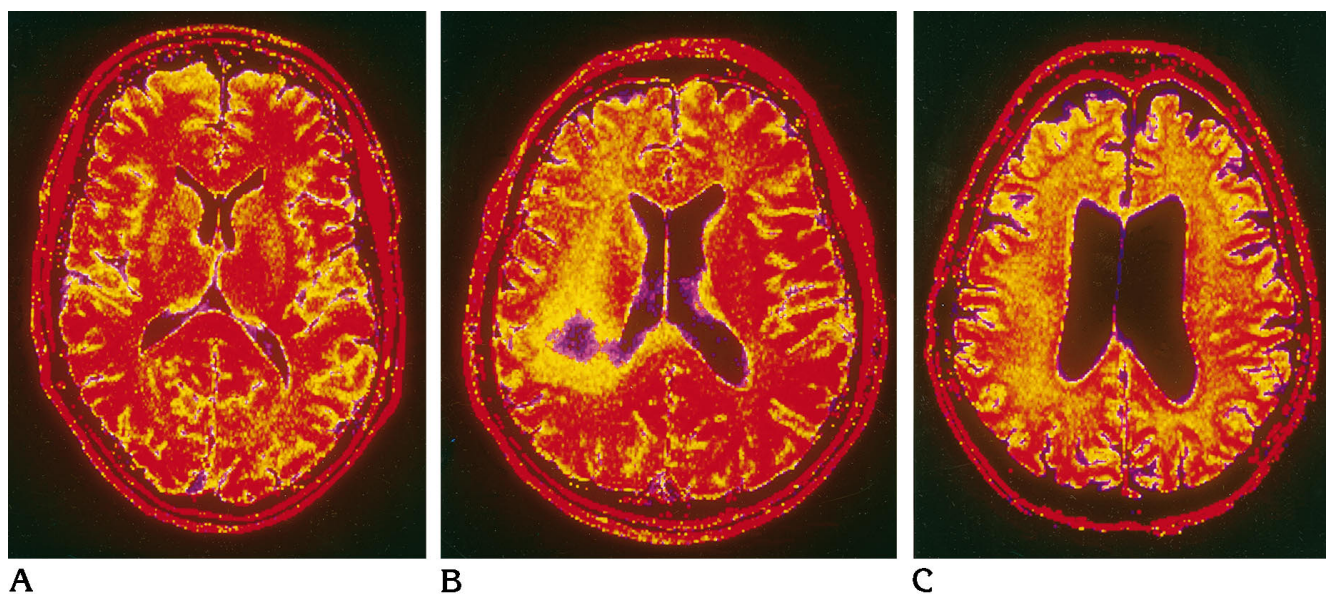


Fig 4. Color-encoded MTR maps.

A, In a healthy volunteer, a majority of red spots within the white matter indicates MTR values of over 44%.

B, In patient 9, with a biopsy-proved PML lesion in the right parietal lobe, cold colors indicate low MTR within the core of the demyelinating process.

C, In patient 10, with HIV encephalitis, diffuse abnormality is seen as orange spots within the white matter, an indicator of a much less destructive process than that in patient 9 (Fig 4B).

(17). An inflammatory reaction is usually absent or minimal, which explains the absence of mass effect or edema on both pathologic examinations and MR studies. There is no enhancement on postcontrast images in most cases, but 5% to 10% may show enhancement at the margins of the lesion. In this demyelinating process, we found MTRs to be very low (22%). This dramatic decrease in the MT effects in comparison with those found in the white matter of volunteers (47%) confirmed the specificity of MT in characterizing the destructive process that occurs in central nervous system demyelinating diseases.

Brain involvement by HIV occurs in 90% of HIV-infected patients, as proved by pathologic examination. The pathogenesis of HIV encephalitis is still obscure (18). The transport of HIV into the brain is mediated by cells belonging to the monocyte/macrophage system. Although HIV has the ability to cause neurologic disease, the virus does not replicate within neural or glial cells (19). The AIDS dementia complex, which occurs in 15% of HIV patients, may be due to damage of the blood-brain barrier, to cytokines produced from macrophages, and/or to the HIV-1 gp120 coat protein that has the potential to diffuse and interact with distant uninfected brain cells (20–22). Two major consequences of HIV migration to the brain can be seen with MR imaging. First, there may be atrophy of brain parenchyma, which is due to neuronal death; second, alterations of deep white matter usually in the periventricular regions can have high signal intensity on conventional T2-weighted images. Myelin destruction is not usual, and the abnormal signal intensity found on T2-weighted images in these regions may be due to an increase in water content, although other observations have shown that myelin destruction may occur and lead to HIV leukoencephalopathy (19, 23).

Post et al (14) showed that there is not a good correlation between the findings on conventional MR images and the clinical status. The slight decrease in MTR values (40%) in the areas of hyperintense white matter attributed to HIV encephalitis, in comparison with normal white matter MTR values from healthy volunteers (47%), is consistent with an absence of or with discrete tissue destruction at pathologic examination. A small decrease in the MTR (2% to 4%) has been observed in purely edematous lesions of experimental allergic encephalomy-

elitis (4), whereas a decrease of about 10% to 12% has been observed in experimental toxic demyelination. Since the MTR of HIV encephalitis lesions varied from the lowest (36%) to the highest (45%) values, there might be a wide spectrum of tissue damage, from only edematous changes to moderate tissue destruction, including myelin and axon membranes, the latter representing the ultimate stage of leukoencephalopathy due to HIV (23). Broderick et al (15) hypothesized that severe grades of white matter abnormality may be seen in patients with AIDS dementia complex, although deep white matter did not differ significantly between patients with or without dementia. According to our results, MTR may distinguish between severe and discrete white matter involvement by HIV encephalitis. Thus, further work should investigate MTR values relative to clinical status of patients, especially mental status. The effect of treatment, such as zidovudine on HIV encephalitis, may also be assessed by using MT (24). MT could provide an *in vivo* characterization of HIV encephalitis and may play a key role in the future understanding of a pathogenesis that so far is unclear.

Another finding of this work is the decrease of MTR values of normal-appearing white matter in HIV-positive patients, including those with HIV encephalitis and those with PML. The decrease in both groups relative to the white matter of healthy volunteers was found to be statistically significant, although the difference in averaged MTR values was only about 1% to 2%. This finding may be the result of global brain involvement because of diffuse HIV encephalitis throughout the brain, including regions that appear normal on conventional MR images. An identical finding has been observed in normal-appearing white matter of patients with multiple sclerosis, including good correlation with clinical status (4, 7).

Color-encoded MTR maps may be useful because they allow a direct evaluation of tissue morphology with regard to its integrity or destruction.

In conclusion, the specific mechanism of MT based on the relationship between macromolecules and water protons has led to an *in vivo* characterization of these lesions. This work has demonstrated a difference in the MTR values of PML lesions and white matter HIV encephalitis lesions. In difficult cases, morphologic analysis

of the lesion by means of MT may contribute to the proper diagnosis.

Acknowledgement

We thank Ray Cooke for his invaluable linguistic help.

References

1. Wolff SD, Balaban RS. Magnetization transfer contrast (MTC) and tissue water proton relaxation in vivo. *Magn Reson Med* 1989;10:135-144
2. Morrison C, Henkelman RM. A model for magnetization transfer in tissues. *Magn Reson Med* 1995;33:475-482
3. Harrisson R, Bronskill MJ, Henkelman RM. Magnetization transfer and T2 relaxation components in tissue. *Magn Reson Med* 1995;33:490-496
4. Dousset V, Grossman RI, Ramer KN, et al. Experimental allergic encephalomyelitis and multiple sclerosis: lesion characterization with magnetization transfer imaging. *Radiology* 1992;182:483-491
5. Dousset V, Brochet B, Vital A, et al. Lysolecithin- induced myelination in primates: in vivo study by magnetic resonance imaging and magnetization transfer. *AJNR Am J Neuroradiol* 1995;16:225-231
6. Gass A, Barker GJ, Kidd D, et al. Correlation of magnetization transfer ratio with clinical disability in multiple sclerosis. *Ann Neurol* 1994;36:62-67
7. Hiehle JF, Lenkinski RE, Grossman RI, et al. Correlation of spectroscopy and magnetization transfer in the evaluation of demyelinating lesions and normal appearing white matter in multiple sclerosis. *Magn Reson Med* 1994;32:285-293
8. Loevner LA, Grossman RI, McGowan JC, Ramer KN, Cohen JA. Characterization of multiple sclerosis plaques with T1-weighted MR and quantitative magnetization transfer. *AJNR Am J Neuroradiol* 1995;16:1473-1479
9. Tomiak MM, Rosenblum JD, Prager JM, Metz CE. Magnetization transfer: a potential method to determine the age of multiple sclerosis lesions. *AJNR Am J Neuroradiol* 1994;15:1569-1574
10. Filippi M, Campi A, Dousset V, et al. A magnetization transfer imaging study of normal-appearing white matter in multiple sclerosis. *Neurology* 1995;45:478-481
11. Wolff SD, Balaban RS. Magnetization transfer imaging: practical aspects and clinical applications. *Radiology* 1994;192:593-599
12. Guilleux MH, Steiner RE, Young IR. MR imaging in progressive multifocal encephalopathy. *AJNR Am J Neuroradiol* 1986;7:1033-1035
13. Hansman Witheman ML, Post MJ, Berger JR, Tate LG, Bell MD, Limonte LP. Progressive multifocal leukoencephalopathy in 47 HIV-seropositive patients: neuroimaging with clinical and pathologic correlation. *Radiology* 1993;187:233-240
14. Post MJD, Berger JR, Quencer RM. Asymptomatic and neurologically symptomatic HIV-seropositive individuals: prospective evaluation with cranial MR imaging. *Radiology* 1991;178:131-139
15. Broderick DF, Wippold FJ II, Clifford DB, Kido D, Wilson BS. White matter lesions and cerebral atrophy on MR images in patients with and without AIDS dementia complex. *AJR Am J Roentgenol* 1993;161:177-181
16. Sarrazin JL, Soulié D, Derosier C, Lescop J, Schill H, Cordoliani YS. MRI patterns of progressive multifocal leukoencephalopathy. *J Neuroradiol* 1995;22:172-179
17. Richardson EP, Webster HF. Progressive multifocal leukoencephalopathy: its pathological features. *Prog Clin Biol Res* 1983;105:183-190
18. Brew BJ. The clinical spectrum and pathogenesis of HIV encephalopathy, myelopathy, and peripheral neuropathy. *Curr Opin Neurol* 1994;7:209-216
19. Artigas J, Grosse, Niedobitek F. Neuropathology of AIDS. In: Artigas J, Grosse, Niedobitek F, eds. *The Central Nervous System in AIDS*. Berlin, Germany: Springer-Verlag; 1993:79-200
20. Power C, Kong PA, Crawford TO, et al. Cerebral white matter changes in acquired immunodeficiency syndrome dementia: alterations of the blood-brain-barrier. *Ann Neurol* 1993;34:339-350
21. Dawson VL, Dawson TM, Uhl GR, Snyder H. Human immunodeficiency virus type 1 coat protein neurotoxicity mediated by nitric oxide in primary cortical cultures. *Proc Natl Acad Sci U S A* 1993;90:3256-3259
22. Toggas SM, Masliah E, Rockenstein EM, Rall GF, Abraham CR, Mucke L. Central nervous system damage produced by expression of HIV-1 coat protein gp120 in transgenic mice. *Nature* 1994;367:188-193
23. Budka H. Human immunodeficiency virus (HIV)-induced disease of the central nervous system: pathology and implications for the pathogenesis. *Acta Neuropathol* 1989;77:225-236
24. Sidtis JJ, Gatsonis C, Price RW, et al. Zidovudine treatment of the AIDS dementia complex: results of a placebo-controlled trial. *Ann Neurol* 1993;33:343-349