

Are your **MRI contrast agents** cost-effective?

Learn more about generic **Gadolinium-Based Contrast Agents**.



**FRESENIUS
KABI**

caring for life

AJNR

**Beyond the promontory: the multifocal origin
of glomus tympanicum tumors.**

J L Weissman and B E Hirsch

AJNR Am J Neuroradiol 1998, 19 (1) 119-122

<http://www.ajnr.org/content/19/1/119>

This information is current as
of April 20, 2024.

Beyond the Promontory: The Multifocal Origin of Glomus Tympanicum Tumors

Jane L. Weissman and Barry E. Hirsch

PURPOSE: We examined other middle ear locations of glomus tympanicum tumors, which arise from glomus bodies accompanying the tympanic (Jacobson's) nerve through the middle ear. Most descriptions place these tumors on the promontory over the basal turn of the cochlea.

METHODS: We identified seven patients (all women) with small surgically confirmed glomus tympanicum tumors (not completely filling the middle ear) for whom CT scans were available for retrospective review. Patients' ages ranged from 23 to 78 years at the time of the high-resolution CT study (1.0- to 1.5-mm-thick sections).

RESULTS: All tumors arose on the medial wall of the middle ear. One was anterior to the promontory, beneath the cochleariform process and the semicanal of the tensor tympani. Two were inferior to the promontory, in the recess beneath the basal turn of the cochlea. Four were anteroinferior. None was actually on the apex of the promontory.

CONCLUSION: Glomus tympanicum tumors may arise in various locations on the medial wall of the middle ear, where Jacobson's nerve runs. The promontory is only one middle ear location in which glomus tympanicum tumors may arise. Familiarity with the course of the tympanic nerve helps tailor the search for, and facilitates accurate identification of, tiny glomus tympanicum tumors.

The promontory is the convexity made by the basal turn of the cochlea on the medial wall of the middle ear (1). Glomus tympanicum tumors, the most common of the primary middle ear neoplasms (2-4), are usually described as arising on the promontory (4). Encountering glomus tympanicum tumors in other locations prompted this investigation into the middle ear origins of these tumors.

Methods

A review of the computerized clinical files from January 1, 1985, through June 30, 1996, revealed 22 patients in whom glomus tympanicum tumors had been removed at our institution. Computed tomographic (CT) scans of 14 patients were available for retrospective review. In seven cases, the tumor completely filled the middle ear so that the site of origin could not be determined. In the other seven cases, the tumors appeared as small, discrete masses. These seven patients, all women, constituted our study group. Their ages ranged from 23 to 78 years at the time the high-resolution CT examination was

performed. Six studies consisted of both axial and coronal bone algorithms, 1.0- to 1.5-mm thick; in one case, only axial scans were obtained. All seven tumors had been removed surgically and confirmed histologically.

Results

In six patients, the tumor was in the right ear; in one, the tumor was on the left side. The tumors ranged from 1.5 to 7.5 mm in the single greatest transverse dimension on axial and coronal scans. All were located on the medial wall of the middle ear. Two were in the recess inferior to the basal turn convexity (Fig 1). One was anterior to the promontory, beneath the cochleariform process and semicanal for the tensor tympani, near the middle ear opening of the eustachian tube (Fig 2). In four patients, the tumors were both anterior and inferior to the basal turn of the cochlea (Fig 3). This location could be appreciated on axial scans, but was most easily seen on coronal scans (Fig 3A).

Discussion

Glomus tympanicum tumors are middle ear paragangliomas that arise from Jacobson's nerve. In comparison, glomus jugulare tumors arise from the adventitia of the jugular vein in the jugular fossa (2). The term *glomus jugulotympanicum* may be used when a tumor is so large that this distinction cannot be made, or when a glomus jugulare tumor grows into

Received February 7, 1997; accepted after revision May 30.

Presented at the annual meeting of the American Society of Head and Neck Radiology/American Society of Neuroradiology, May 1997, Toronto, Ontario, Canada.

From the Departments of Radiology (J.L.W.) and Otolaryngology (J.L.W., B.E.H.), University of Pittsburgh (Pa) Medical Center.

Address reprint requests to Jane L. Weissman, MD, Department of Radiology, Room D-132 PUH, University of Pittsburgh Medical Center, 200 Lothrop St, Pittsburgh, PA 15213.

FIG 1. Glomus tympanicum tumor beneath the promontory.

A, Coronal CT scan shows the small glomus tympanicum tumor (wavy arrow) on the bone (b) beneath the cochlea (black arrow) and the promontory (straight white arrow).

B, Axial CT scan shows the tumor (arrow) on the bone (b) inferior to the cochlea. This scan was obtained at a level beneath the cochlea and, therefore, beneath the promontory. C indicates petrous carotid canal.

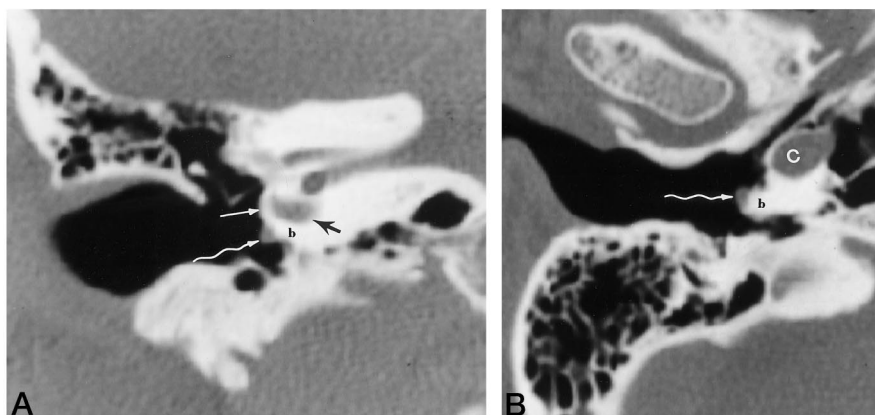
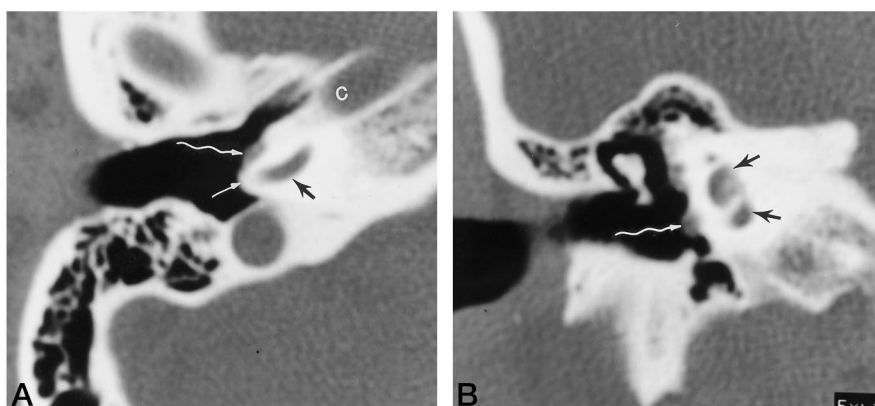


FIG 2. Glomus tympanicum tumor anterior to the promontory.

A, Axial CT scan shows a small tumor (wavy arrow) that is completely anterior to the promontory (straight white arrow), which is the convexity of bone over the basal turn of the cochlea (black arrow). C indicates carotid canal.

B, Coronal CT scan through the cochlea (black arrows) anterior to the promontory shows the tumor (wavy arrow) on the medial wall of the middle ear. Because this scan was obtained anterior to the promontory, the medial wall of the middle ear is flat, not convex, as it would be over the promontory (compare with Fig 1A).



the middle ear (2). These are tumors of middle age, found two to five times more frequently in women than in men (2).

Glomus tumors arise from glomus bodies. Glomus bodies, or nonchromaffin paraganglias (3, 5), are normal components of the diffuse neuroendocrine system (6) that accompany cranial nerves. The function of most paraganglia in the head and neck is obscure; one exception is the carotid body, which is a chemoreceptor. A glomus body of the middle ear (the glomus tympanicum) may also serve as a chemoreceptor, sampling gas composition in the middle ear to maintain normal middle ear pressure (7).

In the temporal bone, glomus bodies accompany the tympanic (or Jacobson's) nerve, a branch of the glossopharyngeal nerve, and Arnold's nerve, the auricular branch of the vagus nerve (5). Arnold's nerve enters the facial canal to join the facial nerve (5). Jacobson's nerve arises from the inferior (petrous) ganglion of the glossopharyngeal nerve (2, 3, 5, 8), then enters the middle ear through the minuscule (inferior) tympanic canaliculus (3, 8, 9) (Fig 4). This canaliculus runs between the petrous carotid canal and the jugular fossa (Fig 4).

The tympanic nerve runs along the medial wall of the middle ear and across the promontory. The promontory is bounded anteriorly by the cochleariform process, a small osseous hook that is the anterior extension of the semicanal for the tensor tympani muscle (9); posteriorly and inferiorly by the round

window niche; and superiorly and posteriorly by the oval window, the horizontal (tympanic) portion of the facial nerve canal, and the lateral semicircular canal (9). The tympanic nerve, as it crosses the promontory, ramifies as the tympanic plexus in one of several patterns: within a complete canal (9), within a sulcus (9) or groove (3, 9), or in the submucosa (3, 5, 9). The plexus also receives input from the caroticotympanic nerve (sympathetic fibers that accompany the internal carotid artery) (3). Beneath the cochleariform process, the tympanic plexus coalesces as the lesser superficial petrosal nerve (5, 9), which leaves the anterior middle ear heading toward the vidian canal (Fig 4).

Anatomists and pathologists have long known that glomus bodies (the glomus tympanicum) exist along the course of Jacobson's nerve (2, 5, 10–12). What may be the earliest report, which appeared in 1941, described "structures, in several respects like the carotid body" along the course of "the ramus tympanicus . . . over the cochlear promontory" (11). Guild (5), in a large review of histologic temporal bone sections, described up to 12 "glomus formations" along Jacobson's nerve in each ear. These tended to cluster within the tympanic canaliculus, on the promontory over the basal turn of the cochlea, and in an osseous canal beneath the cochleariform process and tendon of the tensor tympani muscle. The most frequent location was over the promontory, which may explain why so many radiologic descriptions use this term, and why

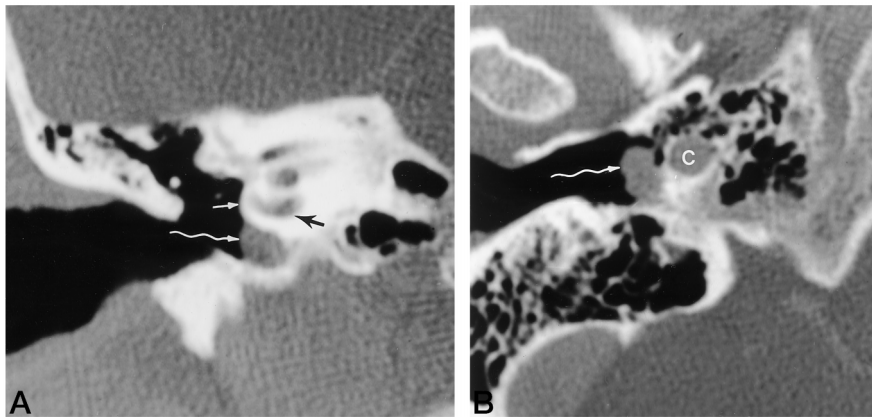


FIG 3. Glomus tympanicum tumor anterior and inferior to the promontory.

A, Coronal CT scan shows a larger tumor (*wavy arrow*) that fills the hypotympanum beneath the cochlea (*black arrow*). The tumor does not extend up to the promontory (*straight white arrow*) over the basal turn of the cochlea (*black arrow*).

B, Axial CT scan obtained beneath the cochlea shows the tumor (*arrow*) extending within the middle ear as far anteriorly as the carotid canal (C). Compare the location of this tumor (and its relationship to the carotid canal) with the location of the smaller tumor in Figure 1B.

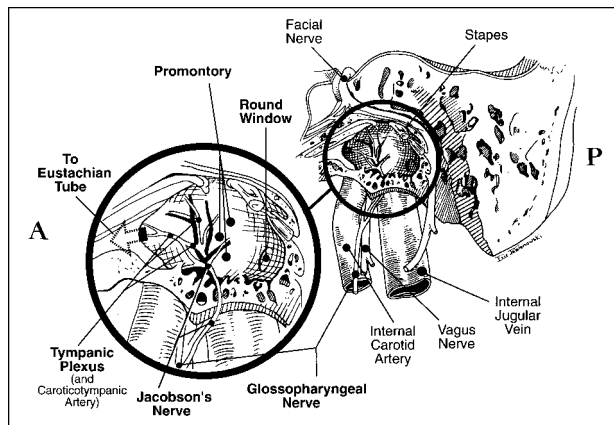


FIG 4. Illustration shows a lateral view of the left temporal bone. The tympanic (Jacobson's) nerve arises from the glossopharyngeal nerve and enters the middle ear through the tympanic canaliculus. Jacobson's nerve forms the tympanic plexus, which ramifies on the medial wall of the middle ear. Glomus bodies accompany the nerve throughout the middle ear, not just over the promontory. Anterior is to the reader's left; the mastoid air cells (reader's right) are posterior. The malleus and incus have been removed. The mastoid air cells are posterior (P); the eustachian tube is anterior (A).

so many published examples of CT scans show tumors on the promontory. However, the pathologists found that the locations were "inconstant," meaning glomus bodies were found anywhere along the nerve (5).

Most glomus tympanicum tumors are accompanied by pulsatile tinnitus. If otoscopy reveals a pulsatile middle ear mass, patients are usually referred for CT, the results of which help determine surgical planning. High-resolution CT of the temporal bones is the examination of choice for evaluating temporal bone glomus tumors (13). Bone algorithms delineate the anatomic extent of tumor (14).

It may be difficult both clinically and radiologically to determine the site of origin of a glomus tympanicum tumor that is so large that it fills the middle ear (15, 16). For this reason, large tumors were excluded from our study. Tumors originating within the tympanic canaliculus can be difficult to distinguish from jugulotympanic tumors. Glomus jugulotympanic tumors grow into the middle ear, but they arise from glomus bodies in the adventitia of the jugular bulb.

Because they do not originate in the middle ear, glomus jugulotympanic tumors were also excluded from this study. Facial nerve glomus tumors are rare, and our search disclosed none in the clinical files.

Previous reports have described the CT location of glomus tympanicum tumors as promontory or hypotympanum (4, 13-19). These CT scans showed tumor on the promontory in some instances (14), but other illustrations clearly showed tumors anterior or inferior to the promontory. The reasons for this discrepancy are not clear. Authors may apply the term *promontory* imprecisely, to refer to any location on the medial wall of the middle ear, or broadly, encompassing the apex of the promontory as well as the surrounding bone. One of our goals was to eliminate this confusion by describing the promontory unequivocally as the convexity of bone over the basal turn of the cochlea and by labeling the promontory carefully (see Figs 1A, 2A, and 3A).

Among our study population, no patient had a tumor that was directly on the promontory, although all tumors were clustered near the promontory. It seems unusual that none of these seven tumors was on the promontory, since many of the glomus tympanicum tumors described previously were clearly on the promontory, and glomus bodies are concentrated in this location. However, the current study is a small (and retrospective) one, and this apparent aberration may be statistical.

Conclusion

A glomus tympanicum tumor is not necessarily a mass on the promontory. The various locations on the medial wall of the middle ear in which glomus tympanicum tumors arise are predictable, corresponding to the locations of middle ear glomus bodies. The promontory is just one of these many locations. An understanding of the origin of these tumors from the glomus bodies accompanying Jacobson's nerve, and of the course of this nerve through the middle ear, will facilitate the search for and the accurate diagnosis of small glomus tympanicum tumors.

Acknowledgments

We are grateful to Sabrina L. Jennings for her outstanding secretarial assistance, and to Eric Jablonowski for his beautiful artwork.

References

1. *Stedman's Medical Dictionary*. 26th ed. Baltimore, Md: Williams & Wilkins; 1995:1437
2. Barnes L, Peel RL, Verbin RS. **Tumors of the nervous system**. In: Barnes L, ed. *Surgical Pathology of the Head and Neck*. New York, NY: Marcel Dekker; 1985:659-724
3. Schuknecht HF. **Pathology of the Ear**. 2nd ed. Philadelphia, Pa: Lea & Febiger; 1993:452-460
4. Lo WWM, Solti-Bohman LG. **Tumors of the temporal bone and the cerebellopontine angle**. In: Som PM, Curtin HD, eds. *Head and Neck Imaging*. 3rd ed. St Louis, Mo: Mosby-Year Book; 1996:1449-1534
5. Guild SR. **The glomus jugulare, a nonchromaffin paraganglion in man**. *Ann Otol Rhinol Laryngol* 1953;62:1045-1071
6. Gulya AJ. **Paraneoplastic disorders**. In: Jackler RK, Brackmann DE, eds. *Neurotology*. St Louis, Mo: Mosby; 1994:535-542
7. Rockley TJ, Hawke M. **The glomus tympanicum: a middle ear chemoreceptor?** *J Otolaryngol* 1989;18:370-373
8. Duckert LG. **Anatomy of the skull base, temporal bone, external ear, and middle ear**. In: Cummings CW, Fredrickson JM, Harker LA, Krause CJ, Schuller DE, eds. *Otolaryngology: Head and Neck Surgery*. 2nd ed. St Louis, Mo: Mosby-Year Book; 1993:2483-2496
9. Donaldson JA, Duckert LG, Lambert PM, Rubel EW. **Anson and Donaldson: Surgical Anatomy of the Temporal Bone**. 4th ed. New York, NY: Raven Press; 1992:245, 415
10. Lattes R, Waltner JG. **Nonchromaffin paraganglioma of the middle ear**. *Cancer* 1949;2:447-468
11. Guild SR. **A hitherto unrecognized structure, the glomus jugularis, in man**. *Anat Rec* 1941;79:28
12. Curtin HD, Som PM, Bergeron RT. **Temporal bone embryology and anatomy**. In: Som PM, Curtin HD, eds. *Head and Neck Imaging*. 3rd ed. St Louis, Mo: Mosby-Year Book; 1996:1300-1318
13. Som PM, Reede DL, Bergeron RT, Parisier SC, Shugar JMA, Cohen NL. **Computed tomography of glomus tympanicum tumors**. *J Comput Assist Tomogr* 1983;7:14-17
14. Larson TC, Reese DF, Baker HL, McDonald TJ. **Glomus tympanicum chemodectomas: radiographic and clinical characteristics**. *Radiology* 1987;163:801-806
15. Swartz JD. **Imaging of the Temporal Bone: A Text/Atlas**. New York, NY: Thieme Medical Publishers; 1986
16. Valvassori GE, Buckingham RA. **Imaging of the temporal bone: glomus tumors**. In: Valvassori GE, Mafee MF, Carter BL, eds. *Imaging of the Head and Neck*, 2nd ed. New York, NY: Thieme Medical Publishers; 1995:118-127
17. Phelps PD. **Glomus tumours of the ear: an imaging regime**. *Clin Radiol* 1990;41:301-305
18. Phelps PD, Lloyd GA. **Vascular masses in the middle ear**. *Clin Radiol* 1986;37:359-364
19. Probst LE, Shankar L, Hawke M. **Imaging case of the month: radiological features of glomus tympanicum and glomus jugulare**. *J Otolaryngol* 1991;20:225-227