

# Age-Related Vasodilatory Response to Acetazolamide Challenge in Healthy Adults: A Dynamic Contrast-Enhanced MR Study

Jeffrey R. Petrella, Charles DeCarli, Mandeep Dagli, Cécile B. Grandin, Josef H. Duyn, Joseph A. Frank, Elizabeth A. Hoffman, and William H. Theodore

**PURPOSE:** We examined age-related changes in baseline regional cerebral blood volume (rCBV) and response to acetazolamide stimulation by using dynamic contrast-enhanced MR imaging.

**METHODS:** Thirty healthy volunteers ranging widely in age (23 to 82 years) were examined before and after intravenous injection of acetazolamide with dynamic susceptibility contrast-enhanced MR imaging. rCBV values were normalized for intersubject and intrasubject comparison by estimating an arterial input function directly from the imaging data. Preacetazolamide baseline rCBV and the percentage volume change index (PVCi) of the postacetazolamide to preacetazolamide state were calculated and examined as a function of age.

**RESULTS:** Older adults (>50 years) had lower baseline rCBV per unit tissue than did younger adults (<50 years), but higher rCBV after acetazolamide stimulation. Baseline rCBV tended to decrease with age in the medial frontal and frontoparietal gray matter regions. Response to acetazolamide stimulation, measured by PVCi, showed a significant age-related increase in gray matter, approximately 0.5% per year.

**CONCLUSION:** rCBV can be significantly increased after acetazolamide stimulation in the healthy aged. These results support the notion that age-related decreases in rCBV measured at rest reflect reduced regional metabolic requirements rather than reduced capacity for regional substrate delivery. These data serve as a normative baseline for comparison studies of rCBV vascular reserve in aging persons with various cerebrovascular disorders.

Although age-related decreases in brain volume, cerebral metabolism, and blood flow (1–3) accompany normal human aging, microvascular studies reveal relative preservation of the cerebrovascular capillary bed (4, 5), implying that substantial vascular reserve may be present in older persons despite loss in parenchymal volume. Vascular reserve in humans can be measured by various methods (6). Most commonly, regional cerebral blood flow (rCBF) or blood

volume (rCBV) is measured before and after a vasodilatory challenge and the two measurements are compared. Studies measuring changes in rCBF using xenon single-photon emission computed tomography after vasodilatory challenge with acetazolamide (7, 8) have shown significant age-related decreases in rCBF cerebrovascular reserve. Studies measuring age-related changes in rCBV after acetazolamide challenge, however, have not been reported, although a number of studies have evaluated rCBV cerebrovascular reserve in the setting of severe extracranial carotid occlusive disease (9, 10). Age-related normative values are therefore important for understanding the effect of cerebrovascular disease on rCBV cerebrovascular reserve measures.

Recently, dynamic contrast-enhanced magnetic resonance (MR) imaging has been proposed as a method for quantitating rCBV (11), and rCBV vascular reserve has been measured with this technique using the acetazolamide challenge (10, 12). In this study, we used dynamic contrast-enhanced MR imaging to determine how rCBV and acetazolamide-induced changes in rCBV varied as a function

---

Received March 14, 1997; accepted after revision June 5.

Dr Grandin was supported by a grant from the "Fondation St Luc," Catholic University of Louvain (Belgium).

Presented at the annual meeting of the American Society of Neuroradiology, Toronto, Ontario, Canada, May 1997.

From the Laboratory of Diagnostic Radiology Research (J.R.P., M.D., J.H.D., J.A.F.), the National Institute of Neurological Disorders and Stroke (C.D., E.A.H., W.H.T), and the In Vivo NMR Research Center (C.B.G.), National Institutes of Health, Bethesda, Md; and the Department of Radiology, Hospital of the University of Pennsylvania, Philadelphia (J.R.P).

Address reprint requests to Jeffrey R. Petrella, MD, Department of Radiology, Box 3808, Duke University Medical Center, Durham, NC 27710.

of age in 30 healthy adult humans over a broad age range.

## Methods

### Subjects

Our study was approved by the Intramural Research Review Board of the National Institutes of Neurological Disorders and Stroke, National Institutes of Health, Bethesda, Md. Thirty healthy subjects ranging in age from 23 to 82 years (mean,  $47 \pm 20$  years) were recruited from the community. All subjects had normal findings on a screening examination, which consisted of a full medical and neurologic history and physical examination. The exclusion criteria included a history of cardiovascular disease, diabetes, hypertension, head trauma, previous central nervous system (CNS) infections, exposure to CNS toxins, metabolic or endocrinologic diseases, and psychiatric history. Written informed consent was obtained from all subjects.

### Study Design

A dynamic contrast-enhanced MR imaging study was performed in each volunteer to look at baseline rCBV values as a function of age. Imaging was also performed after intravenous administration of acetazolamide (15 mg/kg) and a 50- to 60-minute (mean,  $50 \pm 9$  minutes) postinjection rest period outside the magnet to assess rCBV vascular reserve as a function of age. Perfusion images were analyzed to calculate gray and white matter baseline rCBV values and poststimulation rCBV values. The imaging protocol and data analysis methods have been described in detail elsewhere (12), and will only be reviewed here briefly.

### Imaging Protocol

A 20-gauge intravenous catheter was placed in an antecubital vein and connected to an MR-compatible double syringe prototype power injector (Medrad, Pittsburgh, Pa) containing gadopentetate dimeglumine in one syringe and normal saline in the other. Imaging was performed on a conventional 1.5-T MR system using a standard quadrature head coil. Routine structural images were obtained before dynamic contrast-enhanced MR imaging using short-repetition-time spin-echo and double-echo long-repetition-time fast spin-echo techniques. Whole-brain dynamic susceptibility contrast-enhanced MR imaging was performed using a three-dimensional frequency-shifted burst sequence (65/42.5/1 [repetition time/echo time/excitations]) with a  $90^\circ$  flip angle), which has been described previously in detail (12, 13). A total of 40 brain sequences (voxel size,  $4.0 \times 4.0 \times 6.1$  mm; matrix,  $40 \times 48 \times 36$ ) were obtained during the bolus injection, for a total imaging time of 1 minute 29 seconds. The bolus injection was started 20 seconds into the acquisition, using a dose of 0.1 mmol/kg gadopentetate dimeglumine followed immediately by 24 mL of normal saline flush, both at the maximal injector flow rate of 6 mL/s.

### Image Analysis

Reconstruction and analysis of the dynamic contrast-enhanced MR images to obtain rCBV values were performed according to a previously described method (12), and will be briefly reviewed. In this method, the images were registered (14) to correct for interscan motion during the examination and differences in positioning between the preacetazolamide and postacetazolamide examinations. Using the first volume of the preacetazolamide data set as a reference, we drew regions of interest in each hemisphere to correspond to the major cortical cerebrovascular distributions (15) and the supraventricular white matter. The gray matter regions were as follows: medial frontal, corresponding to the anterior cerebral artery territory;

frontoparietal, corresponding to the middle cerebral artery territory; and occipital, corresponding to the posterior cerebral artery territory. Time signal intensity curves were generated for each voxel in the region of interest and averaged into a single time signal intensity curve over the 40 time points. This curve was converted to a time concentration curve, which was then fit with a gamma variate function to remove the effect of recirculation (16). The area under the fitted curve was then determined, and rCBV was calculated in arbitrary units. To normalize the rCBV values for interexamination comparisons, an arterial input function unique to each examination was obtained directly from the images using an empirically developed algorithm to select arterial voxels. The rCBV values were converted to fractional rCBV units (milliliter of blood per milliliter of brain tissue) by dividing them by the area under the arterial input function. The fractional rCBV values were multiplied by 0.73 to adjust for the difference in percentage of plasma volume between tissues and arteries accountable by different hematocrits (17).

Regions of interest drawn from the preacetazolamide data set were applied to both preacetazolamide and postacetazolamide data sets for calculation of rCBV values.

### Data Analysis

rCBVs were described in units of fractional blood volume (milliliter of blood per unit milliliter of brain tissue), and summarized as mean  $\pm$  SD. Response to acetazolamide was determined by calculating a percentage volume change index (PVCI) (18) of the post- to preacetazolamide state as follows:

$$PVCI = \frac{rCBV_{\text{post}} - rCBV_{\text{pre}}}{rCBV_{\text{pre}}}$$

where  $rCBV_{\text{pre}}$  and  $rCBV_{\text{post}}$  represent the preacetazolamide and postacetazolamide rCBV values, respectively.

To analyze the data statistically, we used repeated measures of analysis of variance to assess differences between younger (<50 years) and older (>50 years) groups with regard to baseline rCBV and response to acetazolamide. We also performed multiple regression analysis to assess general age-related trends in baseline rCBV and response to acetazolamide. Statistical significance was defined as  $P = .05$ .

## Results

### Baseline rCBV

Older adults (>50 years;  $n = 15$ ) had a lower mean preacetazolamide rCBV than did younger adults (<50 years;  $n = 15$ ) in both gray and white matter regions (see the Table 1 and Fig 1). These differences did not reach statistical significance, however. Baseline rCBV tended to decrease with age in the medial frontal and frontoparietal gray matter regions, but these trends also did not reach statistical significance (Fig 2). Neither age group showed a significant gray matter regional difference in baseline rCBV.

### Postacetazolamide rCBV

Older adults had a higher mean postacetazolamide rCBV than did younger adults in the medial frontal and frontoparietal gray matter and white matter; however, these differences were not statistically significant. Both age groups showed a regional difference in postacetazolamide rCBV, with a statistically significantly higher value in the medial frontal region as compared with all other regions (Table 1).

**Differential age-related regional cerebral blood volume response to acetazolamide challenge**

Region	Younger Adults (<50 y), n = 15			Older Adults (≥50 y), n = 15		
	Before Acetazolamide*	After Acetazolamide*	Percentage Volume Change Index	Before Acetazolamide*	After Acetazolamide*	Percentage Volume Change Index
Gray matter (overall)	22.9 ± 3.5	26.8 ± 6.6	17.0	21.4 ± 2.5	27.8 ± 5.0	29.9
Medial frontal	24.1 ± 4.8	28.3 ± 7.3	17.4†	21.4 ± 4.3	30.4 ± 6.5	42.1†
Frontoparietal	22.7 ± 3.9	26.1 ± 7.3	15.0	21.0 ± 3.4	28.0 ± 4.6	33.3
Occipital	21.9 ± 4.5	25.9 ± 6.0	18.3	21.8 ± 4.0	25.6 ± 5.1	17.4
White Matter	12.2 ± 3.2	15.0 ± 3.9	23.0	11.9 ± 1.7	16.7 ± 2.9	40.3

\* Units are in fractional cerebral blood volume or percentage of blood volume per unit volume brain tissue.

† Statistically significant difference between younger and older groups.

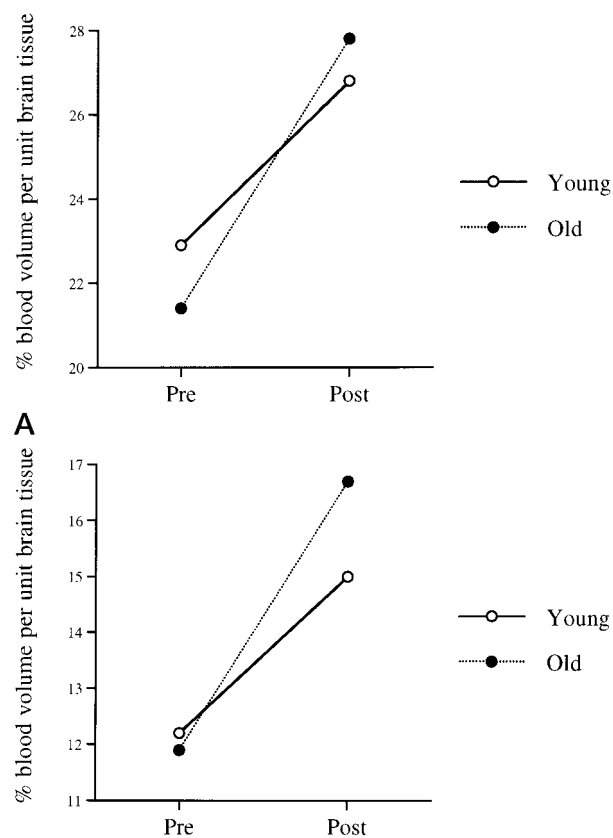


Fig 1. Effect of acetazolamide challenge on rCBV in younger (<50 years, n = 15) and older (>50 years, n = 15) healthy adult volunteers in gray (A) and white (B) matter.

### Acetazolamide Response

Acetazolamide challenge produced a statistically significant increase in rCBV in all regions studied. Older adults had a significantly higher rCBV response to acetazolamide stimulation than did younger adults in the medial frontal gray matter region, as assessed by repeated measures of analysis of variance ( $P < .05$ ). Moreover, looking at age as a continuous variable, the PVCI showed a significant age-related increase in the medial frontal and frontoparietal regions, as well as in the gray matter overall ( $P < .05$ ) (Fig 3). Response was inversely correlated with base-

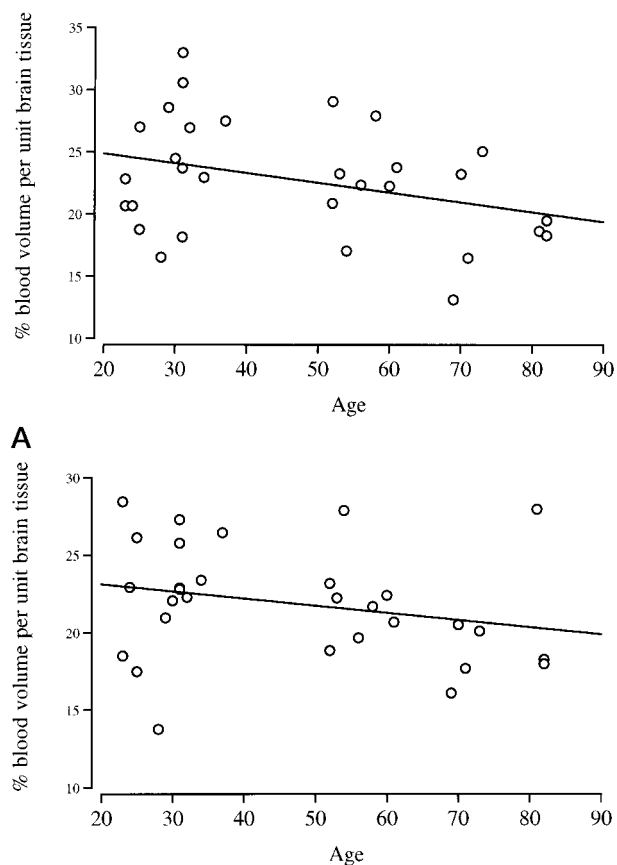


Fig 2. Effect of age on baseline rCBV in the medial frontal (A) and frontoparietal (B) gray matter regions in 30 healthy volunteers.

line rCBV in the medial frontal gray matter and white matter regions ( $P < .05$ ) (Fig 4).

### Discussion

In this study, we used dynamic contrast-enhanced MR imaging to show that acetazolamide-induced changes in rCBV vary as a function of age in healthy adult humans. When evaluating global gray matter response to acetazolamide, we found that PVCI increased by approximately 0.5% per year of age. In addition, older adults (>50 years) had a significantly

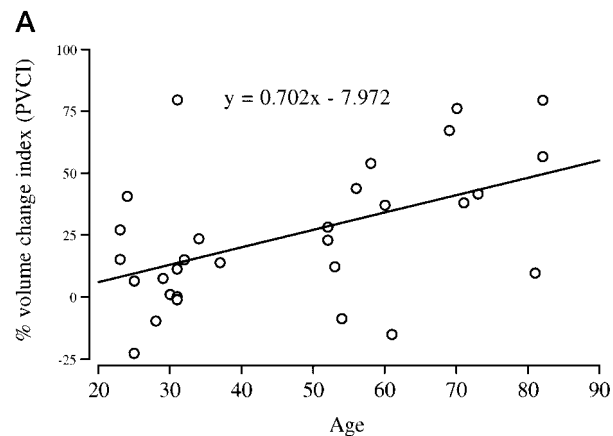
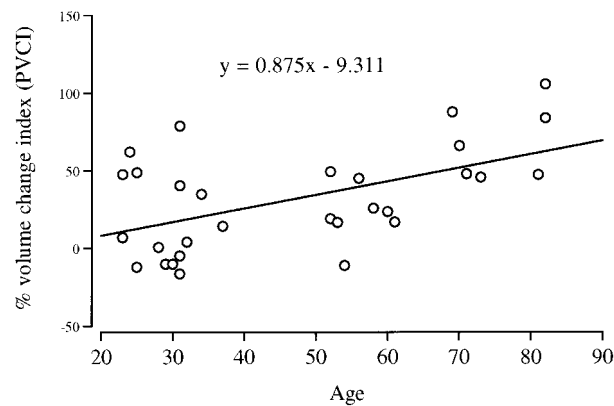
**B**

FIG 3. Effect of age on response to acetazolamide stimulation, measured by PVCI, in the medial frontal (A) and frontoparietal (B) gray matter regions in 30 healthy volunteers. A significant age-related increase was seen in both regions ( $P < .05$ ).

greater PVCI in the medial frontal gray matter region as compared with younger adults (<50 years). Conversely, and consistent with other studies of age-related rCBF (2, 3), baseline rCBV, before acetazolamide stimulation, tended to decrease with age, particularly in the medial frontal gray matter region.

The reason for an age-related increase in acetazolamide-induced rCBV response is uncertain. Age-related neuronal loss is thought to be the principal cause of atrophy and decreased oxygen (19) and glucose use (1) in gray matter. Because oxidative metabolism and blood supply are closely coupled (20), decreases in demand normally cause a concomitant decrease in blood supply. However, neuronal loss and brain atrophy are not necessarily accompanied by a reduction in cerebral microvasculature, and it has been shown that the capillary diameter and length (5, 21) per unit volume of brain tissue increase with age, while intercapillary distance decreases (21). Through its vasodilatory effects, acetazolamide causes an increase in blood volume in the capillary bed and an increase in rCBV per unit tissue after stimulation. Because there is more capillary capacitance per unit tissue in older adults, the PVCI is greater.

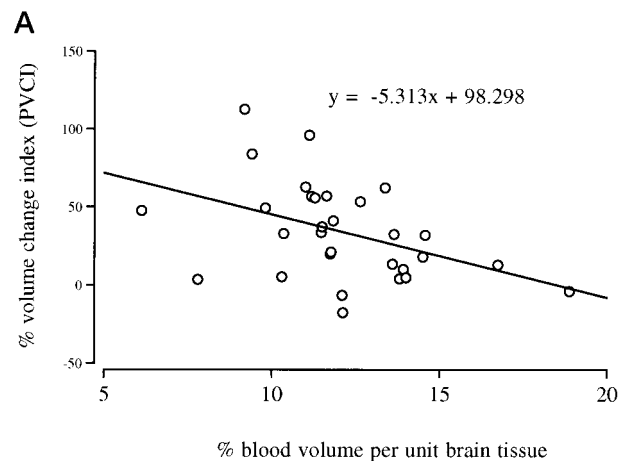
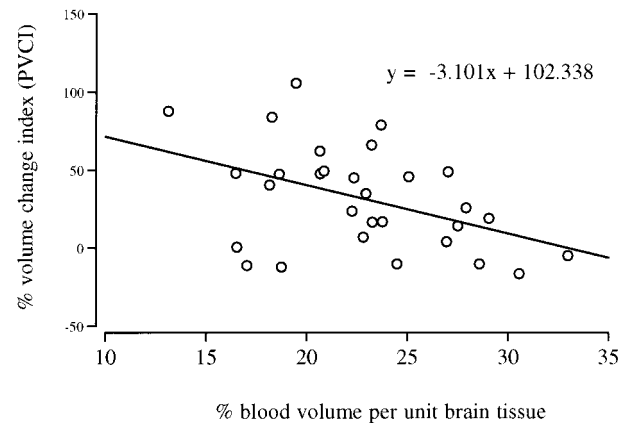
**B**

FIG 4. Effect of baseline rCBV on response to acetazolamide stimulation, measured by PVCI, in the medial frontal gray matter (A) and white matter (B) regions in 30 healthy volunteers. Response was inversely correlated with baseline rCBV in both regions ( $P < .05$ ).

PVCI measures, however, may be biased or artificially elevated in older persons because of a generally lower baseline rCBV than found in younger persons. Given the same absolute difference in rCBV before and after acetazolamide challenge, there would be, by definition, a greater fractional or percentage increase in persons with a lower baseline rCBV. In fact, we showed in our study that PVCI was inversely correlated with baseline rCBV in the medial frontal gray matter and white matter regions (Fig 4). This bias, however, cannot account completely for the age-related increase in rCBV response to acetazolamide. Analysis of the absolute differences between baseline and poststimulation rCBV versus age results in the same age-related increase in response as that seen with PVCI.

These results of age-related increase in rCBV response are the reciprocal of studies examining age-related responses to rCBF (8). The vasodilatory effects of  $\text{CO}_2$  in rhesus monkeys is known to increase rCBV and rCBF in a closely correlated manner, but the relationship between rCBF and rCBV is not linear (22) and may reflect the multiple mechanisms of action attributed to hypercapnia and acetazolamide (6). Acetazolamide decreases smooth muscle tone in

the walls of arteries and arterioles, and reduces the resistance of the precapillary circulation, thereby increasing flow through the capillary bed (23). This increase in flow through the capillary bed expands capillary diameter but also results in recruitment of additional capillaries (24). Although capillary recruitment results in an increase in rCBV, it also causes a relative increase in the average length of the path the blood must traverse, which, according to Poiseuille's law (25), somewhat offsets the augmentation in flow resulting from increases in capillary diameter and number. If older persons have a greater capacity for capillary recruitment per unit volume of brain than younger persons, they will have a greater acetazolamide-induced increase in rCBV but less of an increase in rCBF. The evolution of the normal cortical structure with aging (5) suggests an increased ability to recruit blood vessels on the basis of a per unit volume of brain, and therefore significant age-related variability in capillary capacitance. This might explain the reciprocal age-related response in rCBV and rCBF.

One must not, however, confuse vasodilatory capacity, measured by changes in rCBV, with true cerebrovascular reserve capacity; that is, the ability to maintain normal rCBF in the face of decreased perfusion pressure. It has been suggested that the baseline rCBV or the rCBF/rCBV ratio can be used as an index of cerebral hemodynamic reserve to assess risk of stroke or as an indication for surgery in patients with carotid occlusive disease. This supposition is based on cerebral hemodynamic studies in patients who have shown an increased rCBV, a decreased rCBF/rCBV ratio, and an increased oxygen extraction fraction in areas of "misery perfusion" or hemodynamic stress (9, 26). Such patients typically have a decreased rCBF response to a vasodilatory challenge (10, 27, 28) but a variable rCBV response (9, 10).

We found great intersubject variability in the PVCI, even among subjects of similar ages. Without reproducibility studies, it is difficult to tell how much of this was due to biological variation and how much to a lack of precision in the technique. This study was performed on a 1.5-T system, without specialized gradient hardware, using a frequency-shifted burst pulse sequence that sacrifices spatial resolution and signal-to-noise ratio for whole brain coverage. Although the PVCI is valid, there is loss of precision and systematic bias in absolute rCBV measurements. This issue has been discussed in detail elsewhere (12). Nevertheless, the age-related increase in PVCI found in this study is significant, regardless of the source of variability.

### Conclusion

Dynamic contrast-enhanced MR imaging in healthy adult humans shows an age-related increase in rCBV vascular response to acetazolamide challenge in cerebral gray matter. Our findings, taken together with findings from normal human aging studies of the capillary bed, support the belief that capillary bed architecture is preserved despite the loss

of neuronal and glial tissue that occurs with aging. Data from this study may serve as normative measurements for studies looking at rCBV vascular reserve in patients with cerebrovascular disease.

### Acknowledgments

We thank Jeanette Black, Karen Bove, Renee Hill, and Bobbi Lewis for their technical assistance. We also acknowledge Medrad for providing a prototype dual-head MR-compatible mechanical injector.

### References

1. Yoshii F, Barker WW, Chang JY, et al. **Sensitivity of cerebral glucose metabolism to age, gender, brain volume, brain atrophy and cerebrovascular risk factors.** *J Cereb Blood Flow Metab* 1988; 8:654-661
2. Leenders KL, Perani D, Lammertsma AA, et al. **Cerebral blood flow, blood volume and oxygen utilization: normal values and effect of age.** *Brain* 1990;113:27-47
3. Marchal G, Rioux P, Petit-Taboue M, et al. **Regional cerebral oxygen consumption, blood flow, and blood volume in healthy human aging.** *Arch Neurol* 1992;49:1013-1020
4. Hughes CCW, Lantos PL. **A morphometric study of blood vessel, neuron and glial cell distribution in young and old rat brain.** *J Neurol Sci* 1987;79:101-110
5. Kuschinsky W, Paulson OB. **Capillary circulation in the brain.** *Cerebrovasc Brain Metab Rev* 1992;4:261-286
6. Yonas H, Pindzola RR. **Physiological determination of cerebrovascular reserves and its use in clinical management.** *Cerebrovasc Brain Metab Rev* 1994;6:325-340
7. Leinsinger G, Piepgras A, Einhaupl K, Schmiedek P, Kirsch C. **Normal values of cerebrovascular reserve capacity after stimulation with acetazolamide measured by xenon 133 single-photon emission CT.** *AJNR Am J of Neuroradiol* 1994;15:1327-1332
8. Sullivan HG, Kingsbury TB, Morgan ME, et al. **The rCBF response to Diamox in normal subjects and cerebrovascular disease patients.** *J Neurosurg* 1987;67:525-534
9. Sabatini U, Celsis P, Viallard G, Rascol A, Marc-Vergnes J. **Quantitative assessment of cerebral blood volume by single-photon emission computed tomography.** *Stroke* 1991;22:324-330
10. Guckel F, Brix G, Schmiedek P, et al. **Cerebrovascular reserve capacity in patients with occlusive cerebrovascular disease: assessment with dynamic susceptibility contrast-enhanced MR imaging and the acetazolamide stimulation test.** *Radiology* 1996;201:405-412
11. Rempp M, Gunnar B, Wenz F, Becker C, Guckel F, Lorenz W. **Quantification of regional cerebral blood flow and volume with dynamic susceptibility contrast-enhanced MR imaging.** *Radiology* 1994;193:637-641
12. Petrella JR, DeCarli C, Dagli M, et al. **Assessment of whole-brain vasodilatory capacity with acetazolamide challenge at 1.5 T using dynamic contrast imaging with frequency-shifted burst.** *AJNR Am J Neuroradiol* 1996;18:1153-1161
13. Duyn JH, van Gelderen P, Barker P, Frank JA, Mattay VS, Moonen CT. **3D bolus tracking with frequency-shifted BURST MRI.** *J Comput Assist Tomogr* 1994;18:680-687
14. Woods RP, Cherry SR, Mazziotta JC. **Rapid automated algorithm for aligning and reslicing PET images.** *J Comput Assist Tomogr* 1992;16:620-633
15. Latchaw RE. **MR and CT Imaging of the Head, Neck, and Spine.** St Louis, Mo: Mosby; 1991
16. Thompson HK, Starmer CF, Whalen RE, McIntosh HD. **Indicator transit time considered as a gamma variate.** *Circ Res* 1964;14:502-515
17. Everett N, Simmons B, Laster E. **Distribution of blood (Fe<sup>59</sup>) and plasma (I<sup>131</sup>) volumes of rats determined by liquid nitrogen freezing.** *Circ Res* 1956;4:419-424
18. Greenberg JH, Alavi A, Reivich M, Kuhl D, Uzzel B. **Local cerebral blood volume response to carbon dioxide in man.** *Circ Res* 1978;43:324-331
19. Pantano P, Baron J, Lebrun-Grandi  P, Duquesnoy N, Bousser M, Comar D. **Regional cerebral blood flow and oxygen consumption in human aging.** *Stroke* 1984;15:635-641
20. Des Rosiers MH, Kennedy C, Patlak CS, Pettigrew KD, Sokoloff L, Reivich M. **Relationship between local cerebral blood flow and glucose utilization in man.** *Neurology* 1974;24:389

21. Hunziker O, Abdel'Al S, Frey H, Veteau M-J, Meier-Ruge W. **Quantitative studies in the cerebral cortex of aging humans.** *Gerontology* 1978;24:27-31
22. Grubb RL, Raichle ME, Higgins CS, Eichling JO. **Measurement of regional cerebral blood volume by emission tomography.** *Ann Neurol* 1978;4:322-328
23. Mchedlishvili G. **Arterial Behavior and Blood Circulation in the Brain.** New York, NY: Plenum Press; 1986:338
24. Villringer A, Them A, Lindauer U, Einhaupl K, Dirnagl U. **Capillary perfusion of the rat brain cortex.** *Circ Res* 1994;75:55-62
25. Burns DM, MacDonald SGG. **Physics for Biology and Pre-Medical Students.** London, England: Addison-Wesley; 1970
26. Gibbs JM, Wise RJS, Leenders KL, Jones T. **Evaluation of cerebral perfusion reserve in patients with carotid artery occlusion.** *Lancet* 1984;1:310-314
27. Vorstrup S, Boysen G, Brun B, Engell HC. **Evaluation of the regional cerebral vasodilatory capacity before carotid endarterectomy by the acetazolamide test.** *Neurol Res* 1987;9:10-18
28. Lord RSA, Reid CVA, Ramsay SC, Yeates MG. **Unilateral carotid stenosis and impaired cerebral hemispheric vascular reserve.** *Ann Vasc Surg* 1992;6:438-442