This information is current as of October 11, 2024.

AIDS-related MR hyperintensity of the basal ganglia.

C C Meltzer, S W Wells, M W Becher, K M Flanigan, G A Oyler and R R Lee

AJNR Am J Neuroradiol 1998, 19 (1) 83-89
http://www.ajnr.org/content/19/1/83

AJNR Am J Neuroradiol 19:83–89, January 1998

AIDS-Related MR Hyperintensity of the Basal Ganglia

Carolyn Cidis Meltzer, Scott W. Wells, Mark W. Becher, Kevin M. Flanigan, George A. Oyler, and Roland R. Lee

PURPOSE: **Our goal was to describe the MR imaging appearance and clinical pathologic correlates of bilateral basal ganglia hyperintensity in acquired immunodeficiency syndrome (AIDS).**

METHODS: **Medical records and laboratory data were reviewed retrospectively in nine cases of bilateral basal ganglia hyperintensity on long-repetition-time MR images. Opportunistic infections of the central nervous system were excluded by clinical and laboratory data. Postmortem neuropathologic examination was obtained in two cases.**

RESULTS: **All patients presented acutely with new seizures or changes in mental status. A history of drug abuse was elicited in seven of the nine remaining patients. Renal failure was present in six cases. Symmetric bilateral caudate and putamen hyperintensity on T2-weighted images was found in all cases with variable extension to the surrounding white matter, thalamus, and brain stem. Postmortem neuropathologic examination in two cases revealed numerous microinfarcts in a distribution similar to the MR signal abnormalities.**

CONCLUSION: **The MR appearance of basal ganglia hyperintensity in this series of AIDS patients represents ischemic tissue injury. We propose that this clinicopathologic entity is precipitated by the combined effects of human immunodeficiency virus infection and drug use, particularly cocaine and/or associated toxic contaminants.**

Primary human immunodeficiency virus (HIV) infection of the central nervous system (CNS) is well recognized, with manifestations that include HIV encephalopathy, acquired immunodeficiency syndrome (AIDS) dementia complex, infarctions, and vasculitis (1, 2). There is also evidence to suggest that HIV infection might cause the brain to be more susceptible to parenchymal damage from toxic drug effects (3–5). In 1991, Kodama et al (6) reported two cases of basal ganglia hyperintensity on magnetic resonance (MR) images in HIV-infected patients, one of whom had a history of intravenous drug abuse. We report basal ganglia hyperintensity in nine patients with AIDS, the majority of whom had a history of cocaine use. The corresponding location of the neuropathologic finding of cellular foci with features of microinfarcts and astrocytosis in autopsy material from two cases is consistent with ischemic damage to the basal ganglia and surrounding tissue. The purpose of this work is to describe the clinicopathologic entity of bilateral basal ganglia hyperintensity in AIDS patients and its association with cocaine use.

Methods

We retrospectively reviewed the records of nine patients with bilateral basal ganglia hyperintensity on long-repetition-time MR images who were seen in the emergency department over a 3-year period. Clinical information was obtained by review of the medical records, with particular attention to medical history, HIV status, and history of illegal drug use. Available laboratory data included serum electrolytes, blood urea nitrogen, and creatinine; cryptococcus and toxoplasma serology; CD4 T-lymphocyte count; cerebrospinal fluid (CSF) studies, including cell count, glucose, protein, cryptococcal stain, and VDRL; and serum toxocology. Patients with evidence of CNS infection were excluded. The group consisted of four women and five men, with a mean age of 33 years (range, 26 to 42 years). Seven patients presented with new seizures; two patients came to medical attention because of changes in mental status (Table 1). Noncontrast computed tomography (CT) was performed at the time of admission in seven cases. MR imaging was obtained in all cases within 8 days of presentation (mean interval from presentation to MR imaging, 2 days), with follow-up MR studies obtained in four cases.

Autopsy results were also available in two cases. Postmortem brain specimens from two cases were fixed in 10% neutral-

Received April 1, 1997; accepted after revision July 18.

From the Departments of Radiology (C.C.M.) and Psychiatry (C.C.M.), University of Pittsburgh (Pa) Medical Center; St Francis Xavier Cabrini Hospital, Malvern, Australia (S.W.W.); the Departments of Pathology (M.W.B.), Neurology (G.A.O.), and Radiology (R.R.L.), the Johns Hopkins Medical Institutions, Baltimore, Md; and the Departments of Neurology (K.M.F.) and Pathology (K.M.F.), University of Utah Medical Center, Salt Lake City.

Address reprint requests to Carolyn Cidis Meltzer, MD, University of Pittsburgh Medical Center, PET Facility, B-938, 200 Lothrop St, Pittsburgh, PA 15213.

© American Society of Neuroradiology

TABLE 1: Clinical findings of nine HIV-positive patients

Case	Age, y/Sex	CD4	Presenting Illness	Drug Use	Other Illness	Follow-up Status
1	33/M	47	GTC	Cocaine	None	Seizures continue 3 mo later
2	31/F	167	Status epilepticus	Denied	Renal failure	Died 2 wk later of renal failure
3	41/M	30	GTC	Cocaine, heroin	Renal failure	Died 6 wk later of sepsis, fungal pneumonia
4	32/M	<10	GTC	Cocaine	Renal failure, pancreatitis	Died 6 mo later of renal failure
5	35/F	26	Focal motor seizure confusion	Cocaine, heroin	Renal failure	Died 1 mo later of sepsis
6	42/F	. . .	Lower extremity weakness	Denied	None	Rapid decline in neurologic status and death in 4 wk
7	32/M	. . .	Seizure, unknown type	Cocaine	Renal failure	No follow-up available
8	26/F	<10	Suicidal ideation, auditory hallucinations	Cocaine, heroin	None	No follow-up available
9	27/M	20	GTC	Cocaine	Renal failure diabetes	No follow-up available

Note.—GTC indicates generalized tonicoclonic seizure.
* Drug free 9 to 11 months before presentation.

buffered formalin and sectioned in the coronal plane. Samples for microscopic analysis were routinely processed for paraffin embedding and stained with hematoxylin-eosin (H and E), H and E–Luxol fast blue, and antibodies to glial fibrillary acidic protein (GFAP), an astrocyte marker.

In one patient (case 9), MR spectroscopy of the basal ganglia was performed using a single-voxel stimulated echo acquisition mode (STEAM) technique with parameters of 2000/30/128 (repetition time/echo time/excitations) and a voxel size of 1.5 × 1.5 × 1.5 mm. Manual shimming was performed and individual parameters were optimized for water suppression. Spectra were analyzed by measuring peak heights and calculating ratios of *N*-acetylaspartate (NAA) to choline (Cho) and creatinine (Cr).

MR imaging was performed as T1-, proton density–, and T2-weighted sequences. In eight of the nine cases, a contrast-enhanced T1-weighted axial series was obtained. The MR images were assessed for location, extent, and signal characteristics of the signal abnormalities, and for the presence of enhancement or mass effect. Inclusion criteria were bilateral, relatively homogeneous, hyperintensity in the putamen and caudate on T2- and proton density–weighted images. The MR images were reviewed independently by two neuroradiologists. Disagreements in interpretations were decided by adjudication or by review by a third neuroradiologist. CT data were similarly reviewed.

Results

Clinical Data

All patients had a prior AIDS-defining illness. A history of illegal drug use was a common feature, found in seven of nine cases; however, one patient reported 9 to 11 months of abstinence preceding admission. Cocaine was the primary drug used in all cases, and three patients supplied the additional history of heroin use. Two patients denied use of illegal drugs. No patient had suffered previous CNS disease or seizures.

Laboratory data included serum toxicology screen in eight cases, which was positive on admission in six patients: three for cocaine alone, one for opiates alone, one for both cocaine and opiates, and one only for quinidine and quinine suggestive of recent opiate or cocaine use. All patients tested positive for HIV, with CD4 T-lymphocyte counts below 200 cells/mm^3 in all patients tested (range, less than 10 to 167) (Table 1). CD4 counts were not available in two cases. All patients had history of non-CNS opportunistic infection. Other laboratory data included negative cryptococcal serology in all cases, and negative results in all five patients who were tested for toxoplasmosis.

Lumbar puncture was performed in all patients. CSF analysis was notable only for an elevated protein concentration (47 to 339 mg/dL) present in all patients. CSF staining for cryptococcus and VDRL, and CSF cultures were negative in all patients.

Blood urea nitrogen and creatinine were mildly increased in one patient and moderately to markedly elevated in six. One patient (case 2) had been previously diagnosed with HIV nephropathy and was undergoing peritoneal dialysis. Serum electrolytes were within normal limits in all cases.

Antiepileptic medication administered during hospitalization controlled seizures in most cases. Clinical follow-up data were available in six cases. One patient was released with partially controlled seizures and was stable 3 months later. The five remaining patients died within 6 months after presentation: one patient (case 6) suffered a rapid deterioration in neurologic status with myelopathy, sensory neuropathy, and dementia, and died during hospitalization 1 month after admission; two patients (cases 2 and 4) died of multiorgan failure caused by end-stage renal disease; one patient (case 5) died of bacterial sepsis; and one patient (case 3) succumbed to sepsis and fungal pneumonia. Autopsies were performed in cases 3 and 6.

TABLE 2: Imaging findings of nine HIV-positive patients

Case	Affected structures			MR Appearance of Other Affected Areas	Signal	Enhancement	Mass Effect	Follow-up MR Findings	CT Appearance
	Putamen	Globus pallidus	Caudate		T1/T2/PD				
1	+	−	+	None	0/↑/↑	−	−	Partial resolution at 3 months	Normal
2	+	+	+	Thalamus	↑/↑/↑	−	+	. . .	Hypodense basal ganglia
3	+	+	+	Thalamus, pons, external capsule, temporal lobe white matter	0/↑/↑	−	+	Minimal resolution at 9 days	Normal
4	+	−	+	Pons	0/↑/↑	−	−	. . .	Normal
5	+	−	+	Pons, external capsule, temporal lobe white matter	0/↑/↑	−	+	Unchanged at 15 days	Hypodense basal ganglia
6	+	−	+	Thalamus, pons, external capsule	↓/↑/↑	−	−	Mild worsening at 23 days	. . .
7	+	−	+	Thalamus	0/↑/↑	. . .	−	. . .	Normal
8	+	−	+	None	↓/↑/↑	−	−	. . .	Normal
9	+	−	+	Thalamus, external capsule	↓/↑/↑	−	−	. . .	. . .

Note.—PD indicates proton density–weighted; +, positive; −, negative; ↓, hypointense relative to gray matter; ↑, hyperintense relative to gray matter; and 0, isointense relative to gray matter.

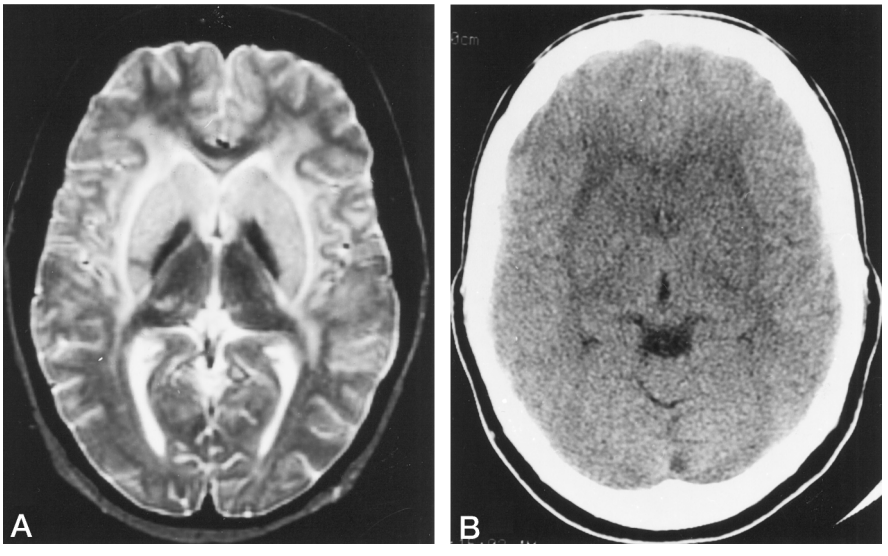

FIG 1. Case 5.
A, T2-weighted (3000/100/0.75) axial MR image shows diffuse bilateral hyperintensity in the putamen and caudate, with sparing of the globus pallidus. Abnormal signal is present in the surrounding white matter.
B, Unenhanced CT scan shows diffuse basal ganglia hypodensity. The presence of mass effect with effacement of the frontal horns is also evident.

Imaging Findings

The putamen and caudate exhibited bilateral hyperintensity relative to gray matter on long-repetition-time images in all cases; the globus pallidus was also involved in two cases (Table 2) (Figs 1–3). Corresponding hypointensity (n = 2), isointensity (n = 5), and mild hyperintensity (n = 1) were observed on T1-weighted images. Additional structures exhibiting abnormal T2 signal included the thalamus in six, pons in four, and other brain stem structures, including the substantia nigra, in one case. T2 hyperintensity extended into the external capsule bilaterally in five patients and further involved the hemispheric (mostly temporal lobe) white matter in two patients. Mass effect was associated with the basal ganglia lesions in three patients. Contrast enhancement was absent in all eight patients who received contrast material.

Findings on noncontrast CT scans of the brain were normal in five of the seven patients who had CT studies; symmetric basal ganglia hypodensity was observed in the remaining two patients (Fig 1).

Follow-up MR data were available in four cases. A repeat MR study in case 3 9 days after the initial study showed mild improvement in signal changes and res-

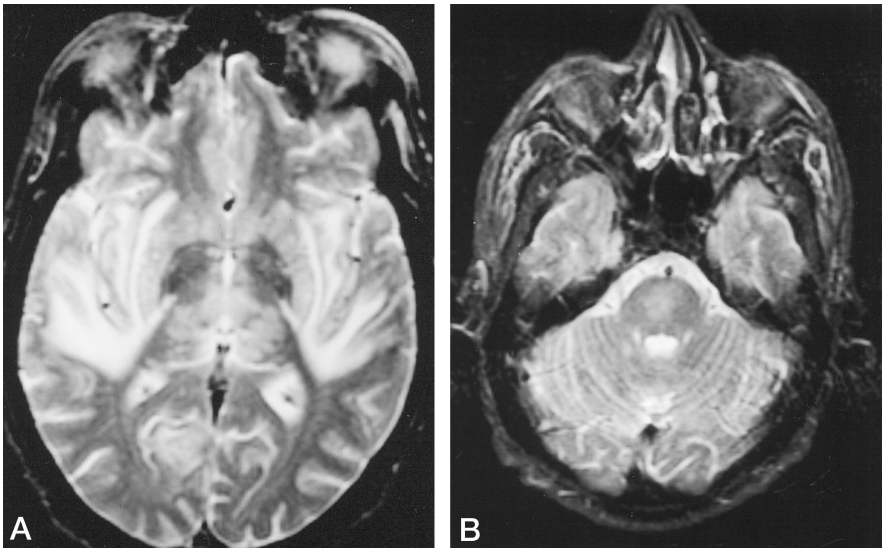

FIG 2. Case 3.
A, T2-weighted (3000/100/0.5) axial MR image shows hyperintensity throughout the putamen and caudate, involvement of the thalamus, and marked symmetric extension of the signal abnormality into the surrounding white matter of the posterior limb of the internal capsule, external capsule, and temporal lobes.
B, Similar signal changes are present in the pons.

olution of mass effect. There was no change in the imaging findings in case 5 upon repeat scan 15 days later. Mild worsening with extension of signal abnormalities into the temporal lobe white matter was found upon repeat MR imaging 23 days after the initial study in case 6. Follow-up MR examination of case 1 at 3 months showed partial resolution of the abnormal T2 hyperintensity in the putamen and caudate.

MR spectroscopic findings in case 9 revealed reduced NAA relative to Cho and Cr in the basal ganglia, consistent with chronic ischemic injury (Fig 4).

Neuropathologic Findings

The neuropathologic analysis of autopsy specimens in cases 3 and 6 showed similar findings. Both specimens were examined after 1 to 2 weeks of fixation in 10% neutral-buffered formalin. Gross examination showed no identifiable lesions or evidence of opportunistic infection. Microscopic analysis of routine sections revealed numerous small foci of disrupted parenchyma in several subcortical structures and the pons. The majority of lesions were located in the caudate nucleus, putamen, and globus pallidus in both cases. Additional lesions were present in the thalamus, amygdala, and basis pontis of both specimens, and in the inferior temporal lobe gray matter in case 6. These foci were characterized by tissue rarefaction, extensive reactive astrocytosis, and varying degrees of macrophage infiltration, consistent with microinfarcts (Fig 3).

Specifically, the cellularity of these lesions ranged from hypocellular foci resembling white matter pallor (Fig 3A) to dense collections of reactive astrocytes (Fig 3B) or foamy macrophages. Other foci more closely resembled classic microglial nodules, yet contained marked astrocytosis not typically found in HIV-related microglial nodules. Tissue degeneration included subtle spongiosus, collections of swollen axons (spheroids), and small cysts filled with macrophages. They involved both gray and white matter, and several lesions were perivascular in location. Both cases lacked multinucleated giant cells (typical of HIV encephalitis), classic microglial nodules, or evidence of opportunistic infections or neoplasms. Mineralization of globus pallidus vessels was found in both cases, similar to the idiopathic mineralization that is occasionally found in elderly persons.

Despite the common features of these findings, each case also had distinguishing features. The caudate lesions in case 3 contained extensive mineralization of neuropil processes, and even an occasional neuron was mineralized. The caudate, putamen, and globus pallidus in case 6 had an extensive generalized astrocytosis in addition to the perilesional reactive astrocytes seen in both cases.

Discussion

The acute presentation of basal ganglia hyperintensity on MR images of nine patients with AIDS is reported. We are aware of one previous report of a similar pattern of T2 hyperintensity in the basal ganglia of two HIV-infected patients, one of whom had a history of intravenous drug abuse (6). It was suggested that this finding may represent an early form of HIV encephalitis. This proposed pathogenesis is not supported by our series, in which all nine patients had prior AIDS-defining illnesses and many had very low CD4 lymphocyte counts, indicative of a relatively late stage of disease. HIV encephalitis is typically an insidious, progressive infection (7), whereas the clinical presentation and evolution of MR lesions in our cases suggest a more acute process. Furthermore, postmortem neuropathologic examination in two cases revealed findings indicative of focal tissue infarction and associated reactive changes in the same brain regions shown to be affected on MR images. The brain tissue examined clearly lacked features of HIV encephalitis, such as multinucleated giant cells. A history of cocaine use was a frequent and notable feature of this group of patients. High metabolic demand and rich vascularity are properties of the basal ganglia (8). Cocaine, which has potent cerebrovascu-

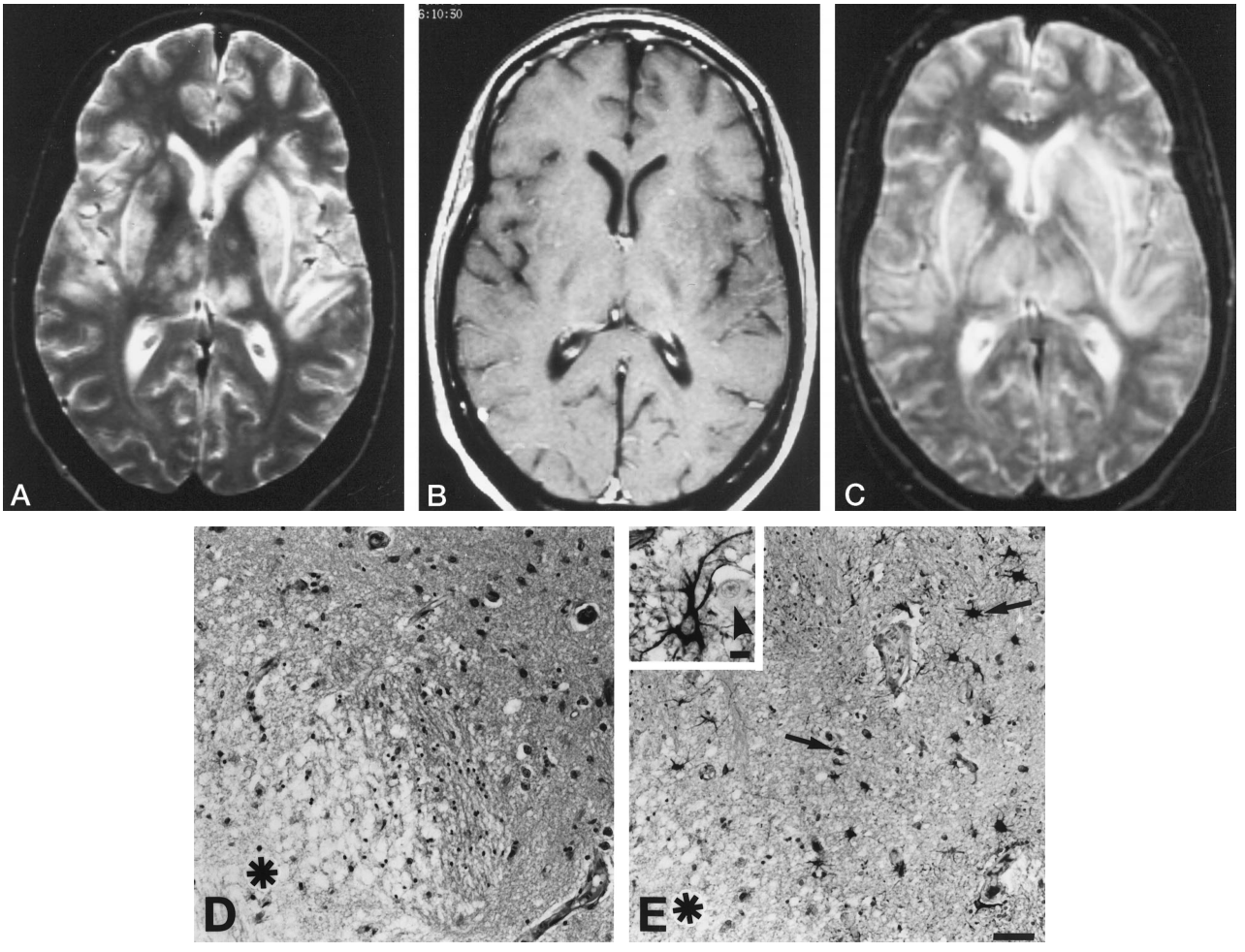

FIG 3. Case 6.

A–C, MR imaging findings. T2-weighted image (3000/100/1) axial MR image (*A*) shows bilateral patchy basal ganglia, thalamic, and white matter hyperintensity. Corresponding contrast-enhanced T1-weighted image (500/32/1) (*B*) shows mild hypointensity in these areas and no evidence of enhancement. A follow-up T2-weighted MR image (3000/100/0.75) 3 weeks later (*C*) shows mild progression of signal abnormalities, particularly an increasing confluence of hyperintensity in the thalami.

D and *E*, Neuropathologic findings. Focal tissue rarefaction (*asterisk*) in the caudate nucleus is indicative of a region of microinfarction. The surrounding tissue adjacent to these regions of microinfarction show reactive changes, manifested by reactive astrocytes in the caudate (*arrows*, *E*) and thalamus (*inset*, *E*), clearly visible when stained by antibodies to GFAP. Note intact thalamic neuron for reference (*arrowhead* in *inset*, *E*). *Bar* in *E*, 50 μm; *bar* in *inset* in *E*, 10 μm (*D*, H and E–Luxol fast blue; *E*, GFAP).

lar effects, may have potentiated disruption of the blood supply to the basal ganglia. Moreover, the presence of renal impairment in six patients in our series may provide an additional contributing factor in the development of this unusual syndrome by reducing clearance of vasoactive substances, such as cocaine, or associated toxic contaminants, such as local anesthetics (9, 10), arsenic (11), and phenytoin (12).

The basal ganglia appear to be preferentially affected in HIV infection. Calcification of the basal ganglia is a common finding in children with AIDS (13), and idiopathic vascular mineralization in the globus pallidus and selective atrophy of the basal ganglia have been reported in HIV-associated dementia (14). High concentrations of HIV viral protein have been reported in the basal ganglia (15). Using positron emission tomography, Rottenberg et al (16) demonstrated selective hypermetabolism in the basal ganglia and thalamus early in the course of the AIDS dementia complex, with progressive hypometabolism

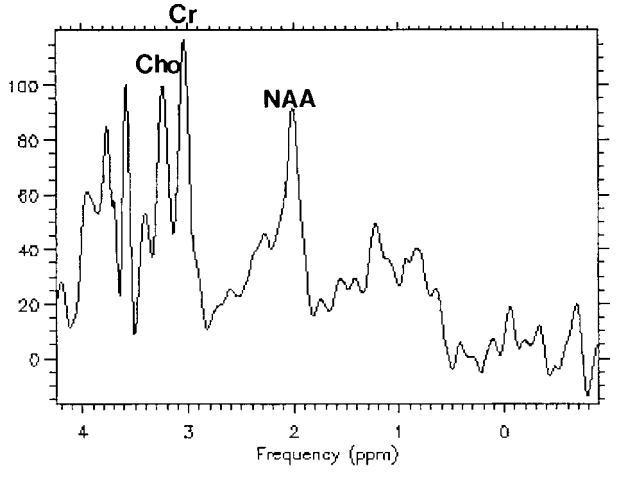

FIG 4. Case 9. MR spectroscopic spectrum (single-voxel STEAM, 2000/30/150; spectral width, 2000 Hz; 2048 data points sampled; voxel size, 1.5 cm^3) sampled from the basal ganglia shows reduced NAA relative to Cho and Cr, a finding consistent with chronic ischemic injury.

in the later stages of disease. Additionally, proton spectroscopic disturbances have been documented in the basal ganglia of children with AIDS, with reduced NAA/Cr ratios similar to that seen in case 9 (Fig 4) found only in those AIDS patients with encephalopathy (17).

Cocaine use has been associated with a variety of CNS complications, including hypertension, infarction, vasculitis, and subarachnoid and intraparenchymal hemorrhage (18, 19). Seizures have been reported subsequent to acute cocaine administration (19). Basal ganglia abnormalities, probably representing infarcts, also have been reported in neonates with a maternal history of cocaine use (20). Single-photon emission CT has demonstrated abnormalities in basal ganglia blood flow in cocaine-dependent subjects (21). These cerebral perfusion defects may be due to the vasoconstrictive properties of the drug and are partially reversible (22). The lack of documentation of drug use in two of our cases suggests that although cocaine may potentiate the basal ganglia hyperintensity syndrome in AIDS, its presence may not be necessary.

Cerebrovascular disease has been reported in AIDS patients (23); however, the mechanism underlying this association remains uncertain, and the frequent coexistence of CNS infections in AIDS patients presenting with cerebral infarction has been observed (23). There is increasing evidence to suggest that the combination of HIV infection and other factors, such as the use of psychoactive drugs, may increase the susceptibility of the brain to injury. Martinez et al (3) found a higher prevalence of HIV encephalopathy among 200 brains of HIV-seropositive patients with a history of intravenous drug abuse (60%) than in patients who were homosexual/bisexual (28%). Augmentation of metabolic alterations in the brains of AIDS patients by concomitant chronic alcohol consumption has been demonstrated using phosphorus-31 spectroscopy (4). Additionally, Gray et al (5) reported dense vascular inflammation in AIDS patients, the majority of whom had died of heroin overdose. HIV-infected macrophages produce a potent cytokine that is toxic to neural tissue (24). This soluble factor has been implicated in the destructive neuropathologic changes found in the brains of two AIDS patients who experienced toxic neurologic reactions to trichosanthin, a ribosome-inactivating protein explored for its ability to inhibit HIV replication in vitro (25). Macrophage-produced factors may potentially predispose brain tissue to further injury from a variety of toxic substances, including cocaine and contaminants commonly found in street drugs. Renal failure and dialysis may further accelerate deposition of toxic metabolic substances in the brain (26). Disruption of the blood-brain barrier at the microscopic level has been described in patients with AIDS dementia (27). If damage to the blood-brain barrier similarly occurred in HIV-seropositive patients without dementia, such substances might leak into, and thus further potentiate damage to, brain tissue.

Conclusions

MR images of the brain in AIDS patients who present acutely with seizures or changes in mental status may show a pattern of bilateral T2 hyperintensity and mass effect within the basal ganglia, with variable involvement of surrounding white matter, thalamus, and brain stem. This MR imaging appearance corresponds to neuropathologic evidence of ischemic tissue injury. We postulate a potential synergistic contribution of a direct HIV effect and vascular disruption related to cocaine use.

Acknowledgments

We thank Jonathan D. Glass for review of autopsy material and helpful discussion, Keith R. Thulborn for review of MR spectroscopic data, and Frank Barksdale for photographic assistance.

References

1. Sharer LR, Cho E-S, Epstein LG. **Multinucleated giant cells and HTLV-III in AIDS encephalopathy.** *Hum Pathol* 1985;16:760
2. Koenig S, Gendelman HE, Orenstein JM, et al. **Detection of AIDS virus in macrophages in brain tissue from AIDS patients with encephalopathy.** *Science* 1986;233:1089–1093
3. Martinez A, Sell M, Mitrovics T, et al. **The neuropathology and epidemiology of AIDS: Berlin experience, a review of 200 cases.** *Pathol Res Pract* 1995;191:427–443
4. Meyerhoff DJ, MacKay S, Sappey-Marinier D, et al. **Effects of chronic alcohol abuse and HIV infection on brain phosphorus metabolites.** *Alcohol Clin Exp Res* 1995;19:685–692
5. Gray F, Lescs M-C, Keohane C, et al. **Early brain changes in HIV infection: neuropathological study of 11 HIV seropositive, non-AIDS cases.** *J Neuropathol Exp Neurol* 1992;51:177–185
6. Kodama T, Numaguchi Y, Gellad FE, Sadato N. **High signal intensity of both putamina in patients with HIV infection.** *Neuroradiology* 1991;33:362–363
7. Chrysikopoulos HS, Press GA, Grafe MR, Hesselink JR, Wiley CA. **Encephalitis caused by human immunodeficiency virus: CT and MR imaging manifestations with clinical and pathologic correlation.** *Radiology* 1990;175:185–191
8. Ho VB, Fitz CR, Chuang SH, Geyer CA. **Bilateral basal ganglia lesions: pediatric differential considerations.** *Radiographics* 1993;13:269–292
9. McKinney CD, Postiglione KF, Herold DA. **Benzocaine-adultered street cocaine in association with methemoglobinemia.** *Clin Chem* 1992;38:596–597
10. Shesser R, Jotte R, Olshaker J. **The contribution of impurities to the acute morbidity of illegal drug use.** *Am J Emerg Med* 1991;9:336–342
11. Lombard J, Levin IH, Weiner WJ. **Arsenic intoxication in a cocaine abuser (letter).** *N Engl J Med* 1989;320:869
12. Katz AA, Hoffman RS, Silverman RA. **Phenytoin toxicity from smoking crack cocaine adulterated with phenytoin.** *Ann Emerg Med* 1993;22:1485–1487
13. Belman AL, Lantos G, Horoupian D, et al. **AIDS: calcification of the basal ganglia in infants and children.** *Neurology* 1986;36:1192–1199
14. Aylward EH, Henderer JD, McArthur JC, et al. **Reduced basal ganglia volume in HIV-1-associated dementia: results from quantitative neuroimaging.** *Neurology* 1993;43:2099–2104
15. Kure K, Weidenheim KM, Lyman WD, Dickson DW. **Morphology and distribution of HIV-1 gp41-positive microglia in subacute AIDS encephalitis.** *Acta Neuropathol (Berl)* 1990;80:393–400
16. Rottenberg DA, Moeller JR, Strother SC, et al. **The metabolic pathology of the AIDS dementia complex.** *Ann Neurol* 1987;22:700–706
17. Lu D, Pavlakis S, Frank Y, et al. **Proton MR spectroscopy of the basal ganglia in healthy children and children with AIDS.** *Radiology* 1996;199:423–428
18. Kaye BR, Fainstat M. **Cerebral vasculitis associated with cocaine abuse.** *JAMA* 1987;258:2104–2106

19. Lowenstein DH, Collins SD, Massa SM, McKinney HE, Benowitz N, Simon RP. **The neurologic complications of cocaine abuse.** *Neurology* 1987;37(Suppl 1):195
20. Dogra VS, Shyken JM, Menon PA, Poblete J, Lewis D, Smeltzer JS. **Neurosonographic abnormalities associated with maternal history of cocaine use in neonates of appropriate size for their gestational age.** *AJNR Am J Neuroradiol* 1994;15:697–702
21. Pearlson GD, Jeffrey PJ, Harris GJ, Ross CA, Fischman MW, Camargo EE. **Correlation of acute cocaine-induced changes in local cerebral blood flow with subjective effects.** *Am J Psychiatry* 1993;150:495–497
22. Holman BL, Mendelson J, Garada B, et al. **Regional cerebral blood flow improves with treatment in chronic cocaine polydrug users.** *J Nucl Med* 1993;31:723–727
23. Engstrom JW, Lowenstein DH, Bredesen DE. **Cerebral infarctions and transient neurologic deficits associated with acquired immunodeficiency syndrome (see comments).** *Am J Med* 1989;86:528–532
24. Pulliam L, Herndier B, Tang N, McGrath M. **Human immunodeficiency virus-infected macrophages produce soluble factors that cause histological and neurochemical alterations in cultured human brains.** *J Clin Invest* 1991;87:503–512
25. Garcia PA, Bredesen DE, Vinters HV, et al. **Neurological reactions in HIV-infected patients treated with trichosanthin.** *Neuropathol Appl Neurobiol* 1993;19:402–405
26. Wills MR. Effects of renal failure. *Clin Biochem* 1990;23:55–60
27. Power C, Kong P-A, Crawford TO, et al. **Cerebral white matter changes in acquired immunodeficiency syndrome dementia: alteration of the blood-brain barrier.** *Ann Neurol* 1993;34:339–350