

Are your **MRI contrast agents** cost-effective?

Learn more about generic **Gadolinium-Based Contrast Agents**.



**FRESENIUS
KABI**

caring for life

AJNR

Parotid pleomorphic adenomas: delayed CT enhancement.

M H Lev, K Khanduja, P P Morris and H D Curtin

AJNR Am J Neuroradiol 1998, 19 (10) 1835-1839

<http://www.ajnr.org/content/19/10/1835>

This information is current as
of April 17, 2024.

Parotid Pleomorphic Adenomas: Delayed CT Enhancement

Michael H. Lev, Kristina Khanduja, P. Pearse Morris, and Hugh D. Curtin

BACKGROUND AND PURPOSE: Weak or absent CT enhancement in pleomorphic adenomas of the parotid gland has been observed immediately after IV contrast administration. This feature can result in poor lesion conspicuity relative to both normal parotid tissue and other parotid abnormalities. The purpose of this study was to document the delayed CT enhancement characteristics of parotid pleomorphic adenomas and to preliminarily compare these results with the enhancement characteristics of other parotid gland tumors.

METHODS: Preoperative CT scans from 18 pathologically proved parotid gland neoplasms were reviewed retrospectively. Lesions included eight pleomorphic adenomas, four Warthin's tumors, two squamous cell carcinomas, two mucoepidermoid cancers, one acinic cell carcinoma, and one melanoma metastasis. In all cases, axial CT was performed after the administration of 100 to 150 mL of IV contrast material, followed by delayed (average, 24 minutes; range, 13 to 34 minutes) coronal CT scanning. The mean normalized Hounsfield unit (HU) attenuation of each lesion was computed by drawing a region of interest around the entire mass and dividing the resulting HU value by that of the contralateral uninvolved parotid gland.

RESULTS: For all eight pleomorphic adenomas, the degree of contrast enhancement increased and became progressively more uniform with time. Mean normalized axial lesion enhancement averaged 1.20 ± 0.35 at 8 minutes, compared with 2.30 ± 0.66 on the coronal scans at 24 minutes. For the 10 nonpleomorphic adenomas, no significant change was found in either the degree or pattern of contrast enhancement between the immediate and delayed CT scans. In these tumors, peak enhancement was reached early, during axial scanning.

CONCLUSION: Delayed CT contrast enhancement is observed in parotid pleomorphic adenomas, increasing in both degree and homogeneity with time. This feature may be useful in selecting an appropriate contrast delay when scanning possible pleomorphic adenomas to improve lesion conspicuity and, potentially, to better distinguish these tumors from other parotid abnormalities.

Both CT and MR imaging are commonly used in the preoperative evaluation of parotid masses. The choice of imaging technique, although sometimes based on such factors as cost or convenience, is more often based on the perception that MR imaging may be more reliable than CT in the detection and delineation of a wide variety of benign and malignant parotid lesions.

Although much has been written about the MR

imaging characteristics of benign parotid pleomorphic adenomas (1–4), the CT characteristics of these tumors have been less rigorously covered in the literature (5–9). The few case reports that have addressed the postcontrast CT appearance of pleomorphic adenomas, although noting the importance of contrast administration for improved lesion definition, have all stressed the heterogeneous enhancement pattern and occasional lack of enhancement typical of these lesions. The enhancement characteristics of pleomorphic adenomas, however, may be a function of the time delay between administration of iodinated contrast material and CT scan acquisition. Our parotid gland CT scanning protocol, in routine clinical use for 3 years, was introduced after the observation by us and other investigators that small pleomorphic adenomas sometimes failed to enhance immediately after administration of IV contrast material but did show conspicuous enhancement on delayed CT scans (10). Our goal in this study, therefore, was to investigate

Received March 19, 1998; accepted after revision August 4.

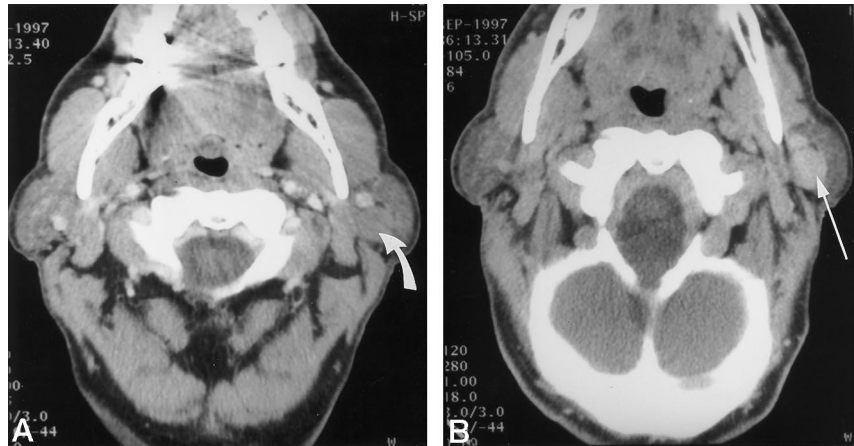
Presented at the annual scientific conference of the American Society of Head and Neck Radiology, Phoenix, April 1998.

From the Massachusetts Eye and Ear Infirmary and Massachusetts General Hospital Harvard Medical School (M.H.L., K.K., H.D.C.), Boston; and Wake Forest University Medical Center, Bowman Gray School of Medicine (P.P.M.), Winston-Salem, NC.

Address reprint requests to Michael H. Lev, MD, Department of Radiology-GRB285, Massachusetts General Hospital, P.O. Box 9657, Boston, MA 02114.

Fig 1. A, Axial CT scan of a parotid adenoma (arrow) 5 minutes after IV administration of contrast material shows no significant enhancement; overall lesion density is less than that of normal contralateral enhancing parotid tissue.

B, By 17 minutes after contrast injection, however, the adenoma has progressed to dense, homogeneous enhancement (arrow).



the delayed postcontrast CT appearance of parotid pleomorphic adenomas. Optimization of the CT scanning protocols used to evaluate parotid masses could potentially aid in their differential diagnosis. Improved timing of contrast administration, if it results in increased lesion conspicuity, might also improve lesion detection and be of value in helping to more easily distinguish parotid adenomas from surrounding normal parotid tissue (Fig 1). In this article, we report the CT contrast enhancement characteristics of parotid pleomorphic adenomas on early and late CT scans.

Methods

Between June 1995 and December 1997, CT scans were obtained in 28 consecutive patients for the preoperative workup of palpable parotid masses. Pathologic proof of diagnosis was found in 18 cases. These included eight pleomorphic adenomas, four Warthin's cell tumors, two squamous cell carcinomas, two mucoepidermoid cancers, one acinic cell carcinoma, and one metastatic melanoma. The pleomorphic adenoma group included two men and six women; patients ranged in age from 30 to 66 years (mean age, 52 years). The nonpleomorphic adenoma group included nine men and one woman; patients ranged from 38 to 82 years (mean age, 60 years).

In all cases, axial CT scans of both parotid glands were acquired after the administration of 100 to 150 mL of IV contrast material, followed by delayed coronal (and in one case, axial) CT scans. Although the precise timing and dose of contrast agent varied minimally from patient to patient, our typical scanning sequence consisted of an initial IV bolus injection of 50 mL, followed, after a 5- to 8-minute delay, by the dynamic injection of the remaining contrast volume at approximately 1 to 2 mL per second. Axial CT was performed during this phase with a 45-second prep delay. Both the initial (axial) and delayed (coronal) CT scans were obtained using the following scanning parameters: 3-mm spiral acquisition reconstructed at contiguous 3-mm intervals, a pitch of 1, 165 to 280 mA, and 120 W. "Time after injection" was defined as the time in minutes between CT scanning and the initial administration of contrast material.

Scans were reviewed visually by two head and neck radiologists who were blinded to the pathologic diagnoses. The degree of parotid lesion enhancement was graded as no enhancement, trace enhancement, mild enhancement, moderate enhancement, or intense enhancement. Pattern of enhancement was graded as heterogeneous, heterogeneous internal enhancement with homogeneous rim enhancement, or homogeneous enhancement.

Additionally, the mean normalized Hounsfield unit (HU) attenuation of each adenoma was computed by drawing a region of interest (ROI) around the entire tumor margin on a representative section through the midportion of the lesion and dividing the resulting HU value by that of a corresponding ROI from the contralateral uninvolved parotid gland. This was performed for both the early and delayed scans.

Statistical analysis was performed using the paired (two-sample for means) *t*-test for the early versus delayed normalized lesion ROI values.

Results

All eight pleomorphic adenomas had distinct margins and ranged in diameter from 0.5 to 3 cm (mean, 1.3 ± 0.46 cm short axis $\times 2 \pm 0.72$ cm long axis). For seven of the eight pleomorphic adenomas, the degree of lesion enhancement increased with time, becoming more uniform and homogeneous, with progression from the tumor margins (Fig 2). Only one of the eight adenomas that had an intense homogeneous enhancement pattern on the initial scan, obtained after an 8-minute delay, failed to show this further filling in of contrast. All adenomas were located in the superficial portion of the parotid gland (one in the tail of the gland). No disagreements were found between the two readers regarding the degree or pattern of contrast enhancement.

Mean early axial lesion enhancement, normalized to that of the contralateral normal parotid tissue, was 1.20 ± 0.35 , at an average time of 8 minutes after contrast administration (range of scan times, 2 to 18 minutes). In comparison, for the delayed coronal scans obtained at an average time of 24 minutes after contrast administration (range of scan times, 13 to 34 minutes), mean normalized adenoma enhancement was 2.30 ± 0.66 ($P < .01$, two-tailed paired [two-sample for means] *t*-test). A scatter plot of lesion enhancement versus time, together with the mean early and delayed ROI values discussed above, is shown in Figure 3.

For nine of the 10 nonpleomorphic adenomas, no significant change was found in either the degree or pattern of contrast enhancement between the early and delayed CT scans (Fig 4). For each of these tumors, peak homogeneous enhancement was reached early, during axial scanning. Only one of the

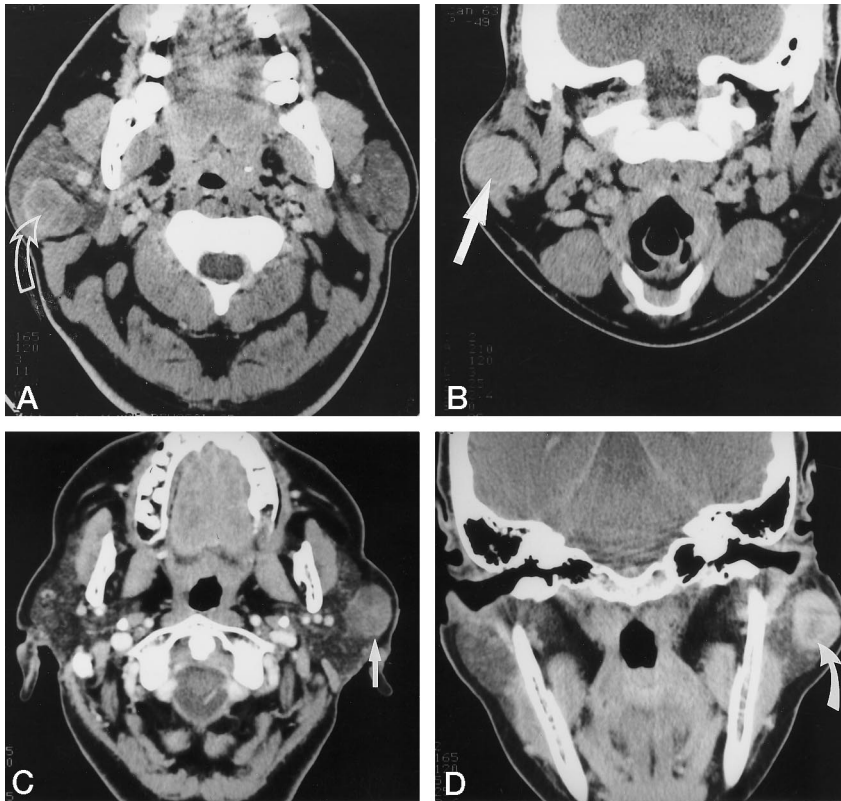


FIG 2. A, Axial CT scan of a typical parotid pleomorphic adenoma, obtained 7 minutes after IV administration of contrast material (arrow). The lesion has distinct margins. Note the thin peripheral rim of enhancement, the slightly reticular pattern of enhancement just deep to this, and the relative lack of central enhancement.

B, Coronal CT scan of the same lesion, obtained after an additional 18-minute delay, shows dense, homogeneous enhancement of the adenoma (arrow).

C, A different case shows similar enhancement characteristics of a pleomorphic adenoma at 2 minutes (arrow).

D, Delayed coronal scan, 23 minutes after contrast injection, shows persistent lack of central enhancement (arrow).

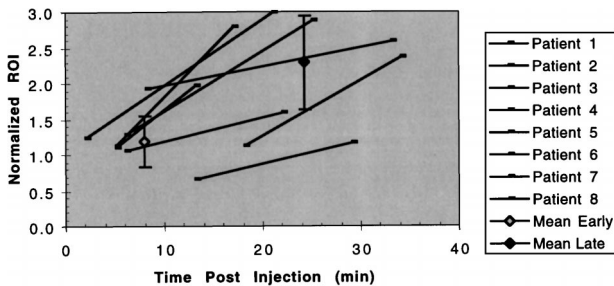


FIG 3. Scatter plot of normalized pleomorphic adenoma lesion ROIs versus time after injection. Mean values of early (axial) enhancement versus late (coronal) enhancement, with error bars indicating ± 1 SD, are included. The position along the time axis reflects the average time after injection of these respective mean values.

10 lesions, a Warthin's tumor, had a slight increase in its proportion of rim enhancement between the early and delayed scans.

The 10 nonpleomorphic adenomas ranged in size from 0.8 to 4 cm, (mean, 1.6 ± 1.0 cm short axis \times 2.1 ± 1.2 cm long axis). All but one of these 10 tumors had distinct margins. The largest lesion, a Warthin's tumor measuring 4×4 cm, had indistinct margins. In another of the Warthin's tumors, the margins became slightly less conspicuous only during the delayed 29-minute scan. Nine of the 10 tumors were located in the superficial portion of the parotid gland (two in the tail of the gland); the large Warthin's tumor had both superficial and deep components. No disagreements were found between the two readers regarding the degree or pattern of contrast enhancement.

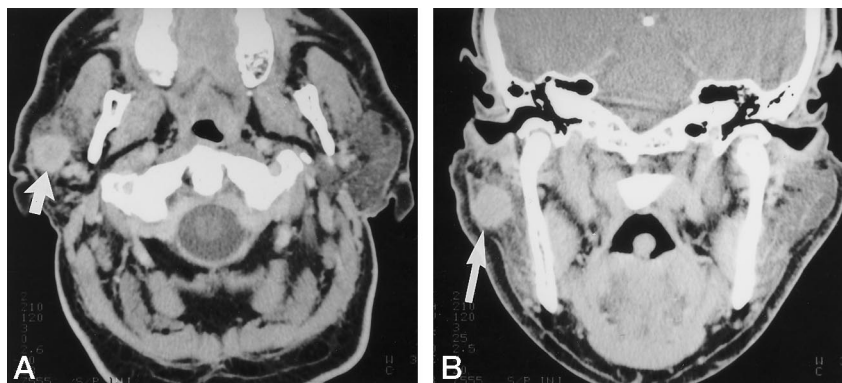
Mean early axial tumor enhancement, normalized

to the contralateral normal parotid tissue, was 3.95 ± 2.15 , at an average time of 8 minutes after contrast administration (range of scan times, 3 to 16 minutes), compared with 4.25 ± 3.36 for the delayed coronal scans obtained at an average time of 30 minutes after contrast administration (range of scan times, 22 to 60 minutes) (P , not significant [$P = .41$, one-tailed t -test; $P = .81$, two-tailed t -test]). For two of the four Warthin's tumors, including the largest (a 4×4 -cm lesion), normalized lesion enhancement was relatively low (approximately 1.5 for both the early and delayed scans).

Discussion

Pleomorphic adenoma, also known as benign mixed tumor, is the most common salivary gland tumor, representing 70% to 80% of all benign salivary tumors. Approximately 85% of these tumors occur in the parotid gland (2). Clinically, parotid pleomorphic adenoma usually occurs in patients between the ages of 30 and 50 years as a slow-growing painless mass. The rate of occurrence is slightly higher in women than in men; the tumor is unusual in children (9). The lesions are composed of epidermoid and myoepithelial cells (3). Dystrophic calcifications are occasionally present. Although malignant degeneration has been reported to be as low as 2% to 5%, by some accounts, up to 25% of pleomorphic adenomas, left untreated, will undergo malignant transformation to carcinoma ex pleomorphic adenoma (2, 11). Because of this high rate of development of carcinoma ex pleomorphic adenoma, pleomorphic adenomas must be completely

FIG 4. A and B, Early (8 minutes after injection) axial contrast-enhanced CT scan of a typical nonpleomorphic adenoma parotid gland tumor, in this case, a mucoepidermoid tumor (A), and delayed (20 minutes after injection) coronal contrast-enhanced scan both show dense homogeneous pattern of enhancement (arrows).



resected. If their capsule is completely removed, these tumors can be completely cured by surgery. Biopsy without resection may increase the risk of recurrence (1).

In contrast to the scant literature regarding the CT appearance of parotid adenomas, the MR imaging findings characteristic of pleomorphic adenomas have been well described. Often cited are a markedly hyperintense T2 signal relative to that of CSF and a well-defined capsule. As opposed to the high T2 signal found in the cystic regions of other benign tumors, the hyperintense T2 components of pleomorphic adenomas more usually enhance with contrast administration (4). In one MR study, a lobulated contour and a low-signal capsule on T2-weighted images were found to characterize most pleomorphic adenomas. The finding of a complete capsule together with a lobulated contour had a positive predictive value of 100% (1). In another MR study, the majority of pleomorphic adenomas were homogeneous and smoothly marginated (3). Warthin's tumors were equally well marginated, but more heterogeneous in appearance. Malignant and inflammatory parotid masses were associated with both lymphadenopathy and subcutaneous stranding of fat.

The typical CT appearance of parotid pleomorphic adenoma has been reported as that of a smoothly marginated or lobulated small spherical tumor. Pleomorphic adenomas have also been described as not significantly enhancing, with larger masses often having a nonhomogeneous appearance characterized by low-attenuation central foci of necrosis, old hemorrhage, and cystic change (2, 5–9). Other benign or malignant lesions, however, may also have these imaging characteristics. Only 10% of parotid pleomorphic adenomas are reported to occur in the deep gland (11). Normal adult parotid gland parenchyma is relatively fatty, with a reticular interstitium. The usual glandular CT density of 15 to 25 HU is lower than that of muscle, but greater than that of fat (12). Some glands are denser, with lower fat, which can decrease the conspicuity of soft-tissue-density lesions within the gland.

Studies reporting the immediate postcontrast appearance of parotid pleomorphic adenomas have concluded that CT may be inferior to MR imaging for depicting lesion margins (3, 5, 7, 9). CT enhancement

of pleomorphic adenomas was described, in one report, as “an inhomogeneous (reticulated) pattern” in a majority of cases (7). In a different study, the authors concluded that to “detect the relation between the tumor and carotid sheath, . . . the images of CT sialography are much better than those of plain CT and intravenous enhancement CT” (5). Another case report described a parotid pleomorphic adenoma that mimicked multiple parotid masses on contrast-enhanced CT scans but that MR imaging revealed to be a single lesion (8). In none of the above examples were delayed postcontrast CT scans obtained.

Our results regarding the average size, margin appearance, and location within the parotid gland typical of parotid pleomorphic adenomas are concordant with those of the literature. Our finding of delayed pleomorphic adenoma enhancement, however, with an increasingly homogeneous filling in of contrast material, has not, to our knowledge, been emphasized previously. This observation may explain some of the differing descriptions of the CT enhancement pattern of parotid pleomorphic adenomas discussed above. As shown in Figure 1, parotid CT performed too early after IV administration of contrast material could result in markedly decreased lesion conspicuity. The fact that the other parotid masses we examined overwhelmingly showed early intense contrast enhancement may potentially be of value in formulating the differential diagnosis, although further work is required to substantiate this hypothesis.

Until more extensive series are performed, it is too early to tell whether the finding of delayed parotid pleomorphic adenoma enhancement will aid in clinical management. Awareness of this feature, however, if it improves diagnostic certainty, could influence the decision to perform fine-needle aspiration biopsy. Current indications for fine-needle aspiration biopsy vary by surgeon and by center. At many institutions, fine-needle aspiration biopsy of potential pleomorphic adenomas is thought to be unnecessary and is not routinely performed (13). Excisional biopsy is preferred for lesions presenting as typical pleomorphic adenomas; needle biopsy is reserved for patients in whom clinical or imaging findings are atypical or suggestive of malignancy (13). If the finding of delayed contrast enhancement does improve diagnostic certainty for what is a typical pleomorphic adenoma,

fewer fine-needle aspiration biopsies may be necessary. In those cases in which the procedure is indicated, however, the possibility of improved lesion conspicuity through delayed enhancement might also be an asset in the performance of CT-guided biopsy.

Conclusion

Delayed CT enhancement is found in pleomorphic adenomas of the parotid gland, with an increasingly homogeneous filling in of contrast material with time. This finding may be useful in selecting the appropriate timing of contrast administration when evaluating potential parotid adenomas.

References

- Ikeda K, Tsutoma K, Ha-Kawa S, et al. **The usefulness of MR in establishing the diagnosis of parotid pleomorphic adenoma.** *AJNR Am J Neuroradiol* 1996;17:555-559
- Som PM, Brandwein M. **Salivary glands.** In: Som PM, Curtin HD, eds. *Head and Neck Imaging*. 3rd ed. St Louis: Mosby; 1995: 879-882
- Swartz JD, Rothman M, Marlowe F, Berger A. **MR imaging of parotid mass lesions: attempts at histopathologic differentiation.** *J Comput Assist Tomogr* 1989;13:789-796
- Tsushima Y, Matsumoto M, Endo K, et al. **Characteristic bright signal of parotid pleomorphic adenomas on T2-weighted MR images with pathological correlation.** *Clin Radiol* 1994;49:485-489
- Guang-yan Y, Zhao-ju Z, Yi-sheng W. **Computed tomography of parotid masses.** *Chin Med J* 1989;102:243-250
- Horii A, Honjo Y, Nose M, Ozaka M, Yoshida J. **Accessory parotid gland tumor: a case report.** *Auris Nasus Larynx* 1997;24:105-110
- Bogaert J, Hermans R, Baert AL. **Pleomorphic adenoma of the parotid gland.** *J Belge Radiol* 1993;76:307-310
- Som P, Shugar J, Sacher M, Stollman A, Biller H. **Benign and malignant pleomorphic adenomas: CT and MR studies.** *J Comput Assist Tomogr* 1988;12:65-69
- Mirich D, McArdle C, Kulkarni M. **Benign pleomorphic adenomas of the salivary glands: surface coil MR imaging versus CT.** *J Comput Assist Tomogr* 1987;11:620-623
- Hudgins P. **Spiral CT applications of the head and neck.** In: *Proceedings of the Annual Meeting of the American Society of Head and Neck Radiology and the International Congress of Head and Neck Radiology*. Washington, DC: 1994:91-93
- Batsakis JG. *Tumors of the Head and Neck: Clinical and Pathological Considerations*. 2nd ed. Baltimore: Williams & Wilkins; 1979: 21-30
- Batsakis J, Chinn E, Weimert T, et al. **Acinic cell carcinoma: a clinico-pathologic study of 35 cases.** *J Laryngol Otol* 1979;93: 325-340
- Johnson JT, Myers EN, Curtin HD. **Tumors of the parapharyngeal space.** In: Myers EN, Suen JY, eds. *Cancer of the Head and Neck*. New York: Churchill Livingstone; 1989:680-681