

Are your MRI contrast agents cost-effective?

Learn more about generic **Gadolinium-Based Contrast Agents**.



AJNR

Stenting of symptomatic stenosis of the intracranial internal carotid artery.

N Al-Mubarak, C R Gomez, J J Vitek and G S Roubin

AJNR Am J Neuroradiol 1998, 19 (10) 1949-1951

<http://www.ajnr.org/content/19/10/1949>

This information is current as of December 3, 2024.

Stenting of Symptomatic Stenosis of the Intracranial Internal Carotid Artery

Nadim Al-Mubarak, Camilo R. Gomez, Jiri J. Vitek, and Gary S. Roubin

Summary: Percutaneous balloon angioplasty has been reported to be useful in the treatment of intracranial atherosclerotic arterial stenoses; however, arterial dissection with increased risk of stroke has limited its widespread implementation. Although vascular stenting has improved the outcome of similar procedures in the extracranial vasculature, its intracranial application has been limited by the lack of suitable stents. We report a case of successful percutaneous stenting of a symptomatic intracranial carotid artery using a second-generation, flexible, coronary stent.

The application of percutaneous balloon angioplasty to the treatment of intracranial atherosclerotic arterial stenosis has been tempered by the increased risk of stroke resulting from distal embolization, vessel dissection, or arterial rupture (1, 2). Stenting has been shown to increase the safety and efficacy of balloon angioplasty in the treatment of extracranial carotid artery atherosclerosis (3–6). Nevertheless, stenting of intracranial atherosclerotic lesions has been limited by the lack of stents suitable for this purpose. We describe the successful treatment of a symptomatic intracranial carotid artery atherosclerotic lesion with the use of a second-generation, balloon-expandable, flexible, coronary stent.

Case Report

A 59-year-old man had had multiple episodes of transient right arm paralysis for 4 months, despite treatment with aspirin and optimal doses of warfarin. Findings at a neurologic examination performed between episodes were normal, and an extensive cardiac evaluation did not reveal any other potential sources of embolization. Digital subtraction cerebral angiography showed a severe, diffuse, and ulcerated lesion of the petrous and precavernous segments of the left internal carotid artery (Fig 1A and B). Because of the continued recurrence of symptoms despite optimal anticoagulation therapy, the option of percutaneous angioplasty with stenting was discussed with the patient as part of a protocol approved by the local institutional review board.

Percutaneous access was obtained via the right femoral artery. The left common carotid artery was engaged with a 5F catheter, which was directed into the artery over a 0.038-inch

hydrophilic-coated wire. After obtaining a preliminary angiogram, the 5F catheter was exchanged for an 8F multipurpose guiding catheter, which was positioned just proximal to the common carotid bifurcation. Preprocedural angiographic images were then obtained in the orthogonal plane (Fig 1). The lesion was crossed with an exchange-length, hydrophilic-tipped coronary wire, the tip of which was positioned in the middle cerebral artery to ensure maximum wire support. The stenosis was then predilated with a 2.5 × 20-mm coronary balloon catheter at 6 atm for 20 seconds. Online quantitative angiography after balloon inflation showed reduction of the stenosis from 88% to 57% (Fig 1C and D). A second-generation coronary stent (GRII, Cook Cardiology, Bloomington, IN) was then successfully deployed over the wire (Fig 1E and F). The 100-cm-long guiding catheter had to be advanced into the internal carotid artery in order for the stent system to reach the lesion. Final quantitative angiography showed further reduction of the stenosis to 8%, with resolution of the dissection (Fig 1G and H). No neurologic events occurred during the procedure or in the postoperative period prior to discharge. The patient had been premedicated with aspirin and ticlopidine, both of which were continued for 4 weeks, after which, he was treated only with aspirin (325 mg/day). At follow-up, 3 months later, he reported no recurrence of neurologic symptoms.

Discussion

Percutaneous transluminal angioplasty is a well-established technique for the treatment of atherosclerotic lesions of the coronary, iliac, and renal arteries. Its use in the cerebral vessels, however, has been tempered by concerns of distal embolization of plaque material, dissection, or vessel rupture (1, 2). More recently, adjunctive stenting has proved to be useful in treating vascular dissections. Theoretically, stenting improves acute and long-term patency and minimizes the risk of distal embolization by trapping plaque material between the stent and the vessel wall (3–6). Several reports have described the safety and efficacy of extracranial carotid stenting with low mortality and stroke rate and favorable long-term patency (3–6). Despite these advances, the use of stents to support angioplasty of the intracranial arteries has not been feasible, largely because of the inability of existing stents to track well into the cranial portion of the vasculature.

Received October 7, 1997; accepted after revision April 6, 1998.

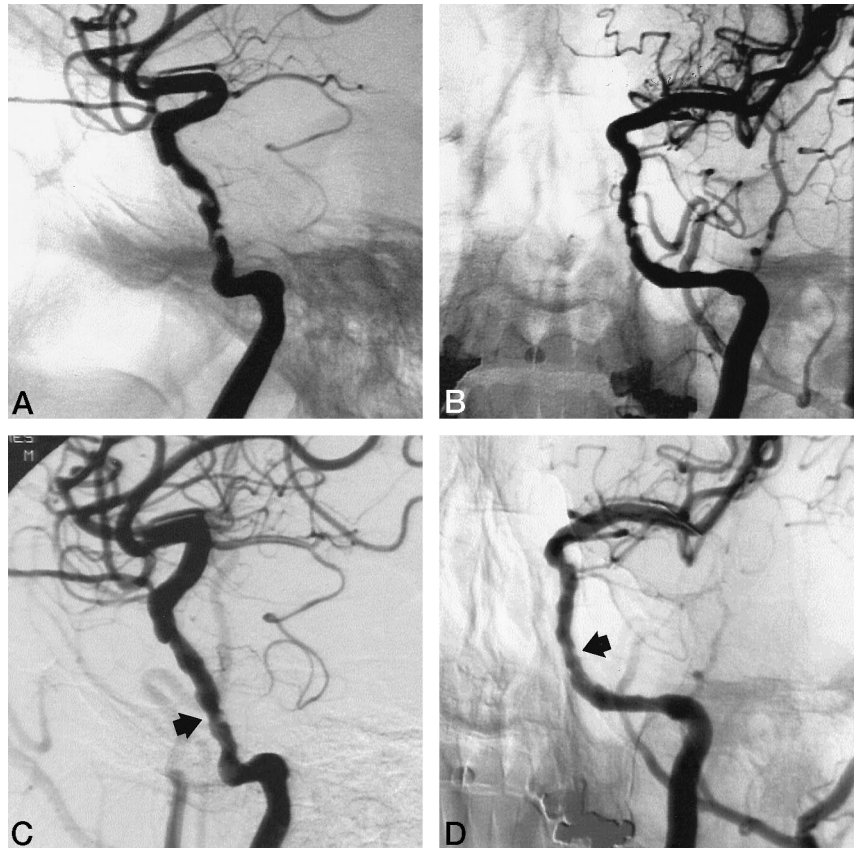
From the Departments of Internal Medicine, Division of Cardiovascular Diseases (N.A.-M., G.S.R.), Neurology (C.R.G.), and Radiology (J.J.V.), The University of Alabama at Birmingham.

Address reprint requests to Camilo R. Gomez, MD, Comprehensive Stroke Center, 1202 Jefferson Tower, 625 S 19th St, Birmingham, AL 35294.

FIG 1. 59-year-old man with 4-month history of multiple episodes of transient right arm paralysis.

A and B, Lateral and anteroposterior views of stenotic petrous and precavernous portions of the left internal carotid artery.

C and D, Lateral and anteroposterior views of the vessel after balloon angioplasty show recoil of the stenotic lesion (arrows).

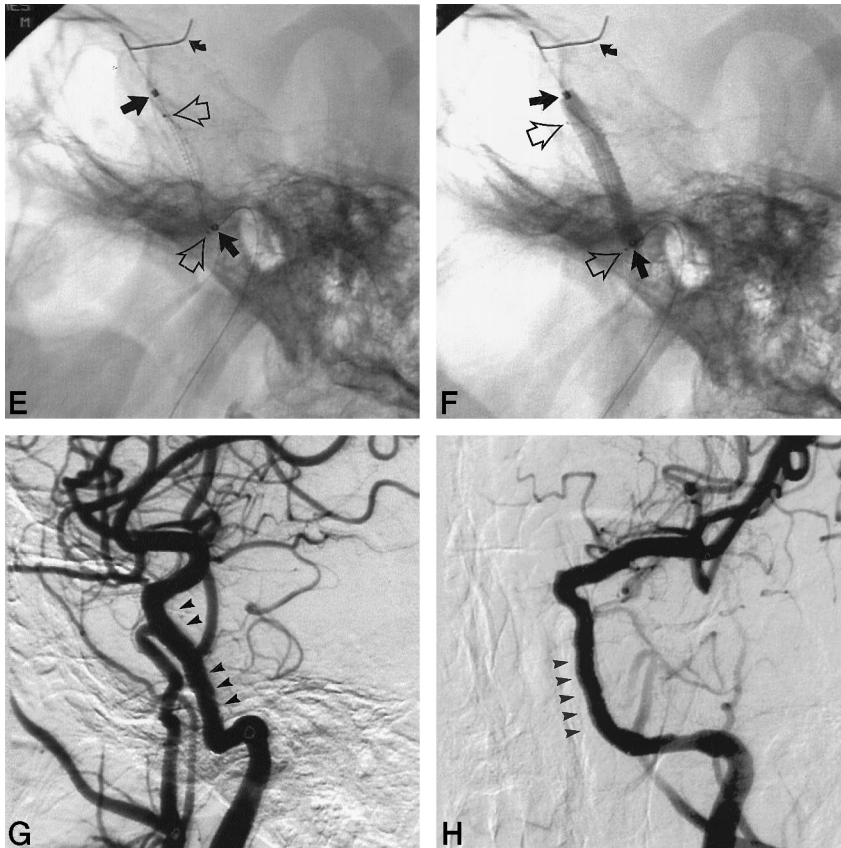


Feldman et al (7) successfully deployed a balloon-expandable coronary stent across a petrous internal carotid artery. The lesion in their patient was more proximal and was located in a larger (>4.5-mm diameter) and less tortuous portion of the vessel. The stented segment was shorter than that in our patient. Nevertheless, these investigators faced similar difficulty in trying to reach the lesion using a regular-length guiding catheter stent delivery system, having to advance these to a point within the common carotid bifurcation (7). They recognized the need for a shorter guiding catheter and a more trackable stent to be able to treat intracranial lesions efficiently. The present report establishes the feasibility of stenting small, more distal, and tortuous intracranial arterial segments using a low-profile, more flexible, and highly trackable stent. We chose the GR II stent because of previous difficulties in getting other available stents to track into the intracranial cavity.

The maturity of interventional cardiovascular techniques and the considerably advanced equipment used in this field significantly contributed to the success of the procedure. The guidewire used has a hydrophilic-coated soft tip, allowing it to be placed in the distal intracranial vasculature while providing adequate support for stent deployment. The balloon used has a low profile, is moderately compliant, and is highly trackable, making it capable of reaching even the distal middle cerebral artery. The design of the GR II stent, including its low profile, flexibility, and high trackability, may have significantly influenced its

successful deployment in the intracranial portion of the internal carotid artery. The GR II consists of a flat coil stent with a single longitudinal strut. This combination allows it to maintain the position of the coils and confers its flexibility. The only potential limitation of the technique described relates to the potentially low radial strength of the GR II stent. This is not critical in the precavernous or cavernous portions of the internal carotid artery, but it may become a problem in the treatment of lesions in its petrous portion, where the vessel walls are surrounded by bone. This vascular environment may limit the outward expansion of the arterial wall during angioplasty, and may lead to stent collapse after deployment. If this were to be followed by acute stent closure, the need to permanently occlude the internal carotid artery may become an issue. In this case, prior assessment of the collateral capabilities of the circle of Willis would be indispensable and should guide any attempts at bailout. At the time this patient was treated, the remaining available stents would not have been useful in the event of a complication of that nature. At present, new stents are rapidly being introduced into the market. It is likely that some of these will further facilitate the treatment of intracranial lesions.

The demonstration of carotid endarterectomy as an effective method for reducing the risk of stroke in patients with significant extracranial atherosclerotic carotid artery lesions has made carotid revascularization the standard of care for these patients (8). However, for patients whose lesions are not readily acces-



E and *F*, Lateral views show deployment of the GR11 stent. A 0.014-inch wire is anchored in the left middle cerebral artery (curved arrows). Markers at the end of the deployment balloon (straight solid arrows) are distinguishable from markers of the stent (open arrows).

G and *H*, Lateral and anteroposterior views of the vessel after stenting show the segment in which the stent was deployed (arrowheads).

sible to surgery, medical therapy has been the only therapeutic option. It seems intuitive that angioplasty represents a feasible solution for effective reduction of stroke risk in these patients, yet the inherent risk of vessel dissection, distal embolization, or rupture has limited its widespread use.

Conclusion

Our case shows that stenting may improve the results of endovascular treatment of lesions in the intracranial segments of the carotid artery, as has been the case in its extracranial segments. Nevertheless, it has not been until recently that newly designed suitable stents have become available. Still, the future awaits further experience for better definition of the role of stenting in the treatment of intracranial carotid atherosclerotic lesions.

References

1. Purday PD, Devous MD Sr, Unwin DH, et al. **Angioplasty of an atherosclerotic middle cerebral artery associated with improvement in regional cerebral blood flow.** *AJNR Am J Neuroradiol* 1990;11:878-880
2. Clark WM, Barnwell SL, Nesbit G, et al. **Safety and efficacy of percutaneous transluminal angioplasty for intracranial atherosclerotic stenosis.** *Stroke* 1995;26:1200-1204
3. Roubin GS, Yadav S, Iyer SS, et al. **Carotid stent-supported angioplasty: a neurovascular intervention to prevent stroke.** *Am J Cardiol* 1996;78:8-12
4. Theron J. **Protected carotid angioplasty and carotid stents.** *J Mal Vasc* 1996;21(Suppl A):113-122
5. Yadav J, Roubin G, King P, et al. **Angioplasty and stenting for restenosis after carotid endarterectomy: initial experience.** *Stroke* 1996;27:2075-2079
6. Yadav JS, Roubin GS, Iyer S, et al. **Elective stenting of the extracranial carotid arteries.** *Circulation* 1997;95:376-381
7. Feldman RL, Trigg L, Gaudier J, et al. **Use of coronary Palmaz-Schatz stent in the percutaneous treatment of an intracranial carotid artery stenosis.** *Cathet Cardiovasc Diagn* 1996;38:316-319
8. North American Symptomatic Carotid Endarterectomy Trial Collaborators. **Beneficial effect of carotid endarterectomy in symptomatic patients with high-grade carotid stenosis.** *N Engl J Med* 1991;325:445-453