

Are your **MRI contrast agents** cost-effective?

Learn more about generic **Gadolinium-Based Contrast Agents**.



**FRESENIUS
KABI**

caring for life

AJNR

Percutaneous laser photocoagulation of spinal osteoid osteomas under CT guidance.

A Gangi, J L Dietemann, S Guth, L Vinclair, J Sibia, R Mortazavi, J P Steib and C Roy

AJNR Am J Neuroradiol 1998, 19 (10) 1955-1958

<http://www.ajnr.org/content/19/10/1955>

This information is current as of May 21, 2024.

Percutaneous Laser Photocoagulation of Spinal Osteoid Osteomas under CT Guidance

Afshin Gangi, Jean-Louis Dietemann, Stephan Guth, Laurent Vinclair, Jean Sibilia, Reza Mortazavi, Jean Paul Steib, and Catherine Roy

BACKGROUND AND PURPOSE: Spinal osteoid osteomas are rare; when they occur, they are usually treated by surgical or percutaneous excision. The aim of percutaneous interstitial laser photocoagulation (ILP) of osteoid osteomas under CT guidance is thermal destruction of the nidus using low-power laser energy, thus precluding bone resection and open surgery.

METHODS: Three cases of spinal osteoid osteomas were treated with percutaneous ILP of the nidus. Under CT guidance, the needle was positioned in the center of the nidus, at least 8 mm from neurologic structures. Using a high-power semiconductor diode laser (805 nm) with a 400- μ m optical fiber, we delivered 600 to 800 joules to the nidus, depending on its size. The procedure was performed with the patient under neuroleptanalgesia and required overnight hospitalization.

RESULTS: Complete pain relief was obtained in all three patients within 24 hours of the procedure, and no major complications were incurred. Follow-up ranged from 20 months to 60 months.

CONCLUSION: Percutaneous ILP of spinal osteoid osteoma is a promising, simple, precise, and minimally invasive technique and may be an alternative to traditional surgical and percutaneous ablations.

Osteoid osteoma is a benign bone lesion with distinctive radiologic and clinical characteristics. Vertebral osteoid osteomas are rare (6%) and usually arise from the posterior elements, with the base of the transverse process, the lamina, and the pedicle being the most common sites (1–3). Conventional treatment of osteoid osteoma is surgical or percutaneous excision of the nidus. Promising results have been obtained with percutaneous radio-frequency ablation (4, 5). Interstitial laser photocoagulation (ILP) is a new technique based on in vitro and experimental animal studies. These investigations have shown promising results, with the production of well-demarcated coagulations (thermal necrosis) of predictable size in solid tissue with the use of a low-power laser technique (6). Optical fibers are inserted percutaneously into the tumors, which are then coagulated and destroyed by direct heating. This technique has

been applied clinically to treat tumors of the liver, pancreas, prostate, brain, breast, and lymph nodes (7–12).

Experimental work has shown that a reproducible, well-defined area of coagulative necrosis is obtained around the precharred fiber tip in bone, with good correlation between energy delivered and lesion size (13). Carbonization of the fiber tip before ILP (pre-charring) makes the effect more predictable. The temperatures at 8 mm around the fiber tip exceed the threshold for osteocyte necrosis (50°C) at 1000 to 1200 joules (13). The extent of thermal necrosis depends on the laser wavelength, the energy deposited, the power used (tip temperature), the thermal and optical properties of the target tissue, and the type of optical fiber used (6, 9). The size of osteoid osteomas falls within the range of those that can be effectively coagulated, and the nidus can be identified precisely on CT scans. The transmission of heat within bone is sharply limited by blood flow and by the fact that high temperatures cannot be sustained over great distances (13–15).

The purpose of this study was to evaluate percutaneous ILP of spinal osteoid osteomas under CT guidance with the use of low-power laser energy as a means of effecting thermal destruction of the nidus without bone resection and open surgery.

Received April 21, 1998; accepted after revision August 25.

From the Departments of Radiology (A.G., J-L.D., S.G., L.V., C.R.), Rheumatology (J.S.), Anesthesiology (R.M.), and Orthopedic Surgery (J.P.S.), University Hospital of Strasbourg, Strasbourg, France.

Address reprint requests to Afshin Gangi, MD, PhD, Department of Radiology B, University Hospital of Strasbourg, 1, place de l'hôpital, Strasbourg 67091, France.

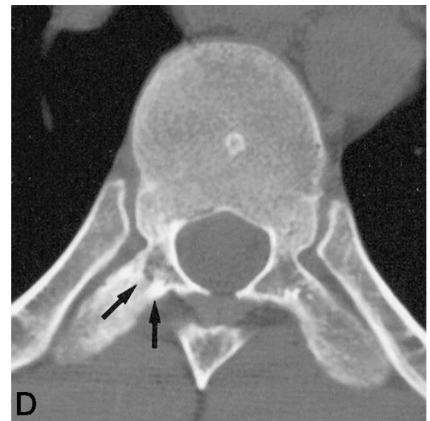
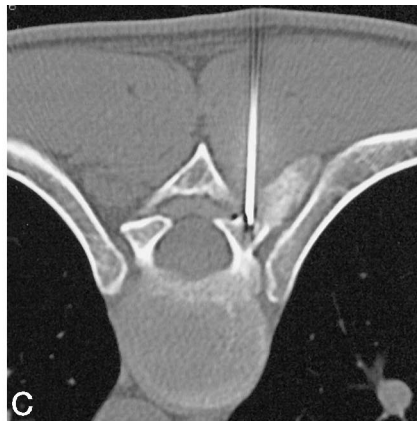
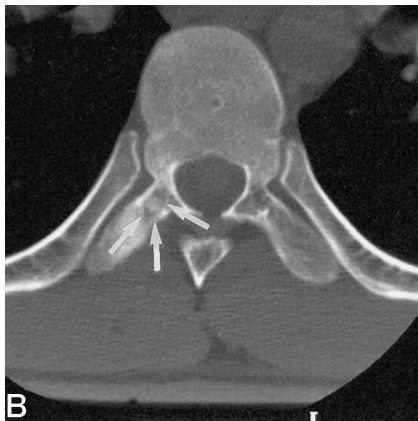
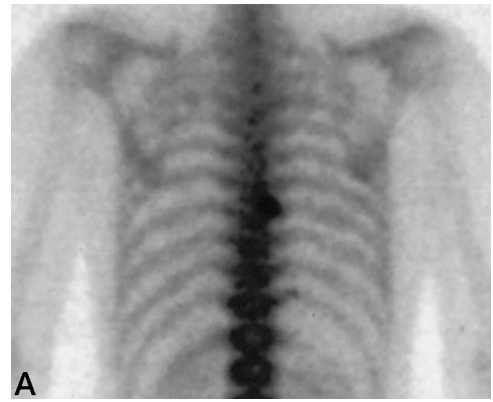
FIG 1. 25-year-old man with back pain for 18 months, which was dramatically relieved by aspirin. Radiographic findings were normal.

A, Bone scintigram shows an area of increased activity in the transverse process of T8.

B, CT scan shows a lucent area in the right transverse process (arrows) of T8 with a small focus of calcification within it. Sclerosis surrounding the lesion was noted and a diagnosis of osteoid osteoma was suggested.

C, Under CT guidance, an 18-gauge spinal needle was placed by a posterior approach in the center of the nidus. A 400- μ m fiber was introduced into the lesion through the canula of the spinal needle.

D, Follow-up CT scan obtained 21 months after the procedure shows replacement of the lucent area (nidus) by a normal medullary cavity (arrows).



Summary of Patients Who Underwent Percutaneous Interstitial Laser Photocoagulation of Spinal Osteoid Osteomas

Case	Age (y)/ Sex	Nidus Location/ Region	Nidus Size (mm)	Distance to Nearest Neural Structure (mm)	Needle Type/Gauge	Energy Deposited (joules)	After Treatment		
							Pain Relief/ Time Required (days)	Follow-up (mo)	Recurrence
1	26/F	Sacrum laminae/cortex	5	10	Ostycut/14	600	Complete/1	60	No
2	25/M	Transverse process T8/ medullary cavity	5	8	Spinal/18	600	Complete/1	32	No
3	27/M	Articular process C3/ cortex	7	12	Spinal/18	800	Complete/1	20	No

Methods

From June 1993 to February 1998, we encountered four cases of spinal osteoid osteoma. Percutaneous ILP guided by CT (Fig 1) was performed in three patients (two men and one woman, 25 to 27 years old). Nidus location and patient data are reported in the Table. One patient with osteoid osteoma of the lamina was not treated with ILP. In this case, the distance between the nidus and dura mater was only 3 mm, and the risk of neurologic damage was high (Fig 2). ILP was not performed if doubt persisted as to the diagnosis of osteoid osteoma or if the nidus was too near neurologic structures (the center of the nidus must be positioned at least 8 mm from dura mater and/or nerve roots) (Fig 3). The temperature at 8 mm around the fiber tip exceed 50°C at 1000 to 1200 joules (13).

Patients with spinal osteoid osteoma were hospitalized for 1 night after the procedure. ILP was performed by using a continuous-wave semiconductor portable diode laser (Diomed 25 laser, Cambridge, UK) with a wavelength of 805 nm. A sterilized, single, freshly cleaved, 400- μ m fiber with polymer cladding was used with a bare tip to deliver laser energy to the tumor (7, 13).

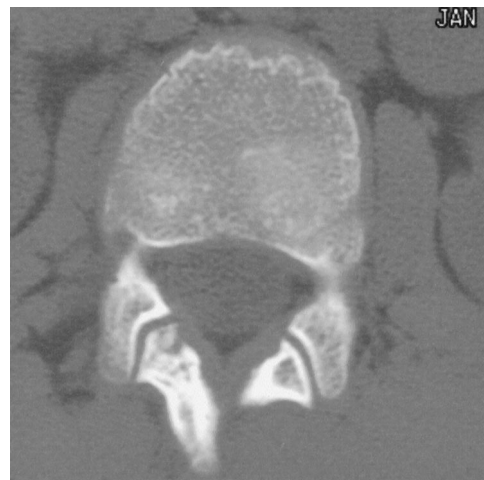

FIG 2. CT scan obtained in a 12-year-old boy shows an osteoid osteoma of the lamina. ILP was rejected because the nidus was too near the dura matter.

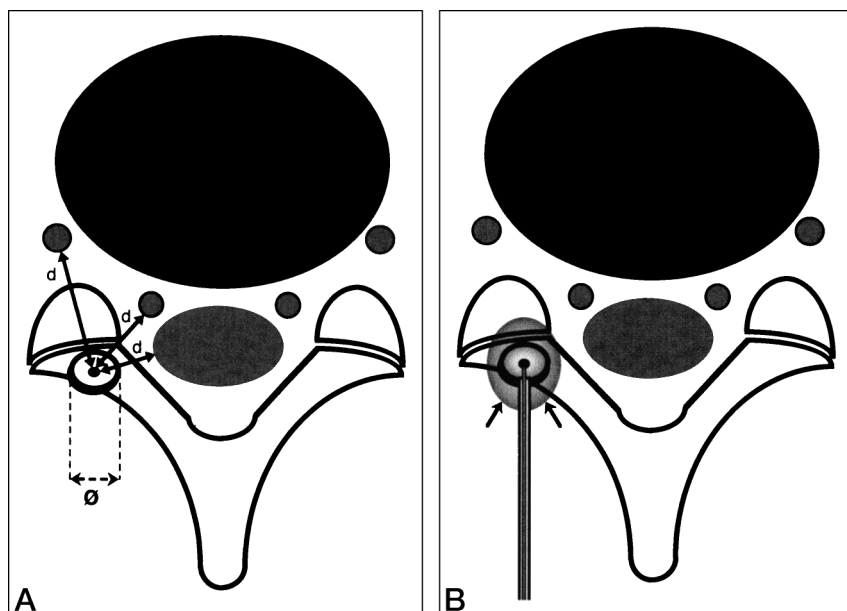


FIG 3. Drawings show the technique of measurements and coagulation of spinal osteoid osteoma.

A, Osteoid osteoma of the lamina. The largest diameter (l) of the nidus is measured to determine the energy necessary to coagulate the tumor. The distance (d) from the center of the nidus to neural structures and dura matter is measured. A distance of at least 8 mm is mandatory to avoid neural damage, particularly in front of the fiber.

B, Introduction of the needle and insertion of the fiber into the center of the nidus. Coagulation (spherical regions of marrow and cortical necroses, *arrows*) is present around the fiber tip. The longitudinal diameter of coagulation (along the fiber track) is greater than the axial diameter.

A CT scanner was used to assure precise needle placement and to detect carbonization (gas inside the nidus). Penetration of the needle into the nidus is always painful and the intervention was performed with the patient under neuroleptanalgesia. The lesion was located precisely on CT scans and the dimensions of the nidus established. The nidus's largest diameter was used to determine the energy necessary to coagulate the tumor (Fig 3A). The current protocol is as follows: nidus diameter \leq 4 mm, 500 joules; nidus diameter = 5 mm, 600 joules; nidus diameter = 6 mm, 800 joules; and nidus diameter \geq 8 mm, 1000 to 1200 joules (13, 16). The experimental work has proved that maximal width extent (14 to 16 mm) is reached after 1000 to 1200 joules of energy delivery. Larger lesions require the insertion of multiple fibers for complete ablation.

The needle was guided by means of CT (16, 17) (Fig 1C). Subperiosteal niduses or cortical niduses without major ossification ($n = 2$) were punctured directly with an 18-gauge spinal needle (Becton Dickinson, Rutherford, NJ). In one case, cortical perforation was accomplished with a 14-gauge bone biopsy needle (Ostycut, Angiomed/Bard Karlsruhe, Germany). A coaxial biopsy was not considered because the small size of the needles does not allow sufficient material to be obtained to confirm the diagnosis.

In all cases, the fiber was inserted into an 18-gauge spinal needle, which served to protect the fiber from breakage. The 18-gauge needle tip was inserted into the center of the nidus. The 400- μ m precharred fiber was inserted through the needle and the needle was withdrawn about 5 mm, so that the tip of the bare fiber lay within the tumor. Precharring the fiber tip was performed clinically by firing the fiber into a few milliliters of the patient's own blood just before introduction. The diode laser (805 nm) was turned on in continuous-wave mode at a power of 2W for 300 to 400 seconds (total energy, 600 to 800 joules). The energy delivered depended on nidus size (9, 13, 14, 16, 17) (Table).

Results

Percutaneous ILP was successful in all patients, producing relief of pain within 24 hours of the procedure and allowing a prompt return to normal activities. After the procedure, one patient (case 2) had a moderate headache for 1 week (Fig 2). Follow-up ranged from 20 to 60 months (mean, 37 months),

during which time the patients remained pain-free without evidence of recurrence. Follow-up CT examinations were performed in all patients. After a period of 6 to 24 months, the lucent area of the nidus was replaced by normal bone (Fig 1D) or sclerosis. No late complications or recurrences were observed.

Discussion

Many techniques have been proposed to treat osteoid osteoma, including surgical resection, percutaneous trocar extraction, alcoholization, and thermocoagulation by radio frequency and laser (4, 5, 16–26). Surgical or percutaneous excision of the nidus is not free from risk, particularly surgical excision. Patients treated by wide excisional margin have an average hospital stay of 5 days (23). Weakening of bone from surgical removal of a portion of the cortex is particularly problematic in weight-bearing bones. This risk is lower with percutaneous extraction of the nidus, but the use of a large drill (7-mm diameter) and the need to make several passes to complete the resection on weight-bearing bones impose limitations on activity for up to 3 months (20, 25). In patients with spinal osteoid osteoma, the use of such large instruments incurs the risk of neurologic and vascular injury.

ILP has been performed in experimental models to determine the feasibility of bone photocoagulation using an 805-nm diode laser and to define the parameters that influence lesion size and shape (13). This experimental work has shown that a reproducible, well-defined area of coagulative necrosis can be obtained around the precharred fiber tip in bone, with good correlation between energy delivered and lesion size. The use of precharred fiber allows a more reproducible coagulation size, independent of location on the bone. This work has also proved that maximal extent is reached after delivery of 1000 to 1200 joules

(13). More energy deliverance at the same position does not modify the coagulation size. This finding is consistent with previous studies that showed that the transmission of heat within bone is sharply limited (14, 15). Forty-seven patients with osteoid osteoma in various locations were treated with percutaneous ILP of the nidus under CT control without major complications. The procedure required only overnight hospitalization and did not limit normal activity.

The drawback of this technique is the lack of histologic verification. In procedures involving resectional and radio-frequency ablation with systematic biopsy, confirmation of osteoid osteoma is obtained in 57% to 79% of cases (5, 20, 24). The joint decision to proceed with ILP was made by a team of rheumatologists, neurosurgeons, orthopedic surgeons, skeletal radiologists, and interventional radiologists. ILP of osteoid osteoma was only performed in patients with typical lesions. If any doubts persisted in the diagnosis of osteoid osteoma, ILP was not done.

Conclusion

ILP of spinal osteoid osteoma under CT guidance is a minimally invasive technique in which an 18-gauge to maximum 14-gauge needle is used to introduce the fiber into the nidus. The ability to precisely control the treated area, a high degree of precision, applicability in joints, and excellent dose-response characteristics may make ILP and radio-frequency ablation preferable to alcoholization and other in situ tissue ablation techniques (4, 5, 16–19, 22). The procedure is performed with the patient under neuroleptanalgesia and requires only overnight hospitalization. ILP is not appropriate for the treatment of osteoid osteoma when the nidus is too near neural structures, as a minimum distance of 8 mm is mandatory to avoid neural damage. Otherwise, ILP is a safe and effective way to treat this benign tumor.

Acknowledgment

We thank Stephen Ferron for his assistance with this work.

References

1. Kransdorf MJ, Stull MA, Gilkey FW, Moser RP Jr. **Osteoid osteoma.** *Radiographics* 1991;11:671–696
2. Resnick D, Kyriacos M, Greenway GD. **Tumor and tumor-like lesions of bone: imaging of specific lesions.** In: Resnick D, Niwayama G, eds. *Diagnosis of Bone and Joint Disorders*. 3rd ed. Philadelphia: Saunders; 1995:3629
3. Runge M. **Ostéome ostéoïde vertébral: Intérêt diagnostique de l'examen scanographique.** *J Radiol* 1986;67:885–889
4. Rosenthal DI, Alexander A, Rosenberg AE, Springfield D. **Ablation of osteoid osteomas with a percutaneously placed electrode, a new procedure.** *Radiology* 1992;183:29–33
5. Rosenthal DI, Springfield DS, Gebhardt MC, Rosenberg AE, Manikin HJ. **Osteoid osteoma: percutaneous radio-frequency ablation.** *Radiology* 1995;197:451–454
6. Bown SG. **Phototherapy of tumors.** *World J Surg* 1983;7:700–709
7. Amin Z, Buonaccorsi GA, Mills TN, et al. **Interstitial laser photocoagulation in rat liver: importance of fibre type, laser wavelength and tissue charring.** In: Jacques SL, ed. *Proceeding of the Society for Photo-optical Instrumentation Engineers (SPIE): Laser-Tissue Interaction IV*. Washington, DC: SPIE; 1993;1882:172–183
8. Amin Z, Donald JJ, Masters A, et al. **Hepatic metastases: interstitial laser photocoagulation with real-time US monitoring and dynamic CT evaluation of treatment.** *Radiology* 1993;187:339–347
9. Dachman AH, Smith MJ, Burrell JA, VanDeMerve WP. **Interstitial laser ablation in experimental models and clinical use.** *Semin Inter Radiol* 1993;10:101–112
10. Harries SA, Amin Z, Smith MEF, et al. **Interstitial laser photocoagulation as a treatment for breast cancer.** *Br J Surg* 1994;81:1617–1619
11. Kahn T, Schwabe B, Bettag M, et al. **Mapping of the cortical motor hand area with functional MR imaging and MR imaging-guided laser-induced interstitial thermotherapy of brain tumors.** *Radiology* 1996;200:149–157
12. Nolsoe P, Torp-Pedersen S, Burchart F, et al. **Interstitial hyperthermia of colorectal liver metastases with a US-guided Nd:YAG laser with a diffuser tip: a pilot clinical study.** *Radiology* 1993;187:333–337
13. Gangi A, Gasser B, De Unamuno S, et al. **New trends in interstitial laser photocoagulation of bones.** *Semin Musculoskeletal Radiol* 1997;1:331–337
14. Lundsberg J. **Heat and bone tissue.** *Scand J Plast Reconstr Surg* 1972;Suppl 9:1–80
15. Tillotson CL, Rosenberg AE, Rosenthal DI. **Controlled thermal injury of bone report of a percutaneous technique using radiofrequency electrode and generator.** *Invest Radiol* 1989;24:888–892
16. Gangi A, Dietemann JL, Gasser B, et al. **Percutaneous laser photocoagulation of osteoid osteomas.** *Semin Musculoskeletal Radiol* 1997;1:273–279
17. Gangi A, Dietemann JL, Gasser B, et al. **Percutaneous laser photocoagulation of osteoid osteomas with use of CT guidance.** *Radiology* 1997;203:843–848
18. Abe E, Sato K, Okada K, Mizutani Y, Ishizawa N, Suzuki T. **Selective en bloc resection of osteoid osteoma of the superior articular process of the sacral spine: a case report.** *Spine* 1993;18:2336–2339
19. Adam G, Neuerburg J, Vorwerk D, Forst J, Günther RW. **Percutaneous treatment of osteoid osteomas: combination of drill biopsy and subsequent ethanol injection.** *Semin Musculoskeletal Radiol* 1997;1:281–284
20. Assoun J, Railhac JJ, Bonneville P, et al. **Osteoid osteoma: percutaneous resection with CT guidance.** *Radiology* 1993;188:541–547
21. Doyle T, King K. **Percutaneous removal of osteoid osteomas using CT control.** *Clin Radiol* 1989;40:514–517
22. Kohler R. **Treatment of osteoid osteoma by percutaneous drill resection with CT control: a study of 12 cases.** *J Pediatr* 1992;2:78–82
23. Lindner NJ, Scarborough M, Ciccarelli JM, Enneking WF. **Die CT-gesteuerte Thermokoagulation des Osteoidosteomas im Vergleich zu traditionellen verfahren.** *Z Orthop* 1997;135:522–527
24. Mazoyer JF, Kohler R, Bossard D. **Osteoid osteoma: CT-guided percutaneous treatment.** *Radiology* 1991;181:269–271
25. Parlier-Cuau C, Nizard R, Champsaur P, Hamze B, Laredo JD. **Percutaneous resection of osteoid osteomas.** *Semin Musculoskeletal Radiol* 1997;1:257–264
26. Voto SJ, Cook AJ, Arrington G, Weiner IDS, Ewing JW. **Treatment of osteoid osteoma, by computed tomography guided excision in a pediatric patient.** *J Pediatr Orthop* 1990;10:510–513