This information is current as of October 11, 2024.

# Direct emergence of the dorsospinal artery from the aorta supplying the anterior spinal artery: report of two cases.

V Lefournier, P Bessou, P Gailloud, A Vasdev, D Rüfenacht and K Boubagra

*AJNR Am J Neuroradiol* 1998, 19 (10) 1961-1962
http://www.ajnr.org/content/19/10/1961

*AJNR Am J Neuroradiol* 19:1961–1962, November 1998

# Direct Emergence of the Dorsospinal Artery from the Aorta Supplying the Anterior Spinal Artery: Report of Two Cases

Virginie Lefournier, Pierre Bessou, Philippe Gailloud, Ashok Vasdev, Daniel Rüfenacht, and Kamel Boubagra

**Summary: We report two cases of an isolated dorsospinal artery that emerged directly from the aorta to supply the anterior spinal artery, which in one case had another blood supply on the opposite side, in a lower position. It is important to identify this anatomic variant, otherwise spinal angiography might be incomplete, especially when the isolated dorsospinal artery supplies the anterior spinal artery.**

Spinal angiography is required on some occasions, and basic anatomy as well as anatomic variants have to be understood.

## Case Reports

### *Case 1*

A 36-year-old woman underwent spinal angiography before surgery for a T7–T8 herniated disk. A common T9–T10 trunk arose on the left side at the T10 level. A dorsospinal branch emerged at the T10 level but not at the T9 level (Fig 1A). A narrow dorsospinal artery was catheterized at that level, directly from the aorta, giving rise to the anterior spinal artery (Fig 1B), which had a second blood supply on the opposite side at the T11 level (Fig 1C).

### *Case 2*

A 50-year-old man required spinal angiography before percutaneous vertebroplasty for painful osteoporosis with fracture of the vertebral body. A common T9–T10 trunk arose on the left side at the T10 level. A dorsospinal branch emerged at the T10 level but not at the T9 level (Fig 2A). The dorsospinal artery was catheterized at that level directly from the aorta, which supplied the anterior spinal artery (Fig 2B).

## Discussion

Direct emergence of the dorsospinal artery from the aorta has rarely been reported. In three instances the dorsospinal artery has been reported at the right T9 level (1) and once each at the left T10 level (2) and the right T8 level (3). Furthermore, this isolated dorsospinal artery has been found to supply the anterior spinal artery in only one case (2). A similar situation was found in our first case, in which the anterior spinal artery had a dual blood supply.

A recent angiographic study of patients undergoing spinal cord vascularization at the thoracolumbar level revealed a dual blood supply for the anterior spinal artery in 48% of the patients studied, the lowest of the two supplying only the conus medullaris, which was validated by a conic arcade. A single blood supply was noted in 45% of the patients, and three anterior radiculospinal arteries supplied the spinal cord in 7% of the patients (4). The case reported here is slightly different, because both radiculospinal arteries supplied the conus medullaris, not just the lowest; however, no statistical analysis has been reported in the literature concerning this particular variation.

The anatomic variant arises when the anastomosis of segmental arteries occurs some distance from the spine; the persistence of the initial portion of the primitive segmental trunk giving rise to the sole dorsospinal artery, directly from the aorta (1).

One sign that suggests such a variant is the absence of a hemivertebral blush at the concerned level during injection of adjacent ipsilateral and contralateral intercostal arteries (1). However, if upper or lower ipsilateral intercostal arteries are injected at the affected level without resulting hemivertebral blush, it can nonetheless be obtained by contralateral segmental arteries, owing to vertebral anastomoses.

In our second case, spinal angiography was performed to identify the presence and location of the main arterial and venous supply to the spinal cord prior to a combined percutaneous and surgical procedure for painful osteoporosis complicated by vertebral body fracture. Although no longer performed routinely before vertebroplasty, a spinal angiographic study may still be considered for highly vascular lesions, such as hemangiomas and hypervascularized metastases involving a vertebral body. In such in-

Received November 11, 1997; accepted after revision March 16, 1998.

From the Department of Neuroradiology, Hôpital A. Michallon, Grenoble, France (V.L., P.B., A.V., K.B.); and the Division of Diagnostic and Interventional Radiology, University of Geneva, Switzerland (P.G., D.R.).

Address reprint requests to Virginie Lefournier, MD, Service de Neuroradiologie, Hôpital A. Michallon, BP 217, 38043 Grenoble cedex 9, France.

© American Society of Neuroradiology

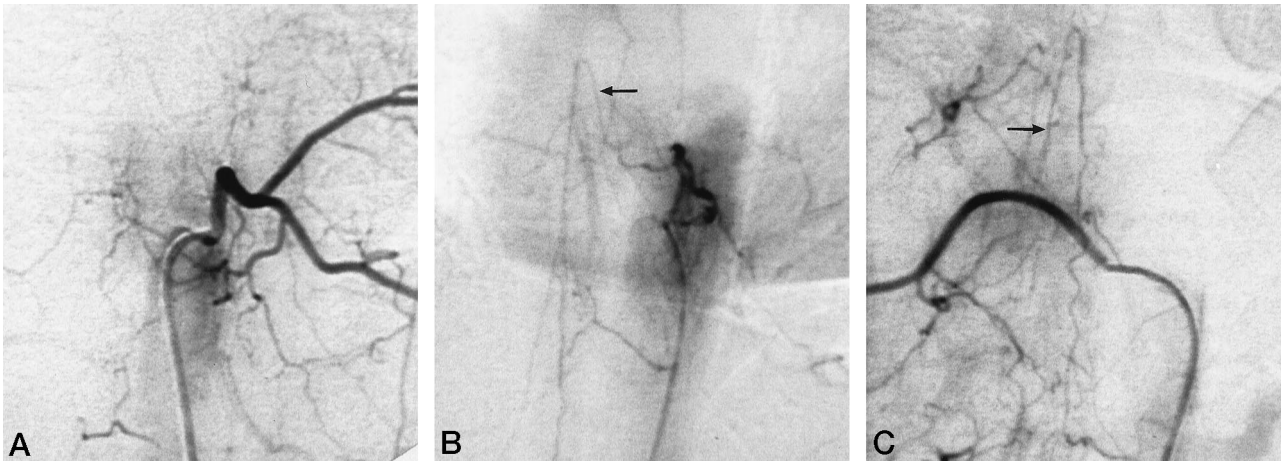


FIG 1. Case 1: 36-year-old woman who had spinal angiography before surgery for a T7–T8 herniated disk.
*A*, Left T9–T10 common trunk arises at the T10 level with no dorsospinal artery at the T9 level.
*B*, Isolated dorsospinal artery at left T9 level supplies the anterior spinal artery (*arrow*).
*C*, Second blood supply of the anterior spinal artery at right T11 level (*arrow*).

FIG 2. Case 2: 59-year-old man who had spinal angiography before percutaneous vertebroplasty for painful osteoporosis with fracture of the vertebral body.
*A*, Left T9–T10 common trunk arises at the T10 level with no dorsospinal artery at the T9 level.
*B*, Isolated dorsospinal artery at left T9 level supplies the anterior spinal artery (*arrow*).

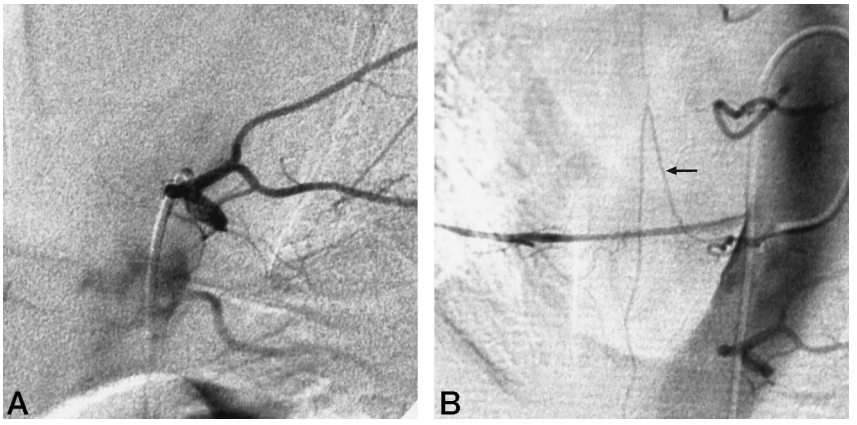


stances, spinal angiography may be helpful in planning the therapeutic approach, in particular to prevent reflux of bone cement into vessels critical to the spinal cord supply.

## Conclusion

If usually common trunks between segmental arteries, which are frequently encountered, fill a dorsospinal artery at each level, one should be aware that a bimetameric trunk does not always supply the entire territory of both segmental arteries. Therefore, the dorsospinal artery has to be sought at each level. Spinal angiography might otherwise be incomplete, especially when this isolated dorsospinal artery supplies the anterior spinal artery.

## Acknowledgments

We are grateful to Katrine Wong Sigli and Linda Northrup for their helpful advice on the manuscript.

## References

1. Chiras J, Merland JJ. **The dorsospinal artery, a little known anatomical variant: its importance in spinal angiography.** *J Neuroradiol* 1979;6:93–100
2. Clavier E, Guimaraems L, Chiras J, Merland JJ, Vasquez J. **Isolated dorsospinal artery supplying anterior spinal artery.** *Neuroradiology* 1987;29:213
3. Thron AK. **Clinical applications.** In: *Vascular Anatomy of the Spinal Cord.* Wien: Springer; 1988:65,70
4. Bert S, Iyriboz AT, Barret F, Zouaoui A, Chiras J. **Angiographic study of spinal cord vascularization at the thoraco-lumbar level.** *J Neuroradiol* 1995;22:12–19