

MR of Hippocampal Sclerosis: Comparison of Qualitative and Quantitative Assessments

Jung-Eun Cheon, Kee-Hyun Chang, Hong Dae Kim, Moon Hee Han, Sung Hwan Hong, Su Ok Seong, In-One Kim, Sang Gun Lee, Yong Seung Hwang, and Hyun-Jip Kim

PURPOSE: Our goal was to compare the diagnostic accuracy of subjective visual assessment versus MR volumetry in evaluating hippocampal sclerosis and to determine whether MR volumetry is needed in the lateralization of this disease process.

METHODS: MR imaging findings were studied retrospectively in 48 patients who underwent surgery for temporal lobe epilepsy and were compared with findings at MR volumetry on an Allegro workstation. Both visual assessment and volumetry were carried out in a blinded fashion with oblique coronal T1-weighted three-dimensional MP-RAGE images obtained on either 1.0-T or 1.5-T units. Normal right-left volumetric differences were recorded in 30 control subjects. The optimum cutoff threshold value for right-left volumetric differences in the sensitivity and specificity of volumetric measurement was obtained from receiver operating characteristic analysis.

RESULTS: Sensitivity, specificity, positive and negative predictive values, and accuracy of visual assessment were 86%, 83%, 86%, 83%, and 85%, respectively. For MR volumetry, with the optimum cutoff threshold value of right-left difference at 0.3 cm³, sensitivity, specificity, positive and negative predictive values, and accuracy were 81%, 82%, 87%, 83%, and 85%, respectively.

CONCLUSION: Visual assessment was slightly superior to or similar to MR volumetry in assessing unilateral hippocampal sclerosis. MR volumetry of the hippocampus may not be needed for the evaluation of most cases of suspected hippocampal sclerosis.

Hippocampal sclerosis, defined as neuronal loss and gliosis of the hippocampus, is the most common abnormality associated with intractable temporal lobe epilepsy (TLE) (1–4). Most patients with hippocampal sclerosis experience satisfactory improvement after resection of the affected hippocampus (1–3). Diagnosis of hippocampal sclerosis is based primarily on magnetic resonance (MR) imaging findings of volume loss and/or T2 high signal intensity of the hippocampus, reflecting neuronal loss and gliosis, respectively (5–12). In some patients, it is difficult to visually determine whether a hippocampus is atrophic. MR-based volumetric measurement of the hippocampus has been applied in those patients and recognized as a sensitive and specific method for detecting changes

in volume associated with hippocampal sclerosis (13–20). Sensitivity and specificity of MR volumetry reported in the literature vary, ranging from 76% to 95% and from 73% to 100%, respectively (14–19). Development of high-resolution MR imaging techniques, including fast spin-echo T2-weighted and three-dimensional T1-weighted gradient-echo imaging with thin sections and large matrices, has led to more accurate visual assessment of epileptogenic foci in patients with TLE.

The purpose of our study was to compare the diagnostic accuracy of subjective visual assessment versus MR volumetry in the lateralization of hippocampal sclerosis.

Methods

Forty-eight patients who underwent anterior temporal lobectomy (including the hippocampus) for treatment of intractable TLE and 30 control subjects were studied. Patients in whom extrahippocampal focal epileptogenic lesions, such as tumors, vascular malformations, and malacia, were seen on MR images were excluded. The group of patients included 24 males and 24 females, ranging in age from 12 to 55 years (mean age, 30 years). Forty-three of the 48 patients had pathologic changes consistent with hippocampal sclerosis (neuronal degeneration and loss, and fibrillary astrocytic proliferation). In 13 patients with hippocampal sclerosis, cortical dysgenesis, or microdysgenesis was also present. Five patients had isolated

Received June 10, 1997; accepted after revision September 2.

Supported by a grant from the Medical Technology Development Research Fund, Ministry of Health and Welfare (1996).

From the Departments of Diagnostic Radiology (J-E.C., K-H.C., H.D.K., M.H.H., S.H.H., S.O.S., I-O.K.), Neurology (S.G.L.), Pediatrics (Y.S.H.), and Neurosurgery (H-J.K.), Seoul (Korea) National University College of Medicine.

Address reprint requests to Kee-Hyun Chang, MD, Department of Diagnostic Radiology, Seoul National University Hospital, 28 Yongon-Dong, Chongno-Gu, Seoul, 110–744, Korea.

cortical dysgenesis or dysplasia with no evidence of hippocampal sclerosis (Table 1). No patient had neoplasm or vascular malformation.

The control group comprised 16 men and 14 women, made up of either healthy volunteers or outpatients who had no history of seizure or dementia and no abnormality on brain MR images. Ages in this group ranged from 20 to 46 years (mean age, 35 years).

All MR imaging studies were performed on either 1.5-T or 1.0-T units. T1-weighted sagittal sequences and proton density- and T2-weighted axial fast spin-echo sequences were obtained. Parameters for T2-weighted images were 3500–4000/95/1 (repetition time/echo time/excitation), 20- to 24-cm field of view (FOV), and 5-mm section thickness. The T1-weighted sequence parameters were 550/15/2, 5-mm section thickness, and 21-cm FOV. Oblique coronal images were obtained perpendicular to the long axis of the hippocampus with 2-mm-thick T1-weighted 3-D magnetization-prepared rapid acquisition gradient-echo (MP-RAGE) sequences and 3-mm-thick T2-weighted fast spin-echo sequences. Parameters for the 3-D MP-RAGE images were 10/4/1, inversion time of 300, 10° flip angle, 256-mm slab thickness, 128 partitions, 2-mm effective section thickness, 256 × 256 matrix size, and 25-cm FOV. In 29 of 48 patients, the raw data of the 3-D MP-RAGE sequences were obtained in the sagittal plane and then reformatted in the oblique coronal plane perpendicular to the long axis of the hippocampus. In the remaining 19 patients, the raw data were obtained directly in the oblique coronal plane.

For the qualitative assessment, the hard copies of the MR images of the 48 patients and 30 control subjects were intermixed, and these were then analyzed retrospectively by two radiologists without knowledge of the clinical, EEG, or surgical findings. In particular, size and signal intensity of the hippocampus, temporal lobe, temporal horn, collateral white matter, fornix, and mammillary body were carefully assessed visually. The MR diagnosis of hippocampal sclerosis was based on the presence of either unilateral atrophy or high T2 signal intensity of the hippocampus, or both, and on the absence of any other abnormality.

MR volumetry was performed using a graphic workstation (Allegro, ISG Technology, Canada) in 29 of the 48 patients and in the 30 control subjects: MR volumetry was not carried out in the remaining 19 patients in whom the raw data were obtained in the oblique coronal plane, because the raw data of direct oblique coronal MR imaging could not be accepted on the Allegro workstation owing to limitations of the software program. Cross-sectional areas of both hippocampi were measured with oblique coronal reformatted T1-weighted MP-RAGE images by tracing the hippocampal boundary manually from the hippocampal head to tail. Manual tracing of the hippocampus was done by a radiologist who was blinded to the clinical information. On the hippocampal head area, the alveus (white matter tract) defining the superior border of the hippocampal head, characteristic digitations of the hippocampal head, and tip of the temporal horn defining the lateral margin of the hippocampal head were used as landmarks to separate the hippocampus from the overhanging amygdala. When the land-

marks were not obvious, as occasionally happened, since the hippocampal head lies directly beneath the amygdala, judgments about the hippocampal borders were made arbitrarily. The posterior margin of the hippocampal volumetric measurement was defined by the MR image intersecting the ascending portion of the fornix. The gyrus intralimbicus and the quadrigeminal plate were considered the most caudal section of the hippocampal head and body, respectively. The white matter tract (alveus) was not included within the boundary of delineation of the hippocampus. The volumes of both hippocampi were displayed automatically in 3-D format and calculated by summing each of the cross-sectional volumes (multiplying cross-sectional area by section thickness) of the entire hippocampus (from the head to the tail) with CAMRA Allegro Sun software on the workstation.

Normal right-left volumetric differences were obtained in the 30 healthy control subjects. The optimum cutoff threshold value of normal right-left volumetric difference for the sensitivity and specificity of the volumetric measurements was obtained from the receiver operating characteristic (ROC) analysis (Fig 1).

The sensitivity, specificity, positive and negative predictive values, and diagnostic accuracy were estimated for both visual assessment and MR volumetry and compared with each other.

Results

Results of visual assessment are summarized in Table 2. By visual assessment of MR images, unilat-

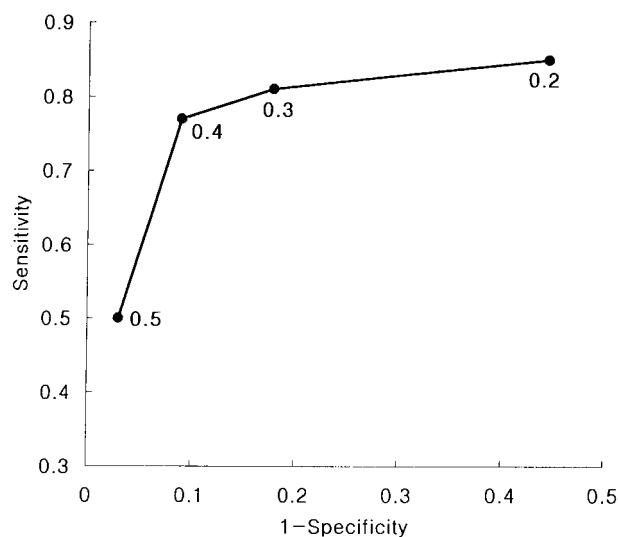


Fig 1. ROC analysis of optimal cutoff value of right-left hippocampal volumetric difference. Optimum cutoff value was determined to be 0.3 cm³ from the ROC curve.

TABLE 1: Pathologic diagnosis (n = 48)

Pathologic Entity	No.
Hippocampal sclerosis with or without heterotropic white matter neurons	30
Hippocampal sclerosis with cortical dysgenesis or microdysgenesis	13
Cortical dysplasia	2
Microdysgenesis	2
Heterotropic white matter neurons	1
Total	48

TABLE 2: Visual assessment versus final diagnosis

Visual Assessment	Final Diagnosis		
	HS+	HS-*	Total*
MR+	37	6 (3)	43 (3)
MR-	6	29 (27)	35 (27)
Total	43	35 (30)	78 (30)

Note.—MR+ indicates unilateral atrophy or high T2 signal intensity of the hippocampus on MR imaging; MR-, no abnormality on MR imaging; HS+, pathologically proved hippocampal sclerosis; HS-, no histologic evidence of hippocampal sclerosis; and HS, hippocampal sclerosis.

* Numbers in parenthesis indicate control subjects.

eral hippocampal sclerosis was lateralized correctly in 37 (86%) of 43 patients. In the remaining six patients (14%), MR findings were judged as normal. Of 35 subjects with no hippocampal sclerosis (five patients in whom it was surgically excluded and 30 healthy control subjects), visual evaluation was correct in 29 (83%) (two patients and 27 control subjects).

At MR volumetry in the 30 control subjects, the average volume of the hippocampus was found to be 2.21 cm³; the average hippocampal volume was slightly larger in women than in men and on the right than on the left side, but the average right-left volumetric difference was not significant in either the men or the women (men: right, 2.20 cm³; left, 2.17 cm³; women: right, 2.27 cm³; left, 2.23 cm³; $P > .05$).

Threshold volumetric difference values of 0.2 cm³, 0.3 cm³, and 0.4 cm³ were applied in 29 of the 48 patients with TLE and in the 30 control subjects to evaluate the diagnostic accuracy of MR volumetry. The resultant sensitivities and specificities are summarized in Table 3. As obtained from the ROC analysis, the optimum cutoff threshold value for the sensitivity and specificity of the volumetric measurement was determined to be 0.3 cm³ (Fig 1, Table 3).

With the cutoff value 0.3 cm³, hippocampal atrophy was correctly lateralized in 21 of 26 patients with hippocampal sclerosis (81%). Of 33 subjects without hippocampal sclerosis (three patients in whom it was proved pathologically and 30 control subjects), 27 (82%) had true-negative MR volumetric findings (Table 4).

Sensitivity, specificity, positive and negative predictive values, and accuracy of visual assessment and MR volumetry are tabulated in Table 5. The sensitivity of visual assessment was slightly higher than that of MR volumetry (86% versus 81%), while specificity of visual assessment was similar to that of MR volumetry (83% versus 82%).

Among the three of six patients with false-negative findings on visual assessment in whom MR volumetric data were available, two also had false-negative results on MR volumetry and only one had true-positive results with the cutoff value of 0.3 cm³.

TABLE 3: Optimal cutoff value of MR volumetry

Right-Left Volume Difference, cm ³	Sensitivity, %	Specificity, %
0.2	85	55
0.3	81	82
0.4	77	91
0.5	50	97

TABLE 4: MR volumetry versus final diagnosis

Right-Left Volumetric Difference, cm ³	Final Diagnosis		
	HS+	HS-	Total
≥0.3	21	6 (6)	27 (6)
<0.3	5	27 (24)	32 (24)
Total	26	33 (30)	59 (30)

Among the five of six patients with false-positive findings on visual assessment in whom MR volumetric data were available (three control subjects and three patients with TLE who had had surgery), three of the control subjects also had false-positive results on MR volumetry and two of the patients with TLE had true-negative findings. Of five patients with false-negative results on MR volumetry, two had false-negative findings at visual assessment and three had true-positive findings. Of six subjects (all from the control group) with false-positive results at MR volumetry, three had false-positive findings on visual inspection and three had true-negative findings.

Discussion

Atrophy of the hippocampus is the most common and consistent MR imaging finding in hippocampal sclerosis. Sometimes it is difficult to visually decide whether hippocampal atrophy is present, particularly in cases of normal asymmetry of the hippocampus, bilateral atrophy, or subtle unilateral atrophy. In these patients, MR volumetry may be helpful. Several previous investigators have reported that quantitative MR volumetry of the hippocampus is more sensitive than visual assessment in detecting atrophy (14, 17–18). There are several advantages of MR volumetry of the hippocampus. It provides objective and quantitative data with well-defined criteria for lateralization, it corrects for patients' head rotation, and it can identify bilateral atrophy. However, it is a labor-intensive and time-consuming procedure, requires special training, and has a potential for measurement error. Precise measurement of the hippocampal volume resulting in consistently reliable volumes is difficult, because arbitrary judgment is unavoidable when delineating the anterior and posterior boundaries of the hippocampus. Even with the contiguous thin sections, it is difficult to distinguish the anterior hippocampus from the posterior amygdala. In borderline cases, a small measurement error may result in false-negative or false-positive lateralization.

Another limitation of MR volumetry is that a difference of more than 10% in right and left hippocampal volume is a normal variation in some healthy subjects. This difference may be apparent with both visual inspection and volumetric measurements, and represents a significant pitfall in MR volumetry. In our study, six (20%) of 30 control subjects had false-positive results at MR volumetry. The relatively high

TABLE 5: Diagnostic accuracy of visual assessment versus MR volumetry

	Visual Assessment, % (No.)	MR Volumetry, % (No.)
Sensitivity	86 (37/43)	81 (21/26)
Specificity	83 (29/35)	82 (27/33)
Positive predictive value	86 (37/43)	78 (21/27)
Negative predictive value	83 (29/35)	84 (27/32)
Accuracy	85 (66/78)	81 (48/59)

false-negative (19%; 5/26) and false-positive (18%; 6/33) findings in our MR volumetric assessment may be the result of normal variations and measurement errors.

In our study, the normal hippocampal values were significantly smaller than those reported in previous studies (13–20). These relatively lower measurements may be the result of racial differences or, more likely, different measurement criteria. The previous studies might have included a more anterior extension of the hippocampus and of the white matter of the hippocampal formation. In our study, the white matter tract, such as the alveus, was not included within the boundary delineation.

The reported sensitivity and specificity for detection of hippocampal sclerosis by visual inspection of MR images have also varied widely (6–9, 14), reflecting the fact that these series were published during a time of technical maturation of MR imaging, and that the pathologic criteria used to define hippocampal sclerosis vary somewhat among institutions. It is currently recognized that visual inspection for unilateral atrophy and increased signal intensity of the hippocampus on T2-weighted fast spin-echo or fluid-attenuated inversion-recovery (FLAIR) MR images allows for sensitivity and specificity of 80% to 90%. This was the case in our study, which disclosed a sensitivity and specificity of 86% and 83%, respectively. Although MR volumetry is known to improve sensitivity in the detection of hippocampal sclerosis by a small incremental amount, this technique is not currently used as a routine procedure in most institutions.

Theoretically, it is conceivable that MR volumetry may obviate the supplementary examinations, such as ictal single-photon emission computed tomography (SPECT), positron emission tomography (PET), and invasive EEG in selected patients with a normal-sized hippocampus on visual inspection. From a practical point of view, surgical selection is not done without positive findings of other supplementary studies, because concordance between ictal EEG and imaging findings, including MR imaging, ictal SPECT, and/or PET, is important in the lateralization of epileptogenic foci. Currently, a battery of preoperative examinations is conducted in most patients in search of concordance. Considering the trend of cost-containment efforts in health care, selective use of imaging studies before epilepsy surgery will be demanded in the future.

Conclusion

The diagnostic accuracy of visual estimation was similar to or slightly better than that of MR volumetry in the evaluation of hippocampal sclerosis. MR

volumetry of the hippocampus is not needed in the evaluation of most cases of suspected hippocampal sclerosis.

References

1. Spencer SS. **Surgical options for uncontrolled epilepsy.** *Neurol Clin* 1986;4:669–695
2. Glaser GH. **Treatment of intractable temporal lobe-limbic epilepsy (complex partial seizures) by temporal lobectomy.** *Ann Neurol* 1980;8:455–459
3. Falconer MA. **Mesial temporal (Ammon's horn) sclerosis as a common cause of epilepsy: etiology, treatment and prevention.** *Lancet* 1974;1:767–770
4. Scheibel ME, Crandall PH, Scheibel AB. **The hippocampal-dentate complex in temporal lobe epilepsy.** *Epilepsia* 1974;15:55–80
5. Kuzniecky R, de la Sayette V, Ethier R, et al. **Magnetic resonance imaging in temporal lobe epilepsy: pathologic correlation.** *Ann Neurol* 1987;22:341–347
6. Bronen RA, Cheung G, Charles JT, et al. **Imaging findings in hippocampal sclerosis: correlation with pathology.** *AJNR Am J Neuroradiol* 1991;12:933–940
7. Bronen RA. **Epilepsy: the role of MR imaging.** *AJR Am J Roentgenol* 1992;159:1165–1174
8. Brooks BS, King DW, Gammal TE, et al. **MR imaging in patients with intractable complex partial epileptic seizures.** *AJNR Am J Neuroradiol* 1990;11:93–99
9. Jackson GD, Berkovic SF, Tress BM, Kalnins RM, Fabinyi G, Bladin PF. **Hippocampal sclerosis can be reliably detected by magnetic resonance imaging.** *Neurology* 1990;40:1869–1875
10. Tien RD, Felsberg GJ, Castro CC et al. **Complex partial seizure and mesial temporal sclerosis: evaluation with fast spin-echo MR imaging.** *Radiology* 1993;189:835–842
11. Jack CR, Krecke KN, Luetmer PH, et al. **Diagnosis of mesial temporal sclerosis with conventional versus fast spin-echo MR imaging.** *Radiology* 1994;192:123–127
12. Jack CR, Rydberg CH, Krecke KN, et al. **Mesial temporal sclerosis: diagnosis with fluid-attenuated inversion-recovery versus spin-echo MR imaging.** *Radiology* 1996;199:367–373
13. Jack CR, Twomey CK, Zinsmeister AR, Sharbrough FW, Petersen RC, Cascino GD. **Anterior temporal lobes and hippocampal formation: normative volumetric measurements from MR images in young adults.** *Radiology* 1989;172:549–554
14. Jack CR, Sharbrough FW, Twomey CK, et al. **Temporal lobe seizures: lateralization with MR volume measurements of the hippocampal formation.** *Radiology* 1990;175:423–429
15. Ashtari M, Barr WB, Schaul N, Bogerts B. **Three-dimensional fast low-angle shot imaging and computerized volume measurement of the hippocampus in patients with chronic epilepsy of the temporal lobe.** *AJNR Am J Neuroradiol* 1991;12:941–947
16. Casino GD, Jack CR Jr, Parisi JE, et al. **Magnetic resonance imaging-based volume studies in temporal lobe epilepsy: pathological correlations.** *Ann Neurol* 1991;30:31–36
17. Lencz T, McCarthy G, Bronen RA, et al. **Quantitative magnetic resonance imaging in temporal lobe epilepsy: relationship to neuropathology and neuropsychological function.** *Ann Neurol* 1992;31:629–637
18. Jack CR Jr, Sharbrough FW, Casino GD, Hirschorn KA, O'Brien PC, Marsh WR. **Magnetic resonance image-based hippocampal volumetry: correlation with outcome after temporal lobectomy.** *Ann Neurol* 1992;31:138–146
19. Kim JH, Tien RD, Felsberg GJ, Osumi AK, Lee N. **MR measurements of the hippocampus for lateralization of temporal lobe epilepsy: value of measurements of the body vs the whole structure.** *AJR Am J Roentgenol* 1994;163:1453–1457
20. Martinez M, Santamaria J, Mercader JM, Catafau A, Cardenal C, Lomena F. **Correlation of MRI hippocampal volume analysis, video/EEG monitoring and inter- and postictal single emission tomography in refractory focal epilepsy.** *Neuroradiology* 1994;36:11–16