

An Early MR Observation of Carotid Involvement by Retropharyngeal Abscess

Christophe Ide, Eddy Bodart, Marc Remacle, Béatrice De Coene,
Jean-François Nisolle, and Jean-Paul Trigaux

Summary: We report early carotid involvement by retropharyngeal abscess in a 4-year-old boy. MR imaging showed enhancement of the wall and narrowing of the lumen of the internal carotid artery, which were thought to reflect spasm and/or arteritis. Prompt treatment may have prevented hemorrhagic and neurologic complications.

Retropharyngeal abscess, usually seen in children, is a serious infection with an enormous potential for extension into adjacent structures. Prompt diagnosis and treatment are essential to prevent complications. Although carotid involvement by such infections has become exceptional in the era of antibiotics, it still constitutes a potentially life-threatening complication (1, 2). This report illustrates the importance of magnetic resonance (MR) imaging in showing early carotid involvement before rupture, pseudoaneurysm, or occlusion.

Case Report

A 4-year-old boy was taken to his family practitioner with low-grade fever, asthenia, and a progressively enlarging tumefaction on the right side of the neck. A diagnosis of cervical lymphadenitis was made, and the patient was treated with oral antibiotics. Two days later, he was admitted to our hospital because the swelling had not regressed and had caused hyperextension of the neck and difficulty in swallowing. Physical examination revealed a tender mass behind the right angle of the mandible, smaller adjacent lymph nodes, and nuchal rigidity. The right tonsil was displaced anteriorly. Laboratory investigations showed a white cell count of $30.5 \times 10^9/L$, 75% of which were polymorphonuclear cells. C-reactive protein was 24.8 mg/dL.

An MR examination of the neck revealed a 1.2-cm abscess in the right side of the suprahyoid retropharyngeal space, probably originating within a lymph node. This suppurative lymphadenitis was surrounded by a prominent cellulitis extending into the adjacent parapharyngeal, prevertebral, and carotid spaces (Fig 1A and B). The internal carotid artery was displaced laterally by the mass and showed strong circumferential enhancement of the wall, with significant luminal narrowing on T1-weighted images after injection of gadopentetate dimeglumine (Fig 1A–C). The narrowing and the wall enhancement were seen all along the course of the internal carotid artery up to the cavernous segment (Fig 1C), but narrowing was greatest at the level of the abscess (Fig 1B). A normal flow void was still present in the center of the vessel. The right internal jugular

vein remained patent and the oropharyngeal airway was moderately narrowed (Fig 1B). Because of these unusual and alarming imaging features, the abscess was considered to constitute a risk for arterial or neurologic complications and the patient was scheduled for surgery the next day.

A tonsillectomy was performed, and the abscess was drained by direct incision of the posterior pharyngeal wall. Bacterial cultures grew *Streptococcus viridans*. The child made an uneventful postoperative recovery, and follow-up MR examination 1 week later showed a persistent irregular collection and normalization of the luminal diameter of the carotid artery (Fig 1D and E). No neurologic deficit or hemorrhage was detected either before or after the operation.

Discussion

Complications of infections of the deep neck space are related to the regional anatomic structures. The fascia separating the neck spaces do not provide an anatomic barrier to infection; hence, an infection of the retropharyngeal space can involve the prevertebral, the danger, the parapharyngeal, the pharyngeal mucosal, and the carotid spaces. Resulting complications include vertebral osteomyelitis, mediastinitis, airway obstruction, and rupture into the airway, with aspiration and vascular difficulties involving the jugular or carotid vessels (3).

With the widespread use of antibiotics, infection of the deep neck spaces rarely involves the carotid artery; however, when this does occur, it may pose significant diagnostic and therapeutic challenges. Usually, the diagnosis is made at an advanced stage, when the patient presents with a hemorrhage (1, 2, 4), a pseudoaneurysm (5), or possibly an acute hemiplegia (6). The internal carotid artery is more likely to be involved by nearby infections than are both the external and common carotid arteries combined. Reported explanations for this selectivity include the proximity of the internal carotid artery to the tonsil, especially when its course is anomalous or tortuous, and the large number of lymph nodes closely adherent to it (1, 4).

Carotid ligation has been the standard treatment of

Received January 23, 1997; accepted after revision April 17.

From the Departments of Radiology (C.I., B.D.C., J-F.N., J-P.T.), Pediatrics (E.B.), and Otorhinolaryngology (M.R.), Cliniques Universitaires UCL de Mont-Godinne, B-5530 Yvoir, Belgium.

Address reprint requests to Christophe Ide MD, Department of Radiology, Cliniques Universitaires UCL de Mont-Godinne, B-5530 Yvoir, Belgium.

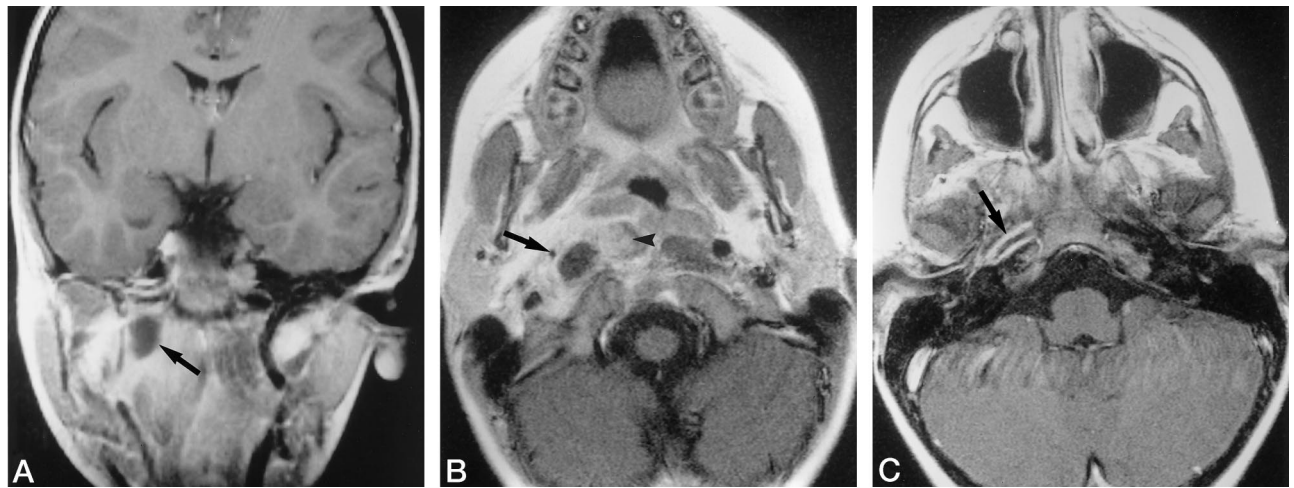


FIG 1. Contrast-enhanced T1-weighted spin-echo MR images in coronal (A) and transverse (B-E) planes show carotid arteritis complicating a retropharyngeal abscess in a 4-year-old child, with complete resolution after surgery.

A, Coronal image shows a right retropharyngeal abscess with surrounding cellulitis spreading to the adjacent spaces (arrow).

B, Transverse image shows involvement of the longus colli muscle medially (arrowhead) and of the internal carotid artery laterally (arrow), which exhibits significant narrowing of the vessel lumen and enhancement of the wall as compared with the other side.

C, Transverse image at the level of the skull base shows circumferential wall enhancement on the temporal segment of the internal carotid artery (arrow).

D, Transverse image at the same level as B after surgical drainage shows a small residual collection (arrowhead) and normalization of the luminal diameter of the right internal carotid artery (arrow).

E, Transverse image at the same level as C shows disappearance of the wall enhancement after surgery (arrow).

carotid erosion for many years, and while this decision is never to be taken lightly, the literature both before and since the advent of antibiotics clearly shows that it may be lifesaving, often with few if any neurologic sequelae, especially in children (1, 2, 5). More recently, interventional radiologic techniques offer another therapeutic possibility in conjunction with surgery (2).

Several clinical findings are suggestive of arterial complications of deep neck space infections: recurrent, even small hemorrhages from the throat, nose, or ear; protracted clinical course (usually more than 7 to 14 days) with continued swelling of the neck; presentation with hemorrhagic shock; presence of an external or intraoral discoloration, indicating extravasated blood; prolonged trismus and disproportionate pain after drainage of the abscess; and presence of ninth, 10th, 11th, or 12th cranial nerve neuropathies or Horner syndrome (2, 5). Our patient had none of these symptoms except for the persistence of a neck tumefaction despite antibiotics; imaging was performed to search for abscess formation.

Imaging plays a major role in the management of these infections and their arterial complications. Conventional radiography is usually of little benefit. Sonography can accurately depict the presence, location, and characteristics of inflammatory masses and define their relationship to adjacent vessels in the neck. Coupled with duplex or color Doppler imaging, sonography can provide information on the arterial wall and on the blood flow within the lumen or within a pseudoaneurysm. Computed tomography (CT) is useful for detecting abscess formation and for evaluating the spread of infection in adjacent spaces and structures. Loss of definition of the carotid artery close to an apparent abscess should suggest arterial involvement (2), and intense enhancement of the central portion of a mass located on the course of the carotid artery should suggest a pseudoaneurysm (5). Angiography will confirm arterial involvement and enable evaluation of the collateral circulation in the circle of Willis before eventual carotid ligation. In case of hemorrhage, angiography can identify which vessels will require occlusion, and it may be employed

therapeutically. MR imaging, used in our case, is an excellent alternative to CT. Owing to its excellent contrast resolution, it demonstrates more effectively than CT the local extension of infection in the deep neck spaces and its proximity to the vessels. Moreover, combined with MR angiography, it can show anomalies in the vessels. Surprisingly, in this case, we found significant intrinsic anomalies in the internal carotid artery adjacent to the abscess. Contrast-enhanced T1-weighted MR images showed strong circumferential wall enhancement all along its course and significant narrowing of its lumen (Fig 1B and C), both of which were seen to have disappeared completely at the MR examination 1 week after surgery (Fig 1D and E). Lacking actual histologic proof, we are still unaware of the exact nature of the wall anomalies: these findings could have been due to spasm resulting from contiguous inflammation or to actual involvement of the wall of the vessel by the inflammatory process itself. This process could presumably be referred to as arteritis, as this term, per se, not only refers to an infection but also simply to an inflammation of the arterial wall, whatever its severity. Intuitively, wall thickening with enhancement would be more readily expected in a true arteritis than in a spasm. Unfortunately, there is no literature, to our knowledge, defining the exact nature of the wall in the case of carotid narrowing. Infectious arteritis may occur not only by direct involvement of the intima from the arterial lumen but also by dissemination of microorganisms into the vasa vasorum or by direct extension from a nearby septic focus (2). It can weaken the wall of the vessel and hence may lead to carotid rupture or to formation of a pseudoaneurysm.

Another potential manifestation of carotid involvement by sepsis is occlusion. In children, it has also been suggested that arteritis produced by direct extension of infection of the neck or throat might be the more important risk factor, along with trauma, for cervical carotid occlusion (6).

Conclusion

Although exceptional since the advent of antibiotics, arterial complications of deep neck space infections may have devastating consequences, such as exsanguination. These complications may not be suspected before the artery has perforated, which necessitates carotid ligation. This observation shows that MR features of spasm and/or arteritis constitute an early manifestation of carotid involvement by an adjacent retropharyngeal abscess that should lead to emergency drainage before carotid occlusion or rupture.

References

1. Salinger S, Pearlman SJ. **Hemorrhage from pharyngeal and peritonsillar abscesses.** *Arch Otolaryngol* 1933;18:464-509
2. Stevens HE. **Vascular complications of neck space infection: case report and literature review.** *J Otolaryngol* 1990;19:206-210
3. Barratt GE, Koopmann CF, Coulthard SW. **Retropharyngeal abscess: a ten-year experience.** *Laryngoscope* 1984;94:455-463
4. Griffies WS, Wotowic P, Wildes TO. **Spontaneous tonsillar hemorrhage.** *Laryngoscope* 1988;98:365-368
5. Krysl J, Noël de Tilly L, Armstrong D. **Pseudoaneurysm of the internal carotid artery: complication of deep neck space infection.** *AJNR Am J Neuroradiol* 1993;14:696-698
6. Tagawa T, Mimaki T, Yabuuchi H, Iwata Y, Makino A. **Bilateral occlusions in the cervical portion of the internal carotid arteries in a child.** *Stroke* 1985;16:896-898