

Are your MRI contrast agents cost-effective?

Learn more about generic Gadolinium-Based Contrast Agents.



**FRESENIUS
KABI**

caring for life

AJNR

Scanning electron microscopic study of the migrated platinum coil after endovascular embolization of a giant cerebral aneurysm.

T Ozawa, T Koike, S Takeuchi and R Tanaka

AJNR Am J Neuroradiol 1998, 19 (3) 594-595

<http://www.ajnr.org/content/19/3/594.citation>

This information is current as of December 12, 2024.

LETTERS

Scanning Electron Microscopic Study of the Migrated Platinum Coil after Endovascular Embolization of a Giant Cerebral Aneurysm

A 35-year-old woman presented for treatment of a giant cerebral aneurysm measuring $30 \times 25 \times 30$ mm with a small neck (2 mm) at the left middle cerebral artery (MCA) trifurcation. The patient was treated with an endovascular technique: 14 platinum Hilal coils (Cook Inc, Bloomington, Ind) were placed with a small residual portion. Follow-up angiography 4 months later revealed coil compaction; a second session of endovascular treatment was subsequently performed using mechanically detachable coils (interlocking detachable coil [IDC], Target Therapeutics, Fremont, Calif). Three IDCs ($4 \text{ mm} \times 20 \text{ cm}$, $4 \text{ mm} \times 6 \text{ cm}$, and $2 \text{ mm} \times 4 \text{ cm}$) were deposited within the residual aneurysm cavity. Just after unlocking an additional coil ($2 \text{ mm} \times 4 \text{ cm}$), the coil showed a snapping movement and the tail end of the coil protruded into the parent artery. Immediate retrieval was not considered because of minimum protrusion of the coil. The patient was systemically heparinized during and for 3 days after the procedure. Oral anticoagulation was continued for 3 months. Clinically, the patient remained neurologically intact except for a transient right-hand numbness after 5 days. One-week follow-up angiography showed partial migration of the coil into the posterior branch of the MCA. The coil position had not changed and there was neither luminal stenosis nor distal occlusion of the MCA branch on a 1-month follow-up angiogram.

The 8-month follow-up angiogram showed unchanged coil position and enlargement of the residual aneurysm cavity. Surgical exploration was done. Under temporary trapping, an aneurysmotomy was performed and the partially migrated coil was withdrawn gently through the aneurysm cavity. The aneurysm was excluded from the circulation by single neck clipping. The removed coil was submitted for scanning electron microscopic study (Fig 1). A mass of thrombus, composed primarily of red blood cells embedded in rich fibrinous tissue, was adherent around the detaching end of the coil. Thrombus was laminated in some parts, presumably in the blood flow direction, and a lamina of thrombus was projected like a wing. However, there was no evidence of endothelial coverage over the coil.

Studies of the histopathologic reaction to platinum coils in vasculature are very limited, and the role of protective endothelialization over the coils against thrombus formation has not been established. Histologic changes after endovascular embolization techniques have been studied in experimental aneurysms. If platinum coils are tightly packed in the aneurysm cavity, a new intimal layer is reported to cover the neck of aneurysms in experimental swine, canine, and primate models (1). However, complete endothelialization was never seen in rabbit carotid aneurysm models (2). In the postmortem histologic observations in two patients with giant cerebral aneurysms who were treated with Guglielmi detachable coils (GDCs), there was no evidence of endothelialization of the luminal surface at the neck of the aneurysms (3).

Although reasons for the lack of endothelialization in our case are not clear, evidence of fine thrombi on the coil suggests that endothelium was not removed traumatically during the surgical procedure. As the platinum coil was biologically inert and anticoagulation was continued, development of vascularized connective tissue around the migrated coil was lacking,

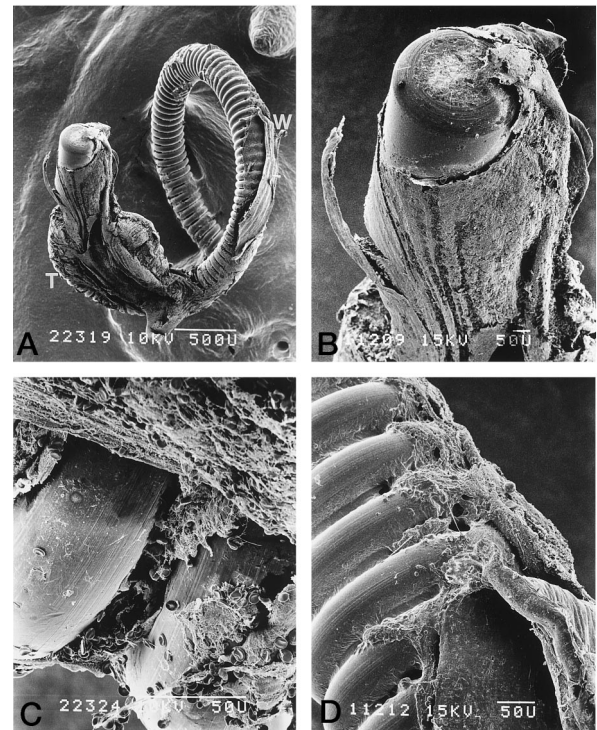


Fig 1. Scanning electron photomicrographs.

A, Low-power photomicrograph shows gross appearance of the detaching end of the partially migrated coil. *T* indicates thrombus around the coil; *W*, detached vascular wall (original magnification $\times 40$).

B, Some thrombi around the coil were laminated, and a lamina is projected like a wing (original magnification $\times 120$).

C, Thrombus is composed of red blood cells in rich fibrinous tissue. Some parts of the coil are not covered by thrombus (original magnification $\times 700$).

D, There is no endothelial coverage even at the margin of the site of adhesion to the vascular wall (original magnification $\times 240$).

which might be one, but not likely the main, cause of endothelialization. It has been shown in a previous study that minimum existence of extracellular matrix-like collagen could propagate cultured canine endothelium on the surface of the platinum coil (4). Endothelialization over platinum coils may be limited in human intracranial arteries. Biochemical characteristics of cultured endothelial cells from brain microvessels are known to be species specific; human endothelial cells grow very slowly in primary cultures and do not proliferate on bare plastic. In contrast, canine cells grow rapidly and proliferate on plastics (5).

Our patient suffered no neurologic symptom except early transient sensory disturbance and there was no angiographic evidence of luminal stenosis or distal occlusion for 8 months. It was anticipated that a new endothelial layer could have played a protective role against thrombus formation over the coil as in some animal models. However, subsequent removal of the coil revealed formation of thrombus with no endothelialization on the surface of the coil. The surface of the partially migrated coil could have been a focus of microthromboembolism. In this

regard, the migrated coils should have been removed earlier either through surgery, endovascular retrieval, or anticoagulation, and antiplatelet therapy should have been maintained.

Tsunenori Ozawa
Tetsuo Koike
Shigekazu Takeuchi
Ryuichi Tanaka
*Department of Neurosurgery
Brain Research Institute
Niigata (Japan) University*

References

1. Teijin H, Fushiki S, Nakahara Y, et al. Effect of Guglielmi detachable coils on experimental carotid artery aneurysms in primates. *Stroke* 1995;26:2075-2080
2. Reul J, Weis J, Spetzger U, et al. Long-term angiographic and histopathologic findings in experimental aneurysms of the carotid bifurcation embolized with platinum and tungsten coils. *AJNR Am J Neuroradiol* 1997;18:35-42
3. Molyneux AJ, Ellison DW, Morris J, Byrne JV. Histological findings in giant aneurysms treated with Guglielmi detachable coils. *J Neurosurg* 1995;83:129-132
4. Tamatani S, Ozawa T, Minakawa T, et al. Histological interaction of cultured endothelial cells and endovascular embolic materials coated with extracellular matrix. *J Neurosurg* 1997;86:109-112
5. Gerhart DZ, Broderius MA, Drewes LR. Cultured human and canine endothelial cells from brain microvessels. *Brain Res Bull* 1988;21:785-793

Reply

This case is important because there is a lack of histologic data in human subjects regarding the changes found in aneurysms treated with endovascular coils. However, histologic analysis of coiled aneurysms in animals has been extensively studied (1, 2). This information is helpful but does not reflect the human condition with respect to vascular endothelialization. Although little information exists regarding the long-term

histologic effects of coils within aneurysms in humans, these authors' findings agree with previously reported histologic findings (3). The absence of endothelial cells attached to the coil is a common finding previously reported. Molyneux et al (3) reported on two patients with coiled aneurysms that were histologically analyzed at autopsy. The coils were embedded in an unorganized thrombus within the aneurysms and there was *no evidence of endothelialization of the aneurysm neck in either case*. They concluded that the persistent immature thrombus was a result of the avascular nature of the aneurysm wall. Usually, there is simultaneously progressive resolution of blood clot with deposition of vascularized fibrous connective tissue. Capillary ingrowth develops from blood vessels in the wall of the aneurysm. Since the wall of an aneurysm is relatively avascular, there is a weak tissue reaction to the presence of clot. The absence of endothelialization at the neck of the aneurysm was consistent with the fact that the neck, like the platinum coils, lacks vascularized fibrous connective tissue necessary for the implantation and growth of endothelial cells.

The authors should be commended for their contribution to the understanding of the long-term effects of endovascular coil implantation within aneurysms. We should exhort other researchers and clinicians to pursue tissue specimens of coiled aneurysms in humans. Only after a thorough understanding of these long-term histologic effects will we treat optimally the patient who has been treated with endovascular coils.

Glen Geremia
*Department of Diagnostic Radiology and Nuclear Medicine
Rush-Presbyterian-St Luke's Medical Center
Chicago, Ill*

1. Mawad M, Mawad J, Cartwright J, Gokaslon Z. Long-term histopathologic changes in canine aneurysms embolized with Guglielmi detachable coils. *AJNR Am J Neuroradiol* 1995;16:7-13
2. Ahuja A, Hergenrother R, Strother C, Rappe A, Cooper S, Graves V. Platinum coil coatings to increase thrombogenicity: a preliminary study in rabbits. *AJNR Am J Neuroradiol* 1993;14:794-798
3. Molyneux A, Ellison D, Morris J, Byrne J. Histological findings in giant aneurysms treated with Guglielmi detachable coils. *J Neurosurg* 1995;83:129-132