

The **next generation** GBCA  
from Guerbet is here

Explore new possibilities >

Guerbet | 

© Guerbet 2024 GU0B220151-A

# AJNR

## **Exophytic primitive neuroectodermal tumor of the spinal cord.**

D Papadatos, S Albrecht, G Mohr and R del  
Carpio-O'Donovan

*AJNR Am J Neuroradiol* 1998, 19 (4) 787-789  
<http://www.ajnr.org/content/19/4/787>

This information is current as  
of August 13, 2024.

# Exophytic Primitive Neuroectodermal Tumor of the Spinal Cord

Demetrios Papadatos, Stephen Albrecht, Gerard Mohr, Raquel del Carpio-O'Donovan

**Summary:** We present a case of an exophytic spinal primitive neuroectodermal tumor that, radiologically, simulated an extramedullary nerve sheath tumor, meningioma, or metastatic tumor deposit. MR imaging provided discrete anatomic localization of the tumor, enabling exclusion of multicentricity in the brain and spinal cord.

Primitive neuroectodermal tumor (PNET) is a generic term used to describe a group of histologically indistinguishable neoplasms, including cerebellar medulloblastomas, that are located at various sites in the CNS. This is a relatively common, malignant CNS tumor in the pediatric age group that almost invariably arises intracranially. By the time it is discovered, it has often disseminated via subarachnoid spaces to involve other parts of the CNS, including the spinal cord. Primary PNET of the spinal cord, however, is rare, with only 13 cases documented in the literature (1-9).

## Case Report

A 23-year-old woman had been experiencing lower back pain for approximately 1 year. Ten days before admission, she noticed numbness on the plantar surface of both feet. Within days, the numbness progressed in an ascending fashion so that it reached the level of her knees. Physical examination revealed bilateral leg weakness and a T12-L1 sensory level. Her knee and ankle reflexes were brisk bilaterally and her toes were downgoing. A CT myelogram revealed an intradural, extramedullary mass at T10-11, which completely obstructed flow of contrast material. An MR study of the brain was normal. Spinal MR imaging revealed a 2-cm, well-circumscribed, posteriorly located, intradural, extramedullary lesion compressing the cord at the T-9 and T-10 levels (Fig 1A-D), and a small subarachnoid cyst was noted at the T-8 level (Fig 1B). A metastatic work-up was negative. The preoperative differential diagnosis included neural sheath tumor, meningioma, and solitary metastasis.

At surgery, the tumor was seen immediately upon incision of the dura. An ultrasonic aspirator was used to remove pinkish friable tumor tissue, which was adherent to the surrounding arachnoid and pia mater. Frozen section revealed a highly cellular malignant neoplasm, suggestive of lymphoma. Exten-

sive debulking was performed; however, since some tumor was noted to involve the posterior spinal cord, a thin rim of tumor was left behind to avoid any permanent neurologic deficit. An extensive duraplasty was then performed to assure decompression of the spinal cord.

Histologically, the tumor was composed of sheets of small blue cells without obvious differentiation (Fig 1E). There was a high mitotic rate, and many karyorrhectic cells were present. Immunohistochemically, we found diffuse, finely granular cytoplasmic material that was positive for synaptophysin throughout the tumor (Fig 1F). Staining with an antibody against glial fibrillary acid protein revealed reactive astrocytes but only a few positive tumor cells. Staining with various antibodies against lymphocyte markers (leukocyte common antigen, CD20, and CD23) was negative. Electron microscopy showed typical features of neuronal differentiation, including neurosecretory granules, cytoplasmic extensions containing microtubules, and poorly formed synapses. The final pathologic diagnosis was PNET with some neuronal differentiation. Given the absence of a primary brain tumor, it was concluded that this was a primary PNET of the spinal cord.

The patient received radiotherapy consisting of 36 Gy to the brain and spinal cord along with a 9-Gy boost to the involved area (T7-12). Three weeks after radiotherapy she began a chemotherapy protocol consisting of 10 cycles of a combination of cyclophosphamide, cis-platinum, and VP-16. Her leg strength recovered and her paresthesias disappeared except for some persistent but minor numbness on the plantar aspect of the feet. Follow-up contrast-enhanced MR imaging of the brain and spinal cord 1 year after surgery showed no evidence of tumor recurrence.

## Discussion

The term primitive neuroectodermal tumor (PNET) was defined by Hart and Earle in 1973 as a malignant, neuroepithelial, cerebral neoplasm found primarily in children (10). Microscopic findings consisted of a predominantly undifferentiated tumor with occasional differentiation along glial or neuronal lines. Such tumors arising in the cerebellum have historically been classified as medulloblastomas, largely because of the long-standing and conventionally accepted brain tumor classification proposed by Bailey and Cushing in 1926 (11). These authors originally defined a medulloblastoma as a densely cellu-

Received June 25, 1996; accepted after revision May 6, 1997.

From the Department of Diagnostic Radiology, Montreal General Hospital (D.P., R.D.C.-O.), and the Departments of Pathology (S..A.) and Neurosurgery (G.M.), Sir Mortimer B. Davis Jewish General Hospital, McGill University, Montreal, Quebec, Canada.

Address reprint requests to Raquel del Carpio-O'Donovan, MD, Department of Radiology, Montreal General Hospital, 1650 Cedar Ave, Montreal, Quebec, Canada H3G 1A4.

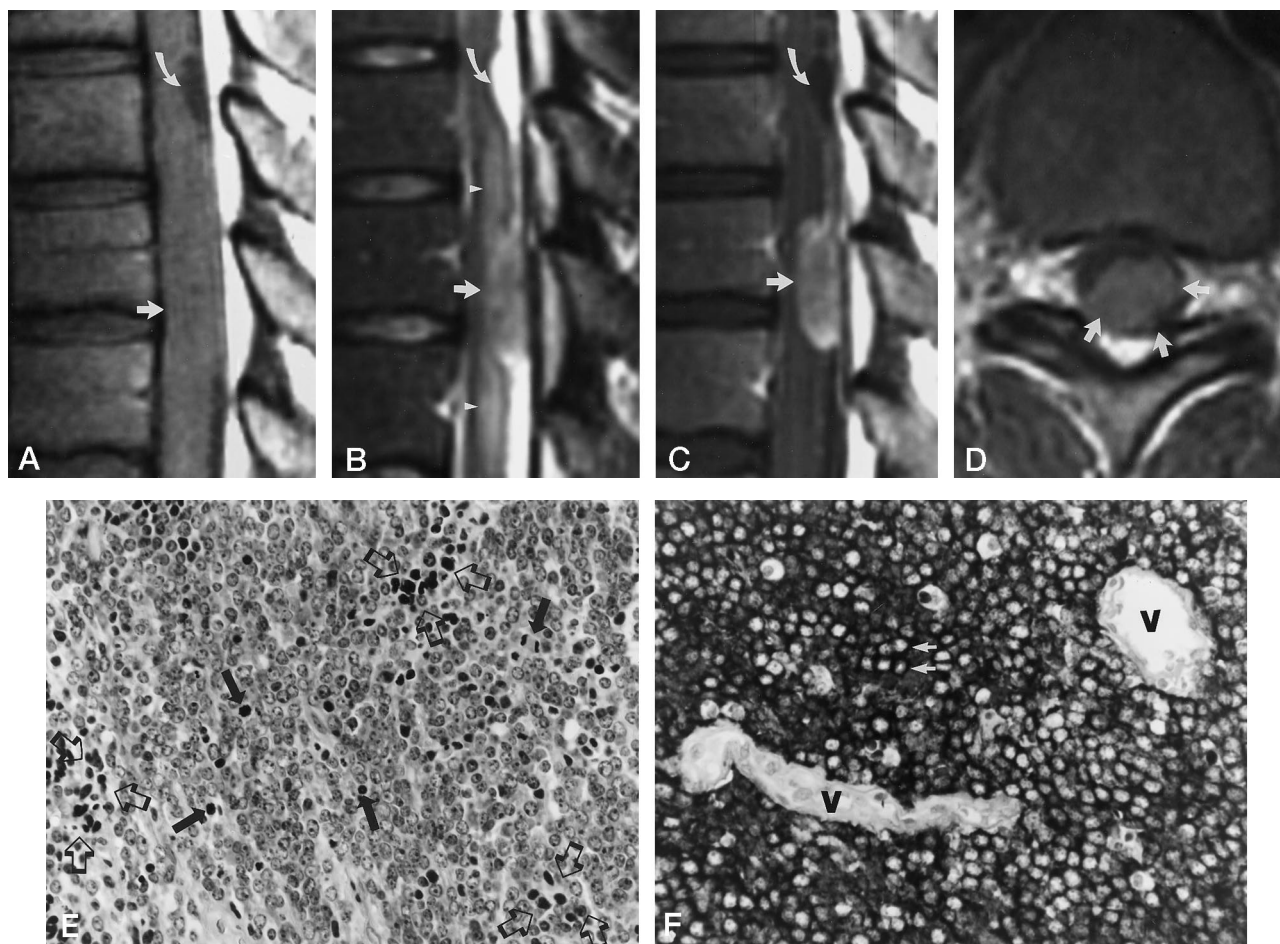


FIG 1. 23-year-old woman with lower back pain and lower-extremity numbness extending to the knees.

A-D, Sagittal T1-weighted (500/20/2) (A), T2-weighted (4000/80/2) (B), contrast-enhanced T1-weighted (C), and axial contrast-enhanced T1-weighted (D) MR images reveal a 2-cm, well-circumscribed, posterior, intradural extramedullary lesion compressing the cord at the T9-10 level (straight arrows) with adjacent central cord edema (arrowheads). The tumor enhances homogeneously to a moderate degree. Surgical findings confirmed the tumor epicenter to be extramedullary but suggested a spinal cord origin. Incidentally, an intradural spinal subarachnoid cyst was noted preoperatively (curved arrows), which disappeared after surgical incision of the tumor.

E, At conventional histologic examination, the tumor was seen to be composed of small cells with scant cytoplasm. Note several mitotic figures (solid arrows) and clusters of karyorrhectic and necrotic cells (open arrows) (hematoxylin-eosin). Magnification was 200 $\times$ .

F, Immunohistochemical analysis revealed a strong and diffuse cytoplasmic immunoreactivity of the tumor cells for synaptophysin as seen in the darkly stained rings of cytoplasm that surround the unstained nuclei (arrows). Vessels (V), which serve as a control, do not show immunoreactivity (as expected). Magnification was 400 $\times$ .

lar, midline cerebellar tumor that arises over the roof of the fourth ventricle and occurs mainly in children. Advances in immunohistochemistry and electron microscopy have since revealed that cerebellar medulloblastomas are in fact histologically indistinguishable from other tumors arising intracranially, which can only be differentiated on the basis of location in the CNS (12). In 1993, the World Health Organization (WHO) revised its original classification of pediatric brain tumors and recommended that the term PNET be used to describe cerebellar medulloblastomas and other neoplasms that are histologically indistinguishable from the latter but that are located at sites in the CNS other than the cerebellum (13).

Overall, PNET is a relatively uncommon tumor of the CNS. It is, however, the most common malignant CNS tumor in children. Although the new WHO classification of pediatric brain tumors considers

medulloblastomas only as definite PNETs, other tumors that can be histologically very similar to these, and thus considered PNETs, include primary cerebral neuroblastoma, pineoblastoma, ependymoblastoma, medulloepithelioma, and primary spinal PNET. A more detailed review of these tumors can be found elsewhere (13, 14).

In 1992, a literature review by Ogasawara et al (1) revealed 13 cases of spinal PNET. These tumors tend to occur in young males (approximately 3:1 male:female ratio, with 50% under 15 years and 85% under 30 years of age). The sites involved include the cauda equina and lower lumbar region (8/14 or 57%), the cervical cord (3/14 or 21%), and the thoracolumbar area (2/14 or 14%). Our case was unusual in that it occurred in a woman, was located at the thoracic cord level, and, of particular interest, was predominantly extramedullary in location. The differential diagnosis

of a solid thoracic intradural, extramedullary mass consists of nerve sheath tumors (ie, schwannoma, neurofibroma), meningiomas, and metastases (14). In the absence of brain lesions, PNET is understandably not usually considered preoperatively, and our case is particularly unusual because the PNET was predominantly exophytic. Although the tumor appeared to be characteristically extramedullary at both myelography and MR imaging, surgery confirmed that it did not originate from the dura mater but rather from the cord itself.

The definitive diagnosis of PNET relies on astute pathologic assessment. Light microscopy reveals a small, blue, round-cell malignant tumor that is predominantly undifferentiated (10). Neuronal, glial, or myogenic differentiation may be evident on standard hematoxylin-eosin sections alone or with special histologic stains. Immunohistochemical techniques and/or ultrastructural examination using electron microscopy will often reveal subtle attempts at differentiation along glial or neuronal lines that were not otherwise demonstrable (12).

In our case, MR imaging identified a rarely occurring intradural spinal subarachnoid cyst. These lesions can occur in response to inflammation, trauma, hemorrhage, and tumor, or as a developmental abnormality (15). Characteristically, most occur in the thoracic spine, arise near the septum posticum, are located posterior to the spinal cord, and communicate with the subarachnoid space (14). On MR images, they have the signal intensity of CSF on all sequences but may only be identified if they displace the spinal cord, typically anteriorly (16) (Fig 1A and B). In this case, CSF dynamics were reestablished after surgery, and the subarachnoid cyst disappeared.

Treatment of cerebellar PNETs consists of aggressive surgery followed by radiotherapy and chemotherapy. With the advent of adjuvant chemotherapy, survival rates may be as high as 82% at 5 years (17). Apart from the standard use of surgical resection and radiotherapy, however, the use of chemotherapy for treating patients with PNETs outside the cerebellum, particularly spinal PNETs, has been rather inconsistent (18). This is predominantly due to the rarity of such tumors and to the secondary lack of prospective protocols to address the benefits of specific chemotherapeutic regimens. Survival in the documented cases of spinal PNET from the time of diagnosis has ranged from 3 months to more than 3 years.

## Acknowledgment

We thank J. L. Vezina and N. Just for their contributions to the preparation of this case report.

## References

- Ogasawara H, Kiya K, Kurisu K, et al. **Intracranial metastasis from a spinal cord primitive neuroectodermal tumor: case report.** *Surg Neurol* 1992;37:307-312
- Smith DR, Hardman JM, Earle KE. **Metastasizing neuroectodermal tumors of the central nervous system.** *J Neurosurg* 1969;31:50-58
- Kosnik EJ, Boesel CP, Bay J, Sayers MP. **Primitive neuroectodermal tumors of the central nervous system in children.** *J Neurosurg* 1978;48:741-746
- Baum ES, Morgan ER, Dal Canto MC, West PM. **Review of experience with primitive neuroectodermal tumors of childhood.** In: Humphrey GB, Dehner LP, eds. *Pediatric Oncology I*. The Hague: Martinus Nijhoff; 1981:239-242
- Priest J, Dehner LP, Sung JH, Nesbit ME. **Primitive neuroectodermal tumors: embryonal gliomas of childhood, a clinicopathologic study of 12 cases.** In: Humphrey GB, Dehner LP, eds. *Pediatric Oncology I*. The Hague: Martinus Nijhoff; 1981:247-264
- Bruno LA, Rorke LB, Norris DG. **Primitive neuroectodermal tumors of infancy and childhood.** In: Humphrey GB, Dehner LP, eds. *Pediatric Oncology I*. The Hague: Martinus Nijhoff; 1981:265-267
- Kepes JJ, Belton K, Roessmann U. **Primitive neuroectodermal tumors of the cauda equina in adults with no detectable primary intracranial neoplasm: three case studies.** *Clin Neuropathol* 1985;4:1-11
- Sevick RJ, Johns RD, Curry BJ. **Primary spinal primitive neuroectodermal tumor with extraneural metastasis.** *Am J Nucl Radiol* 1987;8:1151-1152
- Freyer DR, Hutchinson RJ, McKeever PE. **Primary primitive neuroectodermal tumor of the spinal cord associated with neural tube defect.** *Pediatr Neurosci* 1989;15:181-187
- Hart MN, Earle KM. **Primitive neuroectodermal tumors of the brain in children.** *Cancer* 1973;32:890-897
- Bailey P, Cushing H. **A classification of tumors of the glioma group.** Philadelphia, Pa: Lippincott; 1926:21-40
- Rorke LB. **The cerebellar medulloblastoma and its relationship to primitive neuroectodermal tumors.** *J Neuropathol Exp Neurol* 1983;42:1-15
- Kleihues P, Burger PC, Scheithauer BW. **Histological typing of tumours of the central nervous system.** In: Sobin LH, ed. *World Health Organization International Histological Classification of Tumours*. Berlin: Springer; 1993:1-3, 27-30
- Osborne AG. **Tumors, cysts, and tumorlike lesions of the spine and spinal cord.** In: Patterson AS, ed. *Diagnostic Neuroradiology*. St Louis, Mo: Mosby; 1994:895-906
- Stern Y, Spiegelmann, Sadeh M. **Spinal intradural arachnoid cysts.** *Neurochirurgie* 1991;34:127-130
- Dietemann JH, de la Palavesa MMF, Kastler B, et al. **Thoracic intradural arachnoid cyst: possible pitfalls with myelo-CT and MR.** *Neuroradiology* 1991;33:90-91
- Packer RJ, Sutton LN, Goldwein JW, et al. **Improved survival with the use of adjuvant chemotherapy in the treatment of medulloblastoma.** *J Neurosurg* 1991;74:433-440
- Gaffney CC, Sloane JP, Bradley NJ, Bloom HJG. **Primitive neuroectodermal tumours of the cerebrum: pathology and treatment.** *J Neurooncol* 1985;3:23-33