

The **next generation** GBCA
from Guerbet is here

Explore new possibilities >

Guerbet | 

© Guerbet 2024 GUOB220151-A

AJNR

Use of a guide catheter as a temporary stent during microcatheter intervention.

J M Mathis and G Zoarski

AJNR Am J Neuroradiol 1998, 19 (5) 932-933
<http://www.ajnr.org/content/19/5/932>

This information is current as
of July 20, 2024.

Use of a Guide Catheter as a Temporary Stent during Microcatheter Intervention

John M. Mathis and Greg Zoarski

Summary: Placement of a guiding catheter through a tortuous, narrowed, or intrinsically small vessel may result in severe reduction or occlusion of blood flow. However, non-braided guiding catheters can be simply modified with a catheter hole punch to create a temporary stent. The stent reestablishes blood flow, which is routed through the distal segment of the guiding catheter while maintaining the guide platform for the introduction of microcatheters and devices necessary to perform intervention.

An appropriate guiding catheter placed in brachiocephalic vessels is an integral part of microcatheter and device introduction during neuroendovascular procedures. These procedures are complex and therefore often protracted. Hemodynamic flow reduction or occlusion due to guide catheter placement through a tortuous or narrowed vessel may result in ischemia or thrombosis (Fig 1A and B). In this circumstance, flow may be maintained while a guide catheter is in place by introducing multiple side holes through a nonbraided section of the catheter below the level of vascular restriction (Fig 1C). A catheter hole punch (Cook, Inc, Bloomington, Ind) is available for this purpose in sizes ranging from 0.020 to 0.094 inch. A blunt obturator is provided to clear the punch after each hole is produced. A rotating motion of the hole punch produces a "cookie-cutter" effect with the small circular catheter fragment remaining in the punch device (1, 2). Each fragment should be accounted for during this process. Holes are introduced in a spiral manner over a 1- to 2-cm segment for a total of 10 to 15 holes. The spiral rather than the through-and-through configuration of the holes tends to create less weakening of the catheter wall, which might lead to kinking in a tight vascular curve.

The guiding catheter, once modified, is introduced and used in the usual manner. The proximal side holes in the guide catheter must be positioned below the area of vascular occlusion. Reestablishment of blood flow should be demonstrated angiographically after placement of the guide catheter. Appropriate

systemic heparinization is typically used as well as a heparinized normal saline flush through the guiding catheter. The forward heparinized saline flush (4000 U of heparin per liter of normal saline) keeps the portion of the guide catheter from the hub to the side holes free of blood accumulation. Blood rapidly enters the side holes and continuously flushes the distal guide catheter segment. Flow through a standard lumen 6F guide catheter is adequate but more exuberant flow would be provided with a 7F standard lumen or 6F wide lumen system. Multiple side holes distal to the stenosis will also improve blood flow through the stent section while a microcatheter is in place (Fig 1D).

This device has been successfully used to bridge tortuous vertebral origins in three cases, allowing reestablishment of vertebrobasilar flow during basilar aneurysm coiling that lasted between 3 and 4 hours. These procedures were accomplished without evidence of ischemia or embolization. In each case, systemic heparinization was maintained with an initial IV bolus of 3000 to 5000 U followed by 1000 U per hour. The most commonly used guide catheter is the 6F Fasguide (Target Therapeutics, Fremont, Calif), which is hydrophilically coated and has a supple 10-cm nonbraided tip.

This method is anticipated to have a higher risk of embolic complications than the routine guide catheter, in which free flow of blood exists around the outside of the catheter while a heparinized saline flush is maintained through the central lumen. This technique, however, can be extremely helpful in providing nonocclusive access, not otherwise attainable, to vessels in which extreme proximal stenosis or tortuosity is present.

References

1. Johnsrude IS, Jackson DC, Dunnick NR, eds. *A Practical Approach to Angiography*. Little Brown; Boston: 1987:17-32
2. Abrams HJ, ed. *Abrams' Angiography: Vascular and Interventional Radiology*. Little Brown; Boston: 1983:187-204

Received January 31, 1997; accepted after revision July 17.

From the Department of Interventional Neuroradiology, Johns Hopkins Hospital, Baltimore (J.M.M.), and the Department of Neuroradiology, University of Maryland Medical System, Baltimore (G.Z.).

Address reprint requests to John M. Mathis, MD, Department of Neuroradiology, Nelson B-100, Johns Hopkins Hospital, 600 N Wolfe St, Baltimore, MD 21287.

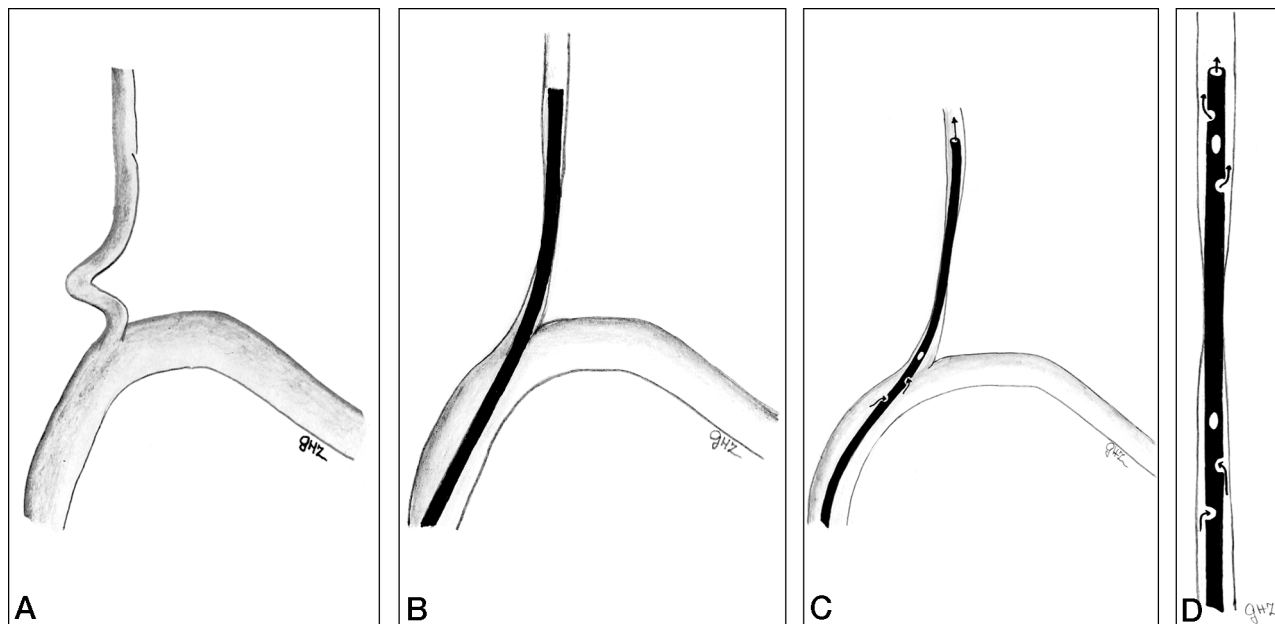


FIG 1. Use of a guide catheter as a temporary stent during microcatheter intervention.

- A, A tortuous proximal vertebral artery.
- B, A guide catheter traversing the proximal portion of the tortuous vertebral artery. Note straightening of the vertebral artery and coexistent flow restriction proximally through the vertebral artery.
- C, Flow is reestablished to the distal vertebral artery by a modification of the guide catheter. Multiple side holes placed in the guide catheter allow blood flow through the distal catheter to circumvent the vascular stenosis or occlusion.
- D, An increase in blood flow may be achieved through the guiding catheter if entry and exit holes are created above and below the region of flow restriction. This will allow more effective blood flow within the guiding catheter, especially when the device is being used as a platform for microcatheter delivery.