



ASNR Career Center

The Go-To Job Site for Neuroradiology Employers and Job Seekers
Start here: careers.asnr.org

AJNR

Development of a cavernous malformation of the brain.

P Maeder, F Gudinchet, R Meuli and N de Tribolet

AJNR Am J Neuroradiol 1998, 19 (6) 1141-1143

<http://www.ajnr.org/content/19/6/1141>

This information is current as
of December 7, 2023.

Development of a Cavernous Malformation of the Brain

P. Maeder, F. Gudinchet, R. Meuli, and N. de Tribolet

Summary: We report the appearance of a cavernous malformation associated with a developmental venous anomaly in a young boy 3 years after radiation therapy for a posterior fossa medulloblastoma. The presence of a stenosis of the venous drainage of the anomaly led us to postulate that venous restrictive disease, induced by radiation therapy, resulted in increased venous pressure and caused the formation of the cavernous malformation.

Cavernous malformations and developmental venous anomalies (DVAs) have been recognized with increasing frequency on CT and MR studies (1–4), and reports of an association between these two vascular malformations have become more commonplace (5, 6). We report the case of a young boy treated by surgery and radiotherapy for a medulloblastoma in whom MR demonstrated the *de novo* formation and growth of a cavernous malformation in close association with a DVA.

Case Report

A 14-year-old boy was treated for a medulloblastoma of the vermis (grade IIb) by means of complete resection of the tumor followed by radiotherapy of the brain and spinal cord (36 Gy to the whole brain and 54 Gy to the posterior fossa). Three years later, while the patient remained disease free without radiologic signs of dissemination or recurrence in the posterior fossa, a small intracerebral hemorrhagic lesion appeared in the deep white matter of the left hemisphere. This hemorrhage was located close to a DVA, which had been noted on the first preoperative MR study. This particular DVA consisted of a transcerebral vein draining a few small dilated medullary veins into the periventricular venous system. On subsequent follow-up MR studies, the small hemorrhage was seen to increase regularly in size over 2 years, finally achieving a multilobulated shape with heterogeneous signal on T2-weighted images (Fig 1). The radiologic features of what was first identified as a chronic hematoma appeared more and more similar to a cavernous malformation of the brain. Moreover, it seemed that on the T1-weighted MR images a stenosis of the deep collector vein of the DVA was present. Digital subtraction angiography suggested a stenosis of this vein (Fig 1E). Surgery was first delayed because the lesion was asymptomatic and in a precentral location; however, as it continued to increase in size, a total resection was performed by stereotactic craniotomy after local-

ization of the motor strip by means of functional MR imaging. The patient recovered without neurologic symptoms, and histologic examination confirmed a typical cavernous malformation consisting of endothelial-lined sinusoidal vascular spaces filled with thrombosed blood without intervening brain parenchyma.

Discussion

An association between cavernous malformation and DVA has often been reported (5). Surgical experience with excision of cavernous malformations associated with DVAs soon pointed to the necessity to preserve the venous draining component, as it became clear that a devastating venous infarct could result from the excision of this aberrant drainage of the normal surrounding brain (6). Indeed, DVAs, which are the most commonly encountered vascular malformations of the brain, appear to be congenital in origin, a contention supported by the absence of other drainage of normal brain parenchyma, their common appearance in childhood (7), and their occasional association with neuronal migration anomalies.

The prevalence of hemorrhagic complications of DVAs is a matter of controversy; however, it is generally agreed they have a relatively benign course. The origin of cavernous malformations of the brain is less clear. Until recently, cavernous malformations were essentially believed to be of congenital origin and classified with arteriovenous malformations (AVMs), capillary telangiectases, and DVAs as vascular malformations of the CNS. Cavernous malformations have also been classified in the so-called angiographically occult or cryptic vascular malformations category, together with slow-flow and thrombosed AVMs and telangiectases. The difficulty in distinguishing these entities after a hemorrhagic episode does not help to clarify their origin. Nevertheless, one particularly interesting feature of cavernous malformations is their propensity to increase in size over time. This growth is not due to tumoral cellular proliferation but seems to be caused by intracavernous and local intracerebral self-limited hemorrhagic

Received December 17, 1996; accepted after revision August 8, 1997.

From the Departments of Radiology/Interventional Radiology (P.M., F.G., R.M.) and Neurosurgery (N.D.T.), CHUV, University Hospital, Lausanne, Switzerland.

Address reprint requests to P. Maeder, MD, Department of Radiology and Interventional Radiology, CHUV, University Hospital, CH-1011 Lausanne, Switzerland.

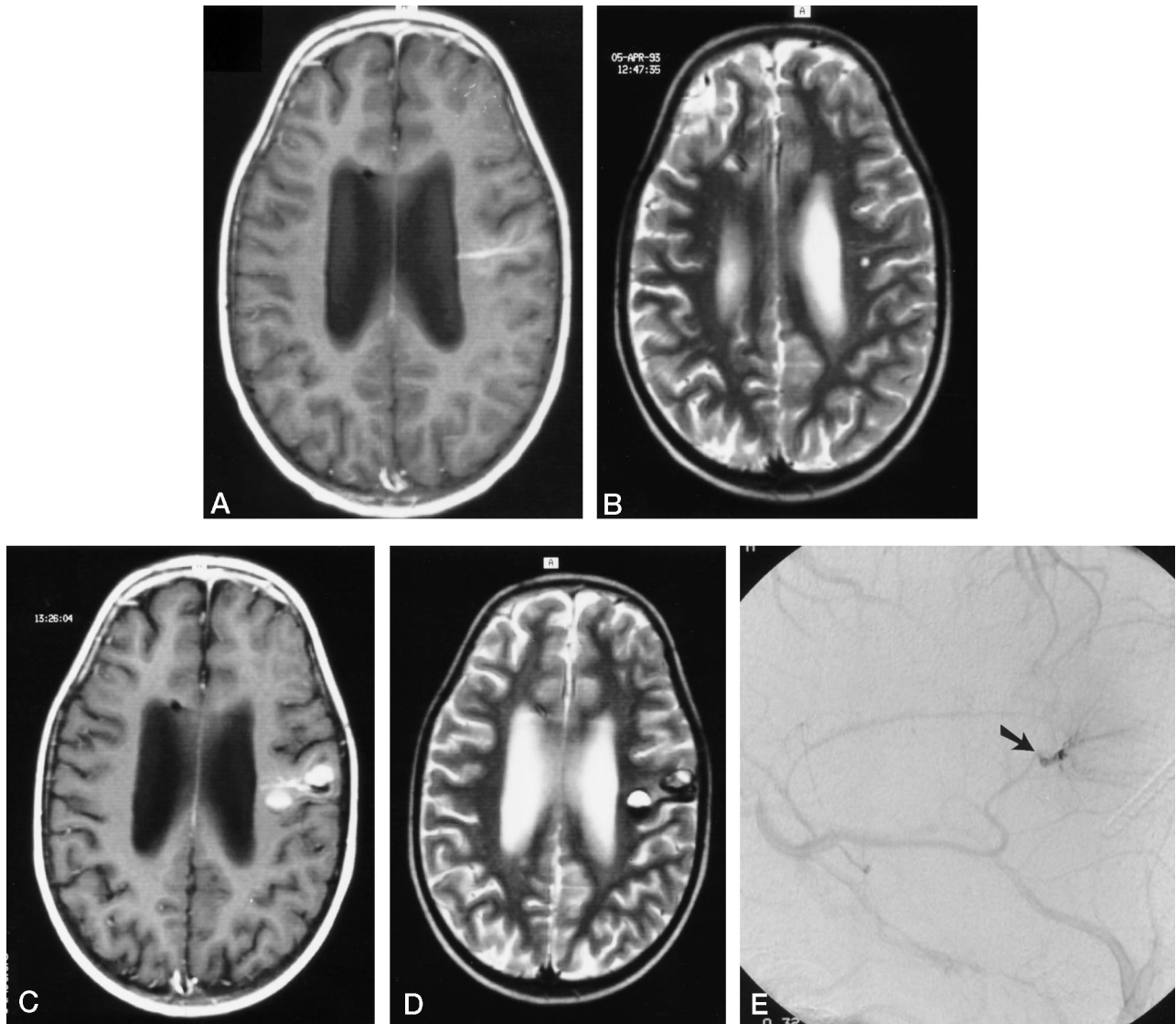


FIG 1. 14-year-old boy treated 3 years earlier with surgery and radiotherapy for medulloblastoma of the vermis presented with intracerebral hemorrhagic lesion in proximity to a DVA.

A–D, Contrast-enhanced T1-weighted (600/15/2 [TR/TE/excitations]) (A and C) and fast spin-echo T2-weighted (3500/93/1) (B and D) transverse MR images show the increase in size over time of the hemorrhagic lesion close to the DVA, finally achieving the radiologic features of a cavernous malformation 3 (A and B) and 5 (C and D) years after radiation therapy.

E, Magnified lateral view in the venous phase of digital subtraction angiogram shows a narrowing of the deep collective vein of the DVA as it enters the deep venous system (arrow).

events (8). Reports of intermediate stages between hematoma and cavernous malformation with partial endothelialization of a chronic hematoma and hemorrhagic angiogenic proliferation support this mechanism of growth. Intermittent diapedetic oozing of blood through defective capillaries without disruption of the vessel wall has been proposed by Wilson (9). If successive bleeding or diapedesis of red blood cells through normal capillaries or venules is indeed the factor that initiates cavernous malformation growth, it is still unclear what triggers such hemorrhagic events. The answer is probably in the study of flow dynamics of cavernous malformations, of which little is known. Surgeons have consistently reported that small arteries, and at least one abnormal draining vein, are always found during resection of cavernous

malformations; therefore, there is flow in those malformations even if it is very sluggish. The pressure has also been recorded in cavernous malformations during surgery and found to be substantially higher than cortical venous pressure (10). Dillon et al (Dillon WP, Wilson CB, Hieshima GB, Rosenau W, "Hemorrhagic Venous Malformations: The Role of Venous Restriction," presented at the annual meeting of the American Society of Neuroradiology, St Louis, June 1992) were the first to measure elevated pressure in DVAs associated with hemorrhagic or cryptic vascular malformations. They found a high percentage of venous stenosis of the collector vein in these patients and thus postulated that a higher pressure due to venous restrictive disease could be the cause of hemorrhage from a DVA with subsequent formation of a

cavernous malformation. This theory would favor the possibility that some cavernous malformations are in fact acquired lesions. Indeed, there is evidence of the de novo appearance of cavernous malformations. These have mostly been described in familial cases, but they have also been reported in one case in association with a craniopharyngioma and in another case of multiple cryptic malformations associated with an extensive DVA.

We believe that the findings in our case support the theory of Dillon et al (ASNR meeting, 1992) in that the DVA was in close association with the hemorrhagic lesion, which appeared first as a chronic hematoma then increased in size and finally showed the complex multilobulated features of a cavernous malformation, which was confirmed by histologic examination. The stenosis of the collector vein could be recognized on MR images but was subsequently characterized more precisely at conventional angiography.

What is the role played by radiotherapy in the case described? It has been shown that radiotherapy produces hyalinization and fibrinoid necrosis of small arteries and arterioles together with narrowing of the lumen and endothelial proliferation. It is also responsible for the so-called mineralizing microangiopathy with dystrophic calcifications often encountered in children after combined chemotherapy and cranial irradiation. If damage to small and medium-sized arteries is more common in late radiation injury of the brain, damage to large arteries can also be seen with fibrinoid necrosis of the vessels or, more commonly, in arteriosclerosis with vascular narrowing and occlusion. Moya-moya-like features have been reported in young patients treated for craniopharyngioma. It seems also that radiotherapy can induce the formation of capillary telangiectasia by altering the endothelium of veins, producing venous occlusive disease. Vascular structures appearing to be ectatic venules and capillaries surrounded by a variable amount of gliosis have been identified in patients presenting with acute symptomatic parenchymal hemorrhage more than 2 years after brain irradiation (11). Careful examination of the radiation-injured brain with serial sections has shown that the most dramatic vessel changes occur on the venous side, with dilated and occluded veins of the thick wall producing veno-occlusive disease (12).

Conclusion

Small petechial hemorrhage or diapedesis of red cells in response to venous endothelial damage may result in stimulation of fibroblasts and fragile capillaries prone to recurrent hemorrhage, leading to the development of a cavernous malformation. In our case, there was evidence of a preexisting venous malformation, but changes induced by radiation treatment of this malformation probably caused its transformation with the appearance of an associated cavernous malformation. These findings suggest that radiotherapy plays a role in the formation and evolution of cryptic vascular malformations of the brain by means of induced venous restrictive disease and alterations in small venules and capillary walls.

References

1. Simard JM, Garcia-Bengochea F, Ballinger WE, Parker Mickle J, Quisling RG. **Cavernous malformation: a review of 126 collected and 12 new clinical cases.** *Neurosurgery* 1986;18:162-172
2. Lasjaunias P, Burrows P, Planet C. **Developmental venous anomalies (DVA): the so-called venous angioma.** *Neurosurg Rev* 1986;9:233-244
3. Valavanis A, Wellauer J, Yasargil MG. **The radiological diagnosis of cerebral venous angioma: cerebral angiography and computed tomography.** *Neuroradiology* 1983;124:193-199
4. Ostertun B, Solymosi L. **Magnetic resonance angiography of cerebral developmental venous anomalies; its role in differential diagnosis.** *Neuroradiology* 1993;35:97-104
5. Rigamonti D, Spetzler RF. **The association of venous and cavernous malformations: report of four cases and discussion of the pathophysiological, diagnostic and therapeutic implications.** *Acta Neurochir* 1988;92:100-105
6. Sasaki O, Tanaka R, Koike T, Koide A, Koizumi T, Ogawa H. **Excision of cavernous malformation with preservation of coexisting venous angioma.** *J Neurosurg* 1991;75:461-464
7. Awad IA, Robinson JR, Mohanty S, Estes ML. **Mixed vascular malformations of the brain: clinical and pathogenetic considerations.** *Neurosurgery* 1993;33:179-188
8. Pozzati E, Giuliani G, Nuzzo G, Poppi M. **The growth of cerebral cavernous malformations.** *Neurosurgery* 1989;25:92-97
9. Wilson CB. **Cryptic vascular malformations.** *Clin Neurosurg* 1992;38:49-84
10. Little JR, Awad IA, Jones SC, Ebrahim ZY. **Vascular pressures and cortical blood flow in cavernous malformation of the brain.** *J Neurosurg* 1990;73:555-559
11. Poussaint TY, Siffert J, Barnes PD, et al. **Hemorrhagic vasculopathy after treatment of central nervous system neoplasia in childhood: diagnosis and follow-up.** *AJNR Am J Neuroradiol* 1995;16:693-699
12. Gaensler EHL, Dillon WP, Edwards MSB, Larson DA, Rosenau W, Wilson CB. **Radiation-induced telangiectasia in the brain simulates cryptic vascular malformations at MR imaging.** *Radiology* 1994;193:629-636