

Measuring Diffusion of Solutes into Intervertebral Disks with MR Imaging and Paramagnetic Contrast Medium

Canh Nguyen-minh, Victor M. Haughton, R. Anne Papke, Howard An, and Steven C. Censky

BACKGROUND AND PURPOSE: Experimental studies have shown that solutes diffuse more slowly into degenerated intervertebral disks than into normal disks. A noninvasive clinical study of diffusion in intervertebral disks is not generally available. Our purpose was to evaluate contrast-enhanced MR images to study diffusion in normal and degenerated lumbar intervertebral disks.

METHODS: The change in signal intensity (as a proportion of baseline signal intensity) was calculated in lumbar intervertebral disks on MR images obtained before and after injection of intravenous contrast medium in 15 patients with low back pain. The intervertebral disks were classified as normal or degenerated on the basis of the MR appearance. Postoperative disks and degenerative intervertebral disks with a "high-intensity zone" were excluded. The changes in signal intensity as a proportion of baseline signal intensity were compared in degenerated disks and normal disks and the differences tested for statistical significance.

RESULTS: After intravenous administration of a gadolinium complex, signal intensity in normal intervertebral disks increased an average of 36% of baseline. In intervertebral disks with signs of degeneration, it increased an average of 21% of baseline. The difference was significant.

CONCLUSION: The study shows that diffusion into normal human lumbar intervertebral disks can be evaluated with MR imaging combined with intravenous contrast medium. With suitable MR techniques, the relationship between diffusion and disk degeneration, and the effect of trauma, drugs, and nutrition on disk degeneration can be studied noninvasively.

Since the intervertebral disk is avascular, the transport of nutrients to and waste products from the disk occurs by the process of diffusion. The energy for the metabolism of approximately 8000 cells in each cubic millimeter of disk and for the intracellular synthesis of procollagen and proteoglycans depends on the diffusion of nutrients into the disk. Impaired diffusion has been found in degenerated intervertebral disks and has been suggested as a cause of degeneration (1). The relationship between disk degeneration and diffusion has been studied by counting radioactivity in samples of disk after an isotope is injected intrave-

nously (2-8). Noninvasive methods of studying diffusion in intervertebral disks are not generally available.

Paramagnetic contrast medium injected intravenously has been reported to shorten the T1 of intervertebral disks (9-11). The slowly increasing signal intensity (on T1-weighted images) in the intervertebral disk after intravenous injection of a paramagnetic contrast medium results from diffusion of the contrast medium into the disk. MR studies suggest that diffusion into the disk is affected by the type of contrast medium and the state of the cartilage in the disk. The ionic paramagnetic contrast medium gadopentetate dimeglumine diffuses less rapidly into the disk than the nonionic media gadoteridol or gadodiamide, probably because the charges on the ionic medium slow its entry into cartilage, which contains a high concentration of fixed negative charges (9). In addition, diffusion is slower in mature disk cartilage than in immature disk cartilage, probably because of the amount of collagen in the matrix and/or the concentration of fixed negative charges (10).

Because the effect of intravenously injected paramagnetic contrast medium on the signal intensities of

Received September 17, 1997; accepted after revision June 1, 1998.

From the Departments of Radiology (C.N., V.M.H., R.A.P., S.C.C.) and Orthopaedic Surgery (H.A.), Medical College of Wisconsin, Milwaukee.

Address reprint requests to Victor M. Haughton, MD, Department of Radiology, Medical College of Wisconsin, Froedtert Memorial Lutheran Hospital, 9200 W Wisconsin Ave, Milwaukee, WI 53226.

the disk can be measured, MR imaging may provide a noninvasive clinical method for measuring diffusion into human disks. An effect on normal human intervertebral disks of clinical doses of paramagnetic contrast media has been detected (12). The purpose of this study was to compare diffusion into normal and degenerative disks in a group of patients who received contrast medium for spine imaging.

Methods

Between March 1994 and September 1995, 10 men and five women (ages 23 to 56 years; mean age, 36 years) with continuing back pain after laminectomy were enrolled in a phase III FDA study to evaluate gadoteridol (ProHance, Bracco Diagnostics, Princeton, NJ) as a contrast medium for MR imaging. The protocol for the FDA study required sequential injections of contrast medium to measure the effect of each dose, but in this study only the effect of the cumulative dose was tabulated.

Each patient was imaged in a 0.5-T MR imager with the same experimental protocol. Localizer images and then sagittal fast spin-echo images were acquired with the following parameters: 4000/108/2 (TR/TE/excitations), echo train length of 8, variable bandwidth, 256×256 matrix, 5-mm-thick sections, 1-mm spacing, and a 28-cm field of view (FOV). Sagittal T1-weighted images were obtained before administration of contrast medium, 10 minutes after injection of 0.1 mmol/kg intravenous gadoteridol, and 5 minutes after injection of an additional 0.2 mmol/kg intravenous gadoteridol with imaging parameters of 600/20/2, an acquisition matrix of 512×256 , 5-mm-thick sections, 0.5-mm spacing, and a 28-mm FOV. The time between injections was 15 minutes. Transmit and receive were not adjusted between imaging sequences.

The MR images were reviewed and those with evident motion or artifacts were excluded. On the basis of their MR appearance on the sagittal and axial images, intervertebral disks were classified as normal or degenerative. Disks with normal height and signal intensity and no evidence of radial tear, bulging annulus, or herniated nucleus pulposus were classified as normal. Disks with diminished height or signal intensity or abnormal disk margins were classified as degenerative. Disks at the level of a laminectomy or laminotomy were excluded. Disks that had severely reduced height that precluded accurate measurements were excluded. Degenerative disks with a "high-intensity zone" (13) in the annulus fibrosis on T2-weighted images or with a linear zone of contrast enhancement on sagittal images after injection of contrast medium (14) were excluded.

Signal intensities of disks were measured on midline sagittal images before contrast medium was administered and after the second dose of contrast medium. An investigator who was blinded to the objectives of the study placed cursors adjacent to but not overlapping the low signal intensity in the superior and inferior endplates and halfway between the anterior and posterior longitudinal ligaments (Fig 1). The change in signal intensity as a proportion of baseline signal intensity was calculated for each cursor location. Average values of the change in signal intensity were calculated. Differences between measurements in the normal and degenerated disks were tested for significance with an F test.

Results

In the 15 patients, 15 disks were excluded because of previous diskectomy and 29 because of artifacts or advanced degeneration. Eighteen normal disks and 13 degenerative intervertebral disks were measured. Of the 13 degenerative disks, six with evidence of a

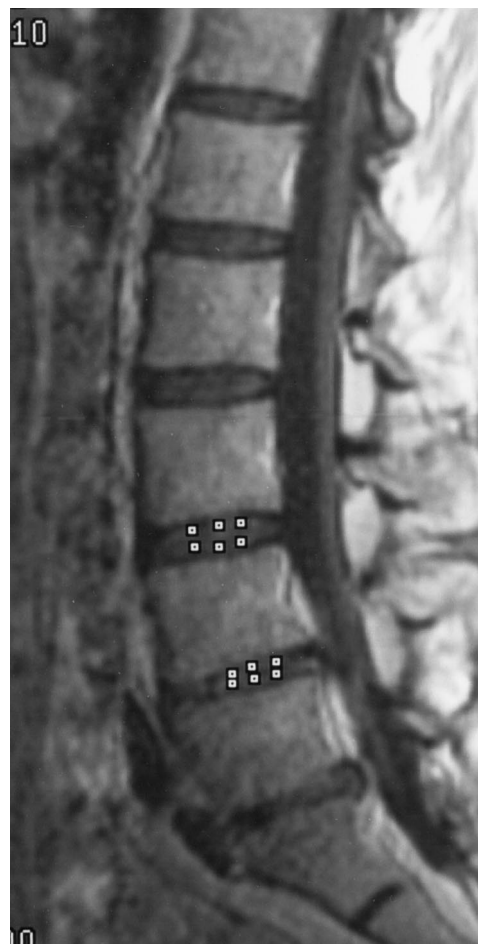

FIG 1. Sagittal MR image of the lumbar spine shows the position of cursors used to measure changes in signal intensity in the intervertebral disk. Six cursors are illustrated in the L4-L5 (normal) disk and the L5-S1 (degenerative) disks. For this study, the signal intensity changes in the central cursors were tabulated. Variance may be reduced by using multiple cursors; for example, all six of the cursors illustrated. A cursor near the center of the disk (not shown), farther from the endplate, detects a smaller change in signal intensity after intravenous administration of contrast medium.

high-intensity zone or radial tear were excluded. In the group without a high-intensity zone, five had evidence of a bulging annulus and two had evidence of a herniated disk.

In the normal disks, the average increase in signal intensity in the intervertebral disks at the endplates was 0.36 with a variance of 0.11 (Table). For the degenerative disks, the average signal intensity change at the endplates was 0.21. The difference between the signal intensity changes at the endplates in normal disks and the degenerative disks was significant ($P = .03$, F test).

In the four subjects in whom both a normal disk and a degenerated intervertebral disk were measured, the signal intensity changes were smaller in each of the degenerative disks than in the normal disks (Fig 2). The difference was significant ($P = .05$, Wilcoxon sign test).

Change in signal intensity in normal and degenerative intervertebral disks after intravenous injection of contrast medium

	Patient No.	Age	Level	Change	
Normal disks	2	36	12-1	0.89	
	2	36	3-4	0.25	
	4	34	3-4	0.15	
	4	34	5-1	0.30	
	5	35	3-4	0.60	
	7	23	2-3	0.09	
	7	23	3-4	0.35	
	9	50	3-4	0.20	
	11	36	4-5	0.12	
	12	43	2-3	0.43	
	13	34	3-4	-0.05	
	14	33	1-2	0.95	
	17	40	4-5	0.35	
	18	33	3-4	0.55	
	19	33	4-5	1.05	
	20	44	4-5	-0.15	
	21	37	1-2	-0.05	
	23	68	1-2	0.45	
		Average		0.36	
		Variance		0.11	
	Degenerative disks	5	35	5-1	0.32
		14	33	5-1	0.35
		15	45	4-5	0.42
1		52	4-5	-0.08	
12		43	4-5	0.09	
7		23	4-5	0.02	
6		43	4-5	0.36	
		Average		0.21	
	Variance		0.03		

Discussion

This study was performed to determine the feasibility of measuring diffusion in intervertebral disks noninvasively with MR imaging and a paramagnetic contrast medium. The study shows that signal intensity changes can be measured in normal and degenerative intervertebral disks after intravenous injection of contrast medium and suggests that paramagnetic contrast media diffuse into normal and degenerative intervertebral disks at different rates.

Our study indicates the need for refinements in data acquisition to obtain clinically useful measurements of diffusion into disks. A 0.5-T imager was used in our study for logistic reasons. Use of a higher-field-strength MR unit is preferable because of its increased sensitivity to T1 shortening by contrast medium (15). A period of at least 40 minutes between intravenous injection of contrast medium and collection of image data would have increased the signal intensity change to more optimal levels (10). We used a shorter interval because it was specified by the FDA protocol. We used a nonionic medium, which diffuses more rapidly in the disk than do the ionic media (10, 11), and a dose of 0.3 mmol/kg. We measured signal intensity changes near the osseous endplate rather than in the middle of the disk, where signal intensity increases more slowly. Because we used a small cursor, variance in our data was high, resulting in occa-

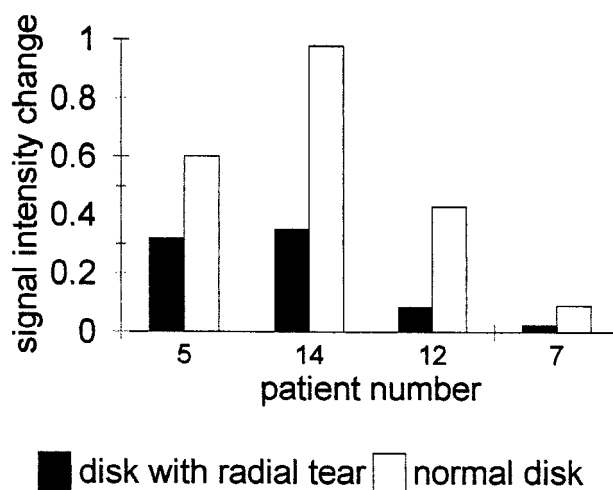


FIG 2. Signal intensity changes in normal and abnormal disks in the four patients with both a normal and a degenerative disk (without a high-intensity zone). Although enhancement is variable from patient to patient, increases in signal intensity are consistently smaller in the degenerative disks.

sional decreases in signal intensity after contrast medium administration. Multiple cursors (as illustrated in Fig 1) or other strategies to increase the volume of disk sampled may reduce variance. Stratification of results by disk type may be needed to avoid confounding effects. We excluded disks with a high-intensity zone on the assumption that they might have accelerated signal intensity changes due to granulation tissue in the annular tear. We did not use an internal reference or control, which might have been beneficial because of large interpersonal variation. Additional limiting factors in this study were the small number of cases and the highly selected sample.

A noninvasive means of measuring diffusion into human intervertebral disks has been an ongoing objective of research (1-5). MR imaging with intravenous contrast medium may provide the solution. Studying diffusion into intervertebral disks may clarify some aspects of disk degeneration, since delayed diffusion into intervertebral disks may be a cause or a marker of disk degeneration. This clinical study shows the feasibility of measuring the effect of diffusion in human intervertebral disks.

Conclusion

Signal intensity changes can be measured with MR imaging in normal and degenerative human lumbar intervertebral disks after intravenous injection of contrast medium. Smaller changes are measured in degenerative disks than in normal-appearing disks. MR imaging can be used to study diffusion of solutes into intervertebral disks.

References

- Urban JPG, Holm S, Maroudas A, Nachemson A. Diffusion of small solutes into the intervertebral disk: an in vivo study of solute transport. *Clin Orthop* 1977;129:101-114

2. Maroudas A. **Biophysical chemistry of cartilaginous tissues with special reference to solute and fluid transport.** *Biorheology* 1975;12:233-248
3. Maroudas A. **Distribution and diffusion of solutes in articular cartilage.** *Biophys J* 1970;10:365-379
4. Maroudas A. **Nutrition and metabolism of the intervertebral disk.** In: Ghosh P, ed. *The Biology of the Intervertebral Disk.*, Boca Raton, FL: CRC; 1983;11:1-38
5. Maroudas A, Stockwell RA, Nachemson A, Urban JPG. **Factors involved in the nutrition of the human lumbar intervertebral disk: cellularity and diffusion of glucose in vitro.** *J Anat* 1975;120:113-130
6. Stairman JW, Holm S, Urban JPG. **Factors influencing oxygen concentration gradients in the intervertebral disk: a theoretical analysis.** *Spine* 1991;16:444-449
7. Urban JPG, Holm S, Maroudas A, Nachemson A. **Diffusion of small solutes into the intervertebral disk: an in vivo study.** *Biorheology* 1978;15:203-223
8. Urban JPG, Holm S, Maroudas A, Nachemson A. **Nutrition of the intervertebral disk: effect of fluid flow on solute transport.** *Clin Orthop* 1982;170:296-302
9. Ibrahim MA, Haughton VM, Hyde JS. **Enhancement of intervertebral disks with gadolinium complexes: comparison of an ionic and nonionic medium in an animal model.** *AJNR Am J Neuroradiol* 1994;15:1907-1910
10. Ibrahim MA, Haughton VM, Hyde JS. **Effect of disk maturation on diffusion of low-molecular-weight gadolinium complexes: an experimental study in rabbits.** *AJNR Am J Neuroradiol* 1995;16:1307-1311
11. Ibrahim MA, Jesmanowicz A, Hyde JS, Estkowski L, Haughton VM. **Contrast enhancement of normal intervertebral disks: time and dose dependence.** *AJNR Am J Neuroradiol* 1994;15:419-423
12. Akansel G, Haughton VM, Papke RA, Censky S. **Enhancement of normal human intervertebral discs with gadoteridol.** *AJNR Am J Neuroradiol* (in press)
13. Aprill C, Bogduk N. **High intensity zone: a diagnostic sign of painful lumbar disc on magnetic resonance imaging.** *Br J Radiol* 1992;65:361-369
14. Ross SJ, Modic MT, Masaryk YJ. **Tears of the annulus fibrosus: assessment with Gd-DTPA-enhanced MR imaging.** *AJR Am J Roentgenol* 1990;154:159-164
15. Lindsey RO, Yetkin FZ, Prost R, Haughton VM. **Effect of dose and field strength on enhancement with paramagnetic contrast media.** *AJNR Am J Neuroradiol* 1994;15:1849-1852-