AJNR

Giant unclippable aneurysms: treatment with detachable balloons.

G Debrun, A Fox, C Drake, S Peerless, J Girvin and G Ferguson

AJNR Am J Neuroradiol 1981, 2 (2) 167-173
http://www.ajnr.org/content/2/2/167

Giant Unclippable Aneurysms: Treatment with Detachable Balloons

G. Debrun[1]
A. Fox[1]
C. Drake[2]
S. Peerless[2]
J. Girvin[2]
G. Ferguson[2]

Nine cases of giant unclippable aneurysms treated with the detachable balloon technique are reported. Adjunctive surgical bypass procedures and arterial ligation were also carried out in four and one cases, respectively. All the patients tolerated occlusion of the carotid artery (eight cases) or of both vertebral arteries (one case). Three patients developed neurologic complications: two transient and one permanent (blindness in one eye). The complications occurred when attempts were made to occlude the aneurysm lumen only to preserve the carotid blood flow. Permanent occlusion of the carotid artery appears safer than aneurysm obliteration. Surgical procedures are necessary if the patient does not tolerate permanent occlusion of the artery or if occlusion of the artery is insufficient to obtain thrombosis of the aneurysm.

Some cavernous carotid artery aneurysms, giant ophthalmic artery aneurysms, giant aneurysms of the bifurcation of the internal carotid artery, and certain giant basilar artery aneurysms cannot be surgically clipped. Occlusion of the internal carotid artery by ligation or by a Selverstone clamp may produce thrombosis of such unclippable carotid aneurysms [1]. However, it may be easier to occlude the carotid artery with a detachable balloon positioned close to the neck of the aneurysm. The ideal would be to occlude the aneurysm itself with a detachable balloon while preserving the arterial blood flow. We report our experience with nine cases of unclippable giant aneurysms that were successfully treated with the detachable balloon technique. Five patients had adjunctive surgical procedures. This technique was first used by Serbinenko [2] and subsequently by one of us [3].

Materials and Methods

The nine patients are summarized in table 1. They were 12–56 years old (average, 34 years). There were six females and three males. Four aneurysms originated from the cavernous carotid artery, two from the ophthalmic artery, two were bifurcation carotid aneurysms, and one was a prepontine basilar aneurysm according to the classifications of both Drake [1] and Pia [4].

The symptoms were classical. With cavernous carotid artery aneurysms were oculomotor nerve palsies or severe retroorbital pain. With one of the supraclinoid carotid aneurysms was progressive loss of vision. The two other carotid bifurcation aneurysms and the basilar aneurysm had subarachnoid hemorrhages. One ophthalmic aneurysm was unusual, with transient ischemic attacks and a small internal capsule infarct.

All procedures and angiographic examinations were carried out by the transfemoral arterial route. The detachable balloon techniques used were described in a previous publication [3]. The balloons were attached to Teflon catheters with elastic ligatures and detached using a second, coaxial polyethylene catheter. Balloon size was 0.5–2.0 ml. The level of the carotid siphons was easily reached with the Teflon catheters.

Received May 1, 1980; accepted after revision October 16, 1980

[1]Department of Diagnostic Radiology, University Hospital, P.O. Box 5339, Postal Station A, London, Ontario, Canada N6A 5A5. Address reprint requests to G. Debrun.

[2]Department of Neurosurgery, University Hospital, London, Ontario, Canada N6A 5A5.

AJNR 2:167–173, March/April 1981
0195-6108/81/0022-0167 $00.00

TABLE 1: **Summary of Cases**

Case No.	Age, Gender	Arterial Location	STA–MCA Bypass	Surgical Clipping	ICA Occlusion	Complications	Final Result
1	56, F	Cavernous	–	–	+	None	Good
2	20, F	End of ICA	+	–	+	None	Good
3	46, F	Cavernous	–	–	–	Transient R arm weakness and dysphasia; recovery	Good
4	42, F	Cavernous	–	–	–, +	Transient drift R arm and dysphasia, III and VI	Good
5	30, M	Cavernous	–	–	–, +	Total ophthalmoplegia, blindness of left eye, brain abscess	Blindness, left eye
6	35, F	Ophthalmic	+	–	+	None	Good
7	30, F	End of ICA	+	A1	+	None	Good
8	38, M	End of ICA	+	A1	+	None	Good
9	12, F	Basilar	–	+ R vertebral	Balloon occlusion, L vertebral	None	Good

Note.—STA–MCA = superficial temporal artery–middle cerebral artery, ICA = internal carotid artery, + = performed, – = not performed.

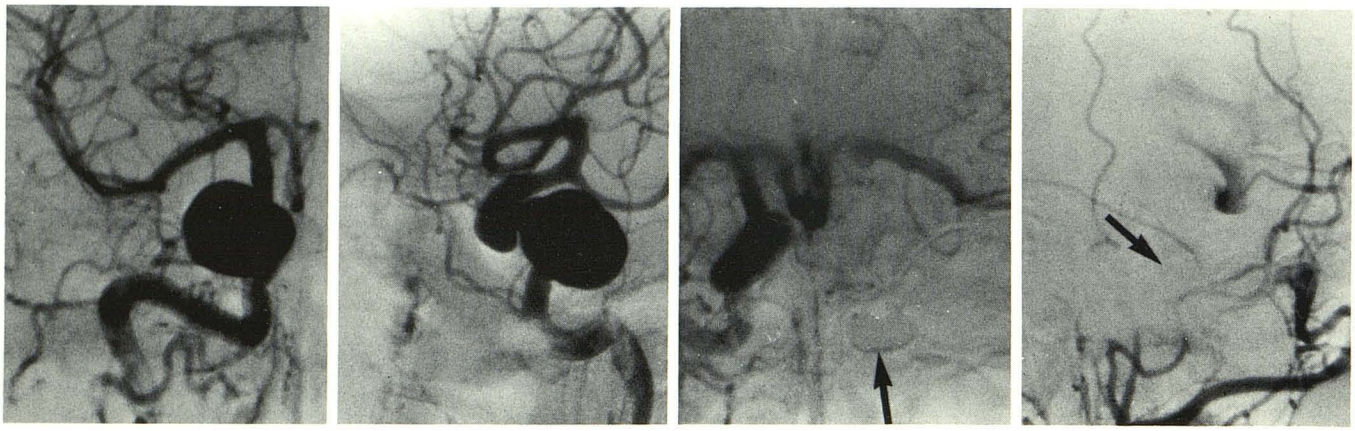

A B C D

Fig. 1.—Case 1. **A**, Anteroposterior view. Giant right cavernous carotid artery aneurysm. **B**, Lateral view before treatment. **C**, Contralateral carotid angiogram. Balloon occlusion of right carotid siphon below aneurysm (*arrow*). Cross-filling without retrograde filling of aneurysm. **D**, Right external carotid angiogram. After occlusion of siphon with detachable balloon (*arrow*). Right internal carotid artery fills retrogradely through ophthalmic artery without any opacification of aneurysm.

Case Reports

Case 1

A 56-year-old woman with double vision and a sixth nerve palsy had a giant right cavernous carotid aneurysm (figs. 1A and 1B). A left carotid angiogram with compression of the right carotid artery showed good cross filling through the anterior communicating artery. The vertebral angiogram with compression of the right carotid artery demonstrated filling of the right middle cerebral artery through the posterior communicating artery. A cerebral blood flow study suggested that the right carotid artery could be permanently occluded. (We used a modification of the Glasgow technique in three patients to assess cerebral blood flow. The Glasgow group measured it intraoperatively before and after temporary internal carotid artery occlusion by direct carotid injection of ^{133}Xe [5]. We measured blood flow using ^{133}Xe inhalation and a computer-linked 36 probe multidetector system to compare flow values in the hemisphere of interest before and after manual occlusion of the internal carotid artery [6]. Intolerance to carotid occlusion is assumed if mean hemispheric flow decreases by more than 25% during such occlusion. Unfortunately, there is no way of predicting the risk of an embolus after occlusion [7].)

At the time of treatment, the balloon easily entered the sac of the aneurysm but when it was fully inflated it bulged into the siphon and occluded it because the neck of the aneurysm was so wide. The balloon was deflated, gently retracted into the siphon below the neck of the aneurysm, inflated with Conray 60 and detached, permanently occluding the carotid artery (figs. 1C and 1D).

Left carotid angiography showed the balloon (fig. 1C) in the right carotid siphon with good filling of the right middle cerebral artery and no filling of the aneurysm. The aneurysm also did not fill on right external carotid angiography (fig. 1D), even on delayed subtraction films. The patient tolerated the occlusion of the carotid artery well and the sixth nerve palsy disappeared. No further treatment was considered necessary.

Case 2

A 20-year-old man with progressive loss of vision of his right eye had a giant fusiform aneurysm of the supraclinoid part of the internal

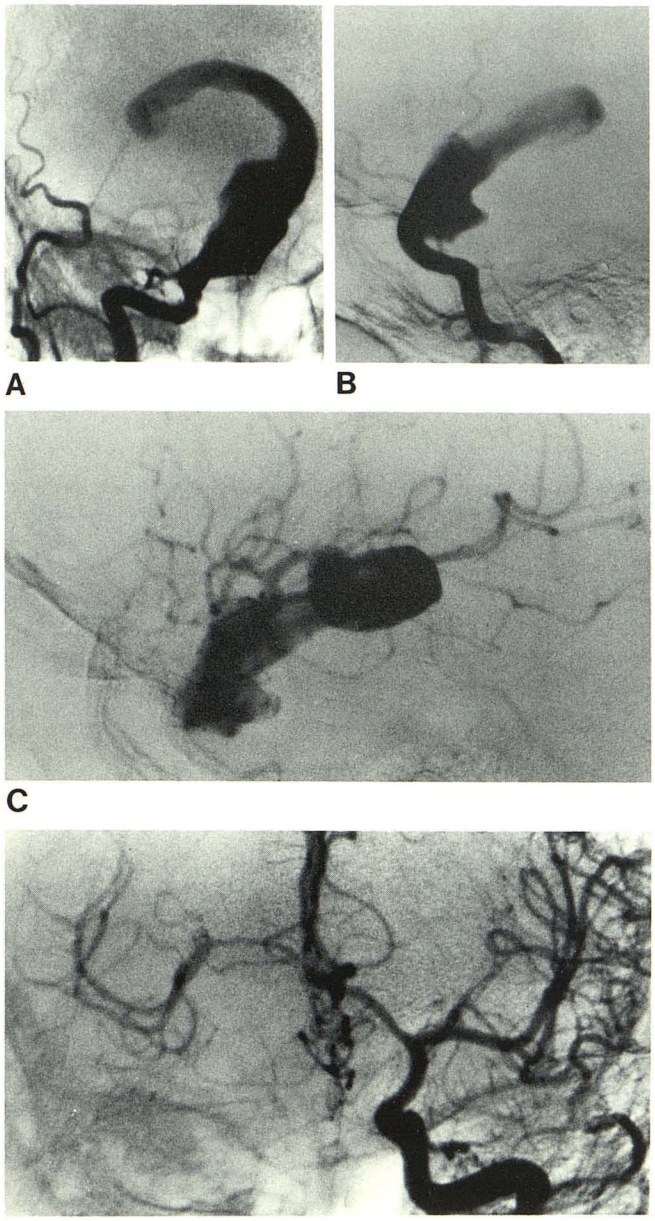

Fig. 2.—Case 2. **A,** Anteroposterior view. Right giant carotid artery bifurcation aneurysm partially thrombosed. **B,** Lateral view. **C,** Lateral view at later phase. Middle cerebral artery branches. **D,** After superficial temporal–middle cerebral artery occlusion of right carotid siphon with detachable balloon. Contralateral carotid angiography did not opacify aneurysm. Balloon invisible on subtracted film.

carotid artery (figs. 2A–2C). The aneurysm was partially thrombosed and probably compressed the right optic nerve. A cerebral blood flow study showed that the patient could tolerate permanent occlusion of the carotid artery. Nevertheless, a right superficial temporal artery–middle cerebral artery bypass was performed. The horizontal part of the right carotid siphon was permanently occluded 5 days later with a detachable balloon filled with Conray-60 (fig. 2D). The clinical course subsequently was uneventful and vision returned.

Case 3

A 46-year-old woman complained of left retroorbital pain, nausea, and vomiting. She had no oculomotor nerve palsy and her vision was normal. Angiography showed a saccular left cavernous carotid aneurysm 2 cm in diameter (fig. 3A) and a fusiform right cavernous carotid aneurysm. Both anterior and posterior communicating arteries were well opacified.

The left carotid artery aneurysm was occluded with a silicone–tantalum powder-filled balloon and the carotid flow was preserved (fig. 3B). Transient right arm weakness and some dysphasia developed immediately after detachment of the balloon. This probably occurred because of embolization from the balloon, the orifice of which was not completely occluded after detachment. Some particles of tantalum powder and silicone were seen in the parietal lobe on CT. No permanent neurologic deficit ensued. Angiography 2 months later showed no filling of the aneurysm. However, a severe stenosis of the siphon had developed (figs. 3C and 3D). The orbital pain had disappeared.

Case 4

A 42-year-old woman had a total left ophthalmoplegia and intractable retroorbital pain. Left carotid angiography (figs. 4A and 4B) showed an unclippable cavernous carotid artery aneurysm. The anterior and posterior communicating arteries were patent and the cerebral blood flow study suggested that the carotid artery could be occluded.

One balloon inflated with Conray-60 was detached in the aneurysm (figs. 4C and 4D). The neck of the balloon was occluded and the carotid artery was patent. The pain disappeared. A short episode of right arm weakness and dysphasia occurred some hours after treatment. Follow-up angiography 1 and 2 months later showed refilling of the aneurysm after progressive deflation of the balloon (figs. 4E–4H) and a second treatment was necessary to occlude the horizontal part of the carotid siphon with a second detachable balloon. The patient tolerated the occlusion of the carotid artery and her third and sixth nerve palsies disappeared.

Case 5

A 30-year-old man complained of left retroorbital pain and diplopia for a few weeks. Vision was normal in his left eye but a sixth nerve palsy was present. Left carotid angiography showed a giant cavernous carotid artery aneurysm (fig. 5A). Twelve balloons were detached in the aneurysm during two different sessions 3 days apart (fig. 5B). The first 11 balloons were inflated with Conray-60. The twelfth balloon was inflated with 2 ml of silicone. The neck of the aneurysm was almost totally occluded, and the carotid blood flow was preserved.

After this second treatment, a series of complications occurred. Initially the patient developed a total ophthalmoplegia and intractable retroorbital pain. After some weeks, he became febrile and drowsy. He was blind in his left eye. A CT scan showed two brain abscesses (fig. 5C).

Since the anterior and posterior communicating arteries were patent, a third treatment with detachment of a balloon in the horizontal part of the carotid artery, occluding the neck of the aneurysm, was carried out. The next day, the two abscesses were drained. They were contiguous with the aneurysm. The aneurysm sac was opened and all the balloons removed. Except for blindness, he showed excellent recovery. In retrospect, simple occlusion of the siphon may have avoided all these complications.

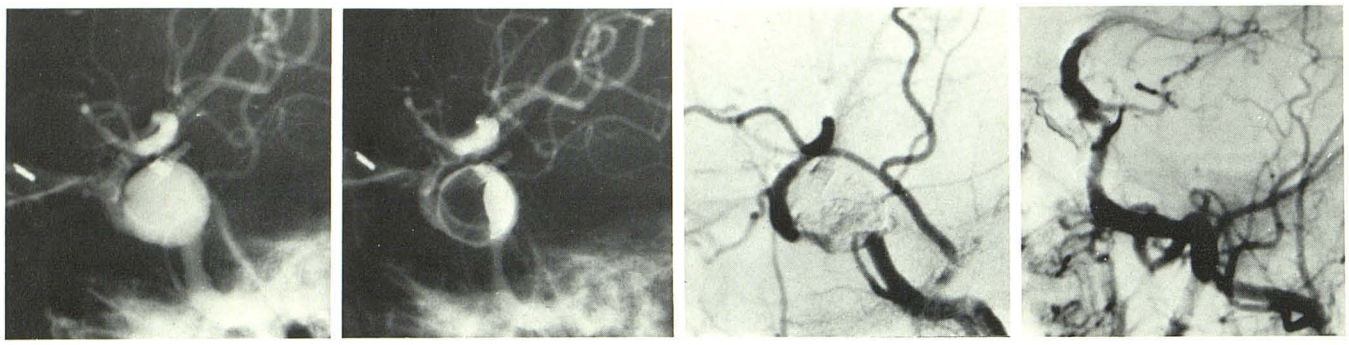

A B C D

Fig. 3.—Case 3. **A,** Left carotid artery aneurysm. **B,** Occlusion of aneurysm with detachable balloon partially filled with silicone and tantalum powder posteriorly and ring of Conray-60 anteriorly. Lateral (**C**) and anteroposterior (**D**) views 2 months later. Aneurysm does not fill, but there is stenosis of siphon with slow arterial flow.

Case 6

A 35-year-old woman had transient ischemic attacks involving the left cerebral hemisphere. A left internal capsule infarct was seen on CT. Angiography demonstrated a giant left ophthalmic aneurysm that appeared surgically unclippable. As the anterior and posterior communicating arteries were small, a superficial temporal–middle cerebral artery bypass was performed. The carotid siphon was then permanently occluded with a detachable balloon filled with Conray-60. The patient tolerated the occlusion without adverse sequelae.

Case 7

A 30-year-old woman had a subarachnoid hemorrhage. Angiography showed a giant right carotid artery bifurcation aneurysm. Initially the right carotid siphon was occluded with a detachable balloon filled with Conray-60. The aneurysm still filled through the anterior communicating artery, and a superficial temporal–middle cerebral artery bypass was done. Subsequently, the A1 part of the anterior cerebral artery and the right posterior communicating artery were clipped. Follow-up angiography demonstrated nonfilling of the aneurysm. Recovery was excellent.

Case 8

A 38-year-old man had subarachnoid hemorrhage from a giant internal carotid bifurcation aneurysm (figs. 6A and 6B). It was impossible to clip the neck of the aneurysm at surgery. The A1 part of the anterior cerebral artery, however, was clipped. A superficial temporal–middle cerebral artery bypass was carried out. Subsequently, the right carotid siphon was occluded with a detachable balloon filled with Conray-60. The follow-up angiogram (fig. 6C) showed that the aneurysm did not fill, and there was good opacification of the middle cerebral artery through the bypass, and of the internal carotid artery above the balloon through the ophthalmic artery. The clinical result was excellent.

Case 9

A 12-year-old girl had a subarachnoid hemorrhage from rupture of a basilar artery aneurysm (fig. 7A). Surgical attempts to clip the neck of the aneurysm failed. The right vertebral artery was ligated above the origin of the right posterior inferior cerebellar artery (fig. 7B). A tourniquet placed on the basilar artery just below the neck of the aneurysm failed to occlude the basilar artery. Subsequently, the left vertebral artery was occluded with a detachable balloon at the C1 level (fig. 7C). The aneurysm still slightly filled and the right posterior inferior cerebellar artery continued to fill normally through the right vertebral artery. The tip of the basilar artery filled from above (fig. 7D). The clinical result was excellent. At the time of this report, it was still too early for follow-up angiography.

Discussion

Giant intracranial aneurysms can be clipped with good clinical results [1, 4]. However, some cannot be treated in this manner, and in such cases it seems reasonable to try intraluminal aneurysm occlusion. Both surgical thrombosis [8, 9] and balloon placement within the aneurysm have been tried [2, 3]. If successful, the aneurysm will thrombose and the artery will be preserved. However, balloon occlusion carries some risk. Since the neck of these aneurysms is generally wide, the balloon has a high chance of bulging into the artery, resulting in stenosis or occlusion of the parent artery. Rupture of such aneurysms, with death or severe morbidity, is also a major risk.

Effective intrasaccular thrombosis of the aneurysm depends on the material used to inflate the balloon. If a water-soluble iodine material is used, the balloon will progressively deflate and the aneurysm may refill, as was seen in case 4. When the internal carotid artery is occluded with an iodine-filled balloon, the balloon will also deflate. However, by the time this occurs the artery will usually already be thrombosed.

A polymerizing substance such as silicone can be used, but not through a single-lumen catheter. Since the dead space in the catheter cannot be emptied of contrast material, it is reintroduced into the balloon when the silicone is injected. The balloon will then be filled only partially with silicone. This disadvantage can be avoided if a double-lumen catheter is used. As silicone displaces the contrast agent from the balloon, it is possible to aspirate it through the second lumen, leaving the balloon exclusively inflated

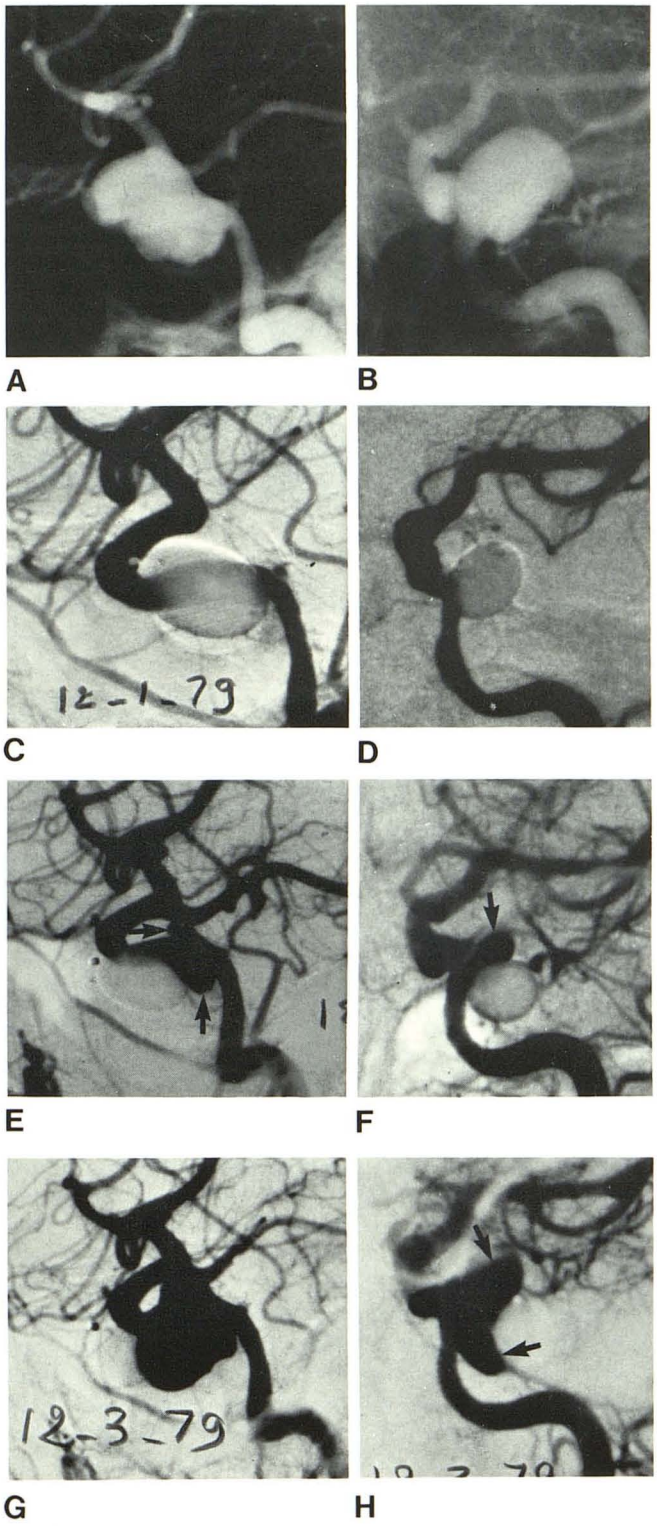

Fig. 4.—Case 4. **A** and **B,** Giant cavernous carotid artery aneurysm. **C** and **D,** Aneurysm totally occluded with detachable balloon inflated with Conray-60. **E** and **F,** 1 month later. Aneurysm partly filled because of partial deflation of balloon. **G** and **H,** 1 more month later. Further filling of aneurysm and further deflation of balloon. Second treatment finally necessary to permanently occlude carotid siphon with detachable balloon.

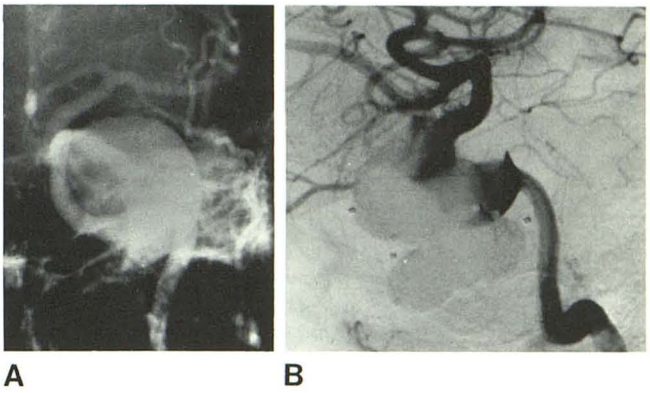

Fig. 5.—Case 5. **A,** Giant cavernous carotid artery aneurysm. **B,** Left carotid angiography after detachment of 12 balloons in aneurysm.

with silicone. The balloon will maintain its size and shape permanently and the aneurysm will thrombose, but the aneurysm sac is transformed into a solid mass that may compress the surrounding neural and vascular structures (case 3).

Complications occurred in the three cases where attempts were made to occlude the aneurysm with one or several balloons. Case 3 had a transient right arm weakness with aphasia. The final result was good but there was a stenosis of the carotid siphon on the 2 month follow-up angiogram and it would not be unexpected if the carotid artery should eventually thrombose. Case 4 had a transient right arm hemiparesis and dysphasia a few hours after occlusion of the aneurysm with the balloon. The aneurysm filled again as soon as the balloon began to deflate and the carotid siphon was finally occluded with a second detachable balloon with an excellent clinical result. Case 5 was a giant cavernous sinus aneurysm 5 cm in diameter, which was occluded with 12 detachable balloons. The patient lost his vision, had a complete ophthalmoplegia, intractable retroorbital pain, and developed two brain abscesses. After permanent occlusion of the carotid siphon, the abscesses were safely drained. The patient made a good recovery.

For these reasons we consider that the safest way to treat a giant carotid aneurysm is to sacrifice the carotid artery. This is an important decision since we believe that not all cavernous sinus aneurysms should be treated with occlusion of the carotid artery. The natural history of these aneurysms is that they maintain their size for many years, and that they rarely burst to produce a carotid-cavernous fistula. They are often bilateral. Therefore, it seems reasonable to treat only those that induce oculomotor nerve palsies and intractable pain.

The occlusion of the carotid artery can be accomplished in different ways. Ligation of the internal carotid artery has often been performed in the past [1, 5, 6, 10–14]. Some surgeons prefer to use a Selverstone clamp, which allows control of the tolerance to occlusion of the carotid artery. The major advantage of balloon occlusion over Selverstone clamping is that the balloon may be placed higher with

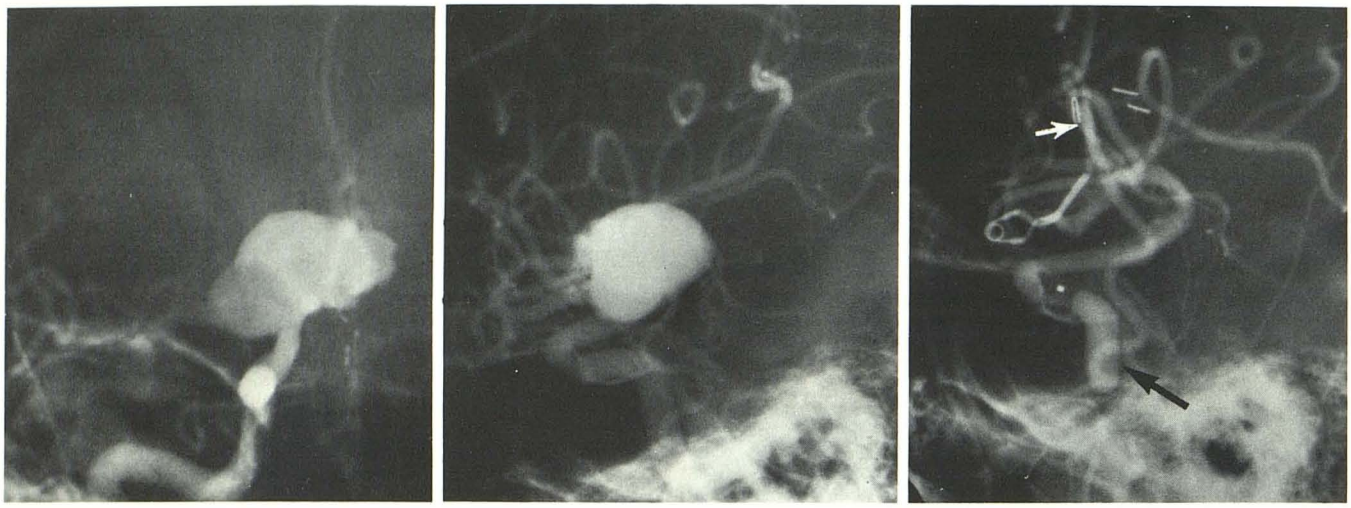

A B C

Fig. 6.—Case 8. **A** and **B,** Giant internal carotid bifurcation aneurysm, unclippable at surgery. A1 ligated at that time. **C,** Right carotid angiogram. Patent superficial temporal–middle cerebral artery bypass (*white arrow*). Siphon occluded with detached balloon (*black arrow*). Aneurysm does not fill despite opacification of internal carotid artery through ophthalmic artery.

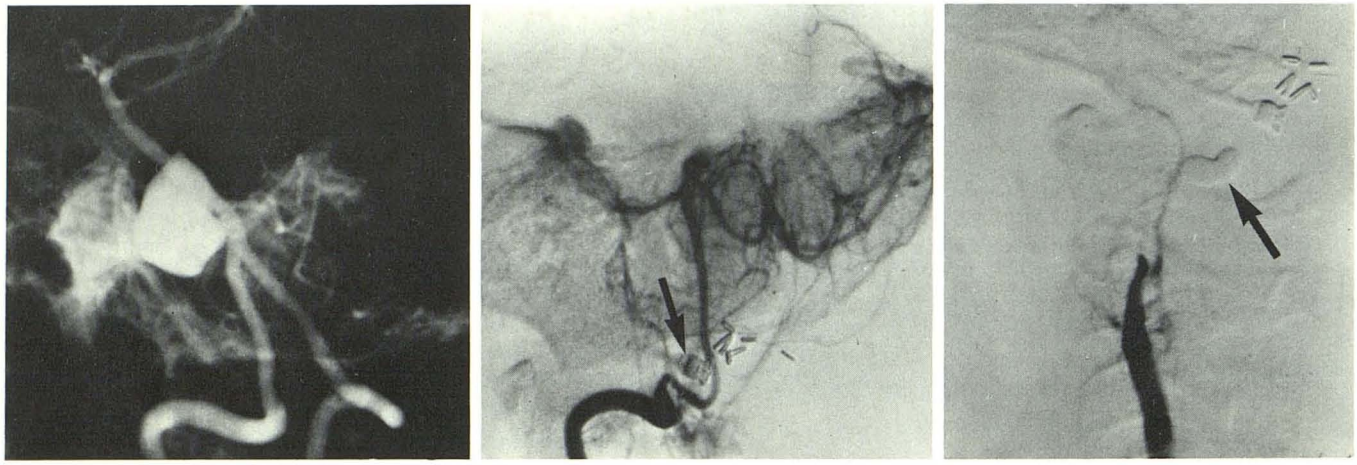

A B C

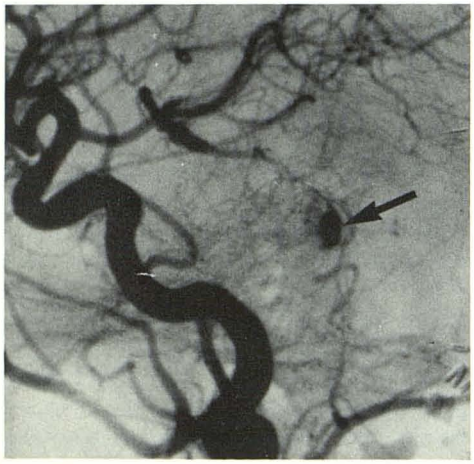

D

Fig. 7.—Case 9. **A,** Vertebral angiogram. Giant basilar artery aneurysm. **B,** Right vertebral angiogram. Right vertebral artery clipped above posterior inferior cerebellar artery (*arrow*). Aneurysm still fills partially through right posterior–anterior inferior cerebellar artery anastomsis. **C,** Left vertebral angiogram. Occlusion of left vertebral artery with detachable balloon (*arrow*) below origin of left posterior inferior cerebellar artery. **D,** Right common carotid angiogram. Aneurysm fills partially through right carotid, posterior communicating, and upper basilar arteries.

reduction of the dead space, in which thrombosis and subsequent embolization can occur. We believe that thromboembolism rather than flow-dependent ischemia is the most common cause of complications with proximal ligation of the carotid artery.

In our experience with 16 permanent balloon occlusions of the carotid siphon, clinical tolerance was always excellent when prior angiography showed that collateral supply via the anterior and/or posterior communicating arteries opacified the middle cerebral artery during balloon occlusion of the ipsilateral carotid artery in the neck. The ^{133}Xe cerebral blood flow study corroborated these findings in the three patients in whom it was performed. The balloon technique has the additional safety feature that it can always be deflated if the patient does not tolerate occlusion of the artery.

In four of our eight cases of carotid aneurysms, a superficial temporal–middle cerebral artery bypass was carried out before or after the balloon occlusion. In all four, occlusion of the carotid siphon was tolerated and the bypass remained open. The bypass was performed not only because the occlusion of the carotid artery would not otherwise have been tolerated (two cases), but also because it was necessary to clip the A1 part of the anterior cerebral artery, obstructing cross-flow through the anterior communicating artery (two cases). When a bypass is performed, occlusion of the internal carotid artery is done as soon as possible after the bypass. There is good evidence to show that one of the major determinants of high volume flow through a bypass is demand. That is, a significant pressure drop across the anastomosis ensures a high volume flow. However, the patient must have recovered from the immediate effects of surgery. Immediate postoperative occlusion is probably unwise as the brain may not autoregulate normally and thus be less tolerant of occlusion. If the bypass is well tolerated by 24–48 hr, occlusion of the internal carotid artery with the balloon is carried out.

Since this report was prepared soon after the patients were treated, follow-up had not been very long. However, when studied after carotid artery occlusion, the eight carotid aneurysms did not fill; the basilar aneurysm still partially filled. Three cases had follow-up angiograms that showed nonopacification of the aneurysm 7 days, 2 months, and 4 months after treatment. The clinical result was excellent or good in all cases. Pain was always the first symptom to clear. Transient neurologic deficits totally disappeared. The oculomotor nerve palsies improved in all cases. One patient had total blindness on the side of his cavernous carotid artery aneurysm after treatment. This was the only permanent neurologic deficit.

To summarize our impressions in this group of eight giant surgically unclippable aneurysms of the carotid artery and one giant unclippable basilar artery aneurysm, occlusion of the parent artery appeared to be the safest way to produce thrombosis of the aneurysm. If the patient does not tolerate the occlusion, a superficial temporal–middle cerebral artery bypass may be done first. The occlusion of the artery can be produced easily by detaching a balloon at the aneurysm orifice without entering the aneurysm. Although occlusion of the aneurysm itself with the balloon is possible, thrombosis may not be complete and other complications such as transient arm weakness and oculomotor nerve palsies may occur. In such cases it is necessary to occlude the parent artery with a second detachable balloon.

REFERENCES

1. Drake CG. Giant intracranial aneurysms: experience with surgical treatment in 174 patients. *Clin Neurosurg* **1979**;26:12–95
2. Serbinenko FA. Balloon catheterization and occlusion of major cerebral vessels. *J Neurosurg* **1974**;41:125–145
3. Debrun G. Detachable balloon and calibrated leak balloon technique in the treatment of cerebral vascular lesions. *J Neurosurg* **1978**;49:635–649
4. Pia HW. Classification of aneurysms of the internal carotid system. *Acta Neurochir* (Wien) **1978**;40:5–31
5. Miller JD, Jawad K, Jennett B. Safety of carotid ligation and its role in the management of intracranial aneurysms. *J Neurol Neurosurg Psychiatry* **1977**;40:64–72
6. Ferguson GG, Farrar JK, Drake CG, Varkey GP. CBF measurement as a guide to the safety of internal carotid occlusion in the treatment of carotid aneurysms (abstr). *Can J Neurol Sci* **1979**;6:390
7. Hopkins LN, Grand W. Extracranial-intracranial arterial bypass in the treatment of aneurysms of the carotid and middle cerebral arteries. *Neurosurgery* **1979**;5:21–31
8. Hosobuchi Y. Electrothrombosis of carotid cavernous fistula. *J Neurosurg* **1974**;41:125–145
9. Mullan S. Experience with surgical thrombosis of intracranial berry aneurysms and carotid cavernous fistulas. *J Neurosurg* **1974**;41:657–670
10. Gelber BR, Sundt TM. Treatment of intracavernous and giant carotid aneurysms by combined internal carotid ligation and extra to intracavernous bypass. *J Neurosurg* **1980**;52:1–10
11. Giannotta SL, McGillicuddy JE, Kindt GW. Gradual carotid artery occlusion in the treatment of inaccessible internal carotid artery aneurysm. *Neurosurgery* **1979**;5:417–421
12. Oldershaw JB, Voris HC. Internal carotid artery ligation. A follow-up study. *J Neurol* **1966**;16:937–938
13. Winn HR, Richardson AE, Jane JA. Late morbidity and mortality of common carotid ligation for posterior communicating aneurysms (a comparison to conservative treatment). *J Neurosurg* **1977**;47:727–736
14. Roski RA, Spetzler RF, Nulsen FE. Late ischemic complications of carotid ligation in the treatment of intracranial aneurysms. Presented at the annual meeting of the American Association of Neurological Surgeons, New York, April **1980**