

Are your **MRI contrast agents** cost-effective?

Learn more about generic **Gadolinium-Based Contrast Agents**.



FRESENIUS
KABI

caring for life

AJNR

Intramedullary penetrance of metrizamide in the dog spinal cord.

P J Dubois, B P Drayer, M Sage, D Osborne and E R Heinz

AJNR Am J Neuroradiol 1981, 2 (4) 313-317

<http://www.ajnr.org/content/2/4/313>

This information is current as
of May 29, 2024.

Intramedullary Penetrance of Metrizamide in the Dog Spinal Cord

Philip J. Dubois¹
 Burton P. Drayer
 Michael Sage
 Dennis Osborne
 E. Ralph Heinz

Metrizamide computed tomography (CT) myelography is clinically useful in the detection of syringohydromyelia. The mechanism by which intrathecally injected metrizamide migrates into the intramedullary cavity is unknown, although reflux into the central canal of the cord via the obex has been postulated. Since intrathecally injected metrizamide has been shown to penetrate normal brain, similar penetrance of the spinal cord might be expected. Five anesthetized mongrel dogs were examined with sequential CT scanning of the cervical spine for 24 hr after intrathecal introduction of metrizamide. The attenuation values of the opacified subarachnoid space and the spinal cord at the level of the atlantoaxial joint were recorded. A significant and reproducible increase with time in attenuation values within the cervical spinal cord accompanied by a progressive decrease in attenuation values of the subarachnoid space was observed. The proposed mechanism of cord enhancement, the implication for cord imaging, and the analysis of patients with syringohydromyelia are discussed.

Recent reports have indicated a useful role for metrizamide computed tomography (CT) myelography in the diagnosis of syringohydromyelia [1]. In this condition intrathecal metrizamide migrates into the central cavity of the spinal cord, possibly via the obex, and CT scans obtained at 6 hr define a marked increase in x-ray attenuation values of the cord itself. In such patients, it is sometimes difficult to distinguish the opacified cavity from the surrounding spinal cord. Since penetration of metrizamide into the normal extracellular brain space has been demonstrated by CT and autoradiography [2, 3] it is likely that similar penetration into the normal spinal cord occurs after intrathecal metrizamide introduction. Quantitation of such spinal cord penetration is considered desirable to assist in the analysis of syringohydromyelia, and as a possible adjunctive method for routinely imaging the normal or pathologic spinal cord. Demonstration of such intramedullary penetrance would also account for occasional cases of muscle cramps and myoclonic jerks in the lower extremities after metrizamide myelography in man. In order to investigate experimentally whether metrizamide penetrates the normal spinal cord, sequential CT scans of the high cervical cord were obtained in five dogs after the intrathecal introduction of this water-soluble contrast agent.

Received August 19, 1980; accepted after revision February, 7, 1981.

Presented at the annual meeting of the American Society of Neuroradiology, Los Angeles, March 1980.

¹All authors: Department of Radiology, Division of Neuroradiology, P.O. Box 3808, Duke University Medical Center, Durham, NC 27710. Address reprint requests to P. J. Dubois.

AJNR 2:313-317, July/August 1981
 0195-6108/81/0204-0313 \$00.00
 © American Roentgen Ray Society

Materials and Methods

Five anesthetized mongrel dogs weighing 15–20 kg were immobilized and examined with serial CT scanning at the level of the atlantoaxial joint over a period of 7–8 hr. After this, all the animals were awakened and resumed normal activity and feeding routines. A 24 hr CT scan under anesthesia was also obtained at as nearly the same level as possible in four of the animals.

The CT scans were obtained with the Searle Photrax 4000 unit. The stability of the derived CT numbers was verified at the beginning of each study using a water-bath phantom. The scans were obtained using 130 kVp, 30 mA, 20 sec scan time, and 10 mm

collimation. At each hour, five sequential CT scans were obtained at identical levels to minimize error due to respiratory motion. The animals were carefully positioned and immobilized so that the same anatomic level could be reproduced from hour to hour, although such precision could not be achieved in the 24 hr studies.

Attenuation values were measured by manual positioning of a 21 pixel rectangular region of interest within the spinal cord (fig. 1). The final position of the cursor was selected by the lowest possible standard deviation of the mean CT number obtained within the visible image of the spinal cord. A similar manually positioned cursor was used to record the attenuation value in Hounsfield units (H) within the opacified subarachnoid space.

Following sedation with acepromazine maleate, cuffed endotracheal tube was inserted. A surgical level of anesthesia was maintained using intravenous Nembutals. Either 3 or 5 ml of metrizamide

at a concentration of 170 mg l/ml was introduced into the cervical subarachnoid space in one of two ways: by lumbar puncture and elevation of the hind limbs in three animals and by a cisternal puncture and mild head elevation in two. After CT confirmation of the correct placement of metrizamide in the cervical canal, the animal was immobilized in the horizontal position. Because of the difficulty in precisely reproducing the anatomic level of interest following movement of the animal for lumbar or cisternal puncture, initial attempts to obtain "scout" CT scans prior to metrizamide introduction were abandoned and the first attenuation value measured within the spinal cord was obtained immediately after metrizamide introduction and positioning of the animal within the scanner.

Results

In all five animals there was an unequivocal progressive elevation of attenuation values within the cervical spinal cord, with a simultaneous progressive decrease in attenuation values of the surrounding, initially opacified, subarachnoid space (table 1, figs. 2-4). The attenuation values of the spinal cord immediately following metrizamide introduction were 28.8-45.4 H (mean 35.6 H) and the maximum increases in cord attenuation values were 55.3-88.0 H (mean, 72.3 H). Three dogs receiving 5 ml of metrizamide



Fig. 1.—10 mm thick CT section at level of dens. Cervical cord is surrounded by high attenuation value metrizamide. Rectangular cursor (7 × 3 pixels) was positioned within cord image so that lowest standard deviation (here, 3.7 H) of mean (41.3 H) attenuation value was obtained.

TABLE 1: Increase in Spinal Cord Attenuation Values in Five Animals

Dog No.	Maximum Increase in Cord Attenuation (H) (% Baseline)	Time to Maximum (hr)	Later Scans Obtained (hr)	Metrizamide Dose (ml)	Route
4274	25.1 (55)	6	7, 8, 24	3	Lumbar
4578	59.2 (226)	8+	24	5	Cisternal
3344	24.0 (47)	5	6, 24	3	Lumbar
4637	22.5 (68)	8+	None	5	Cisternal
3119	50.3 (173)	7+	24	5	Lumbar

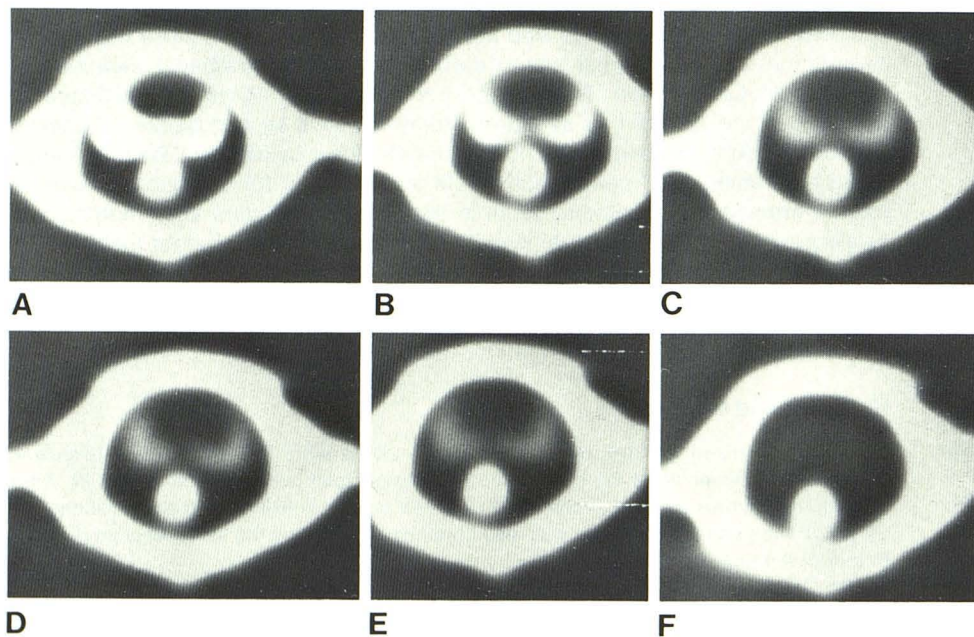


Fig. 2.—Dog 4578. A-F, Sequential 10 mm CT sections at C1-C2 level obtained at 1, 3, 5, 7, 8, and 24 hr, respectively, after metrizamide introduction. Each image is one of five scans obtained at identical level to minimize error in CT numbers. Progressive decrease in attenuation value of subarachnoid space is appreciated.

had maximum increases in cord attenuation values of 226%, 68%, and 173% of the baseline. Two dogs receiving 3 ml of metrizamide by lumbar injection had maximum increases of 55% and 47% of baseline cord attenuation values.

Maximum cord attenuation values were recorded at 5, 6, 7, 8, and 8 hr (tables 1 and 2). In two animals (nos. 3344 and 4274), this maximum value occurred at 5 and 6 hr and was followed by a decrease shown in consecutive hourly scans. The actual peak may have occurred later than 7 or 8 hr in three dogs (nos. 3119, 4578, and 4637) since no further hourly scans were obtained to record a decrease prior to the 24 hr examination. In one animal (no. 4637) no 24 hr scan was obtained because of equipment failure. In three of the four animals in whom a 24 hr scan was obtained (nos. 4578, 3344, and 3119), the attenuation coefficient at 24 hr was lower than the peak level of the preceding day, but was higher than the baseline value obtained immediately after metrizamide introduction. (For technical reasons it was not possible to keep the animals immobilized on the CT pallet for 24 hr continuously. Therefore, considerable potential for error exists in the 24 hr measurements.)

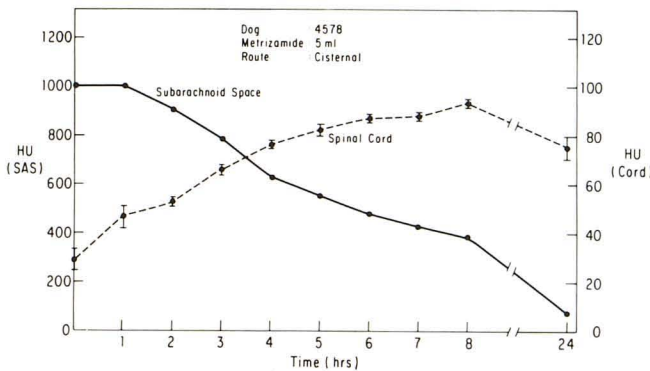
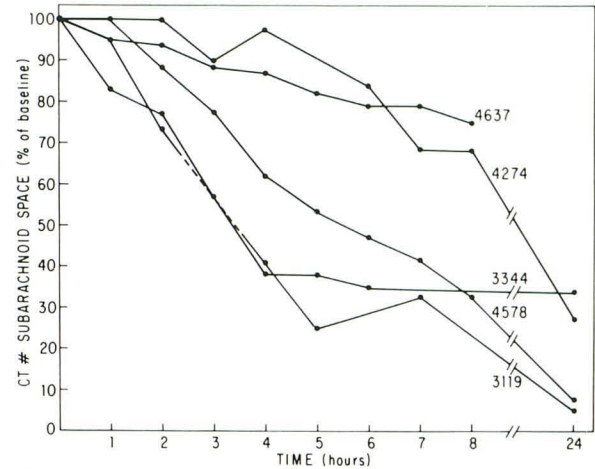


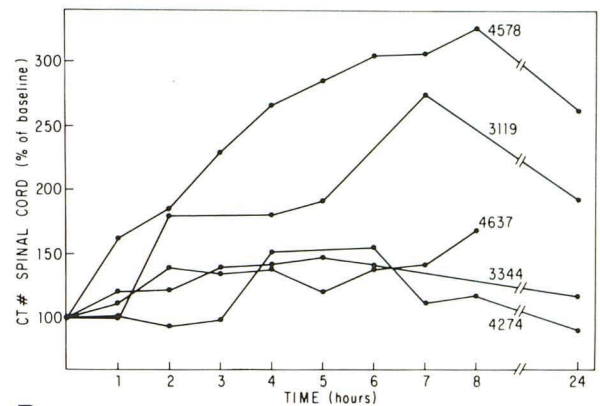
Fig. 3.—Attenuation values (mean and standard deviation of five readings each hour) were obtained from a 21 pixel rectangular region of interest in cord and subarachnoid space using the "most homogeneous sample" method shown in figure 1. A plot of these values against time shows an increase in attenuation of the cord, maximal in this case at 8 hr.

Discussion

The cerebrospinal fluid marker metrizamide progressively increases the density of the cervical spinal cord of dogs



A



B

Fig. 4.—Change in CT numbers of subarachnoid space (A) and spinal cord (B) with time expressed as a percentage of values at time zero. (Animal identification numbers are annotated.)

TABLE 2: CT Numbers for 21 Pixel Regions of Interest within Spinal Cord and Subarachnoid Space

Hour	Mean of Five Readings (H) (SD)									
	Dog 4274		Dog 4578		Dog 3344		Dog 4637		Dog 3119	
	SAS	Cord	SAS	Cord	SAS	Cord	SAS	Cord	SAS	Cord
0	120.8 (9.5)	45.4 (2.9)	1023.0* (0)	28.8 (9.0)	223.8 (23.2)	45.1 (4.4)	291.8 (2.4)	33.0 (7.2)	863.6 (39.5)	30.8 (2.4)
1	121.3 (4.9)	46.2 (3.2)	1023.0* (0)	46.6 (8.0)	186.4 (20.1)	54.6 (6.7)	277.0 (4.5)	36.5 (6.2)	820.2 (27.6)	31.0 (5.1)
2	119.0 (9.0)	42.0 (3.3)	899.0 (13.8)	53.22 (1.7)	171.7 (7.5)	54.8 (3.8)	274.8 (5.4)	46.2 (3.7)	634.0 (31.1)	55.0 (1.4)
3	109.0 (3.2)	44.5 (2.5)	788.6 (12.8)	66.0 (4.5)	128.6 (6.0)	62.5 (4.6)	257.0 (3.4)	44.5 (4.2)
4	118.8 (7.6)	68.9 (15.0)	629.6 (8.8)	76.6 (1.6)	108.3 (8.0)	63.4 (3.9)	253.0 (5.5)	45.8 (3.9)	356.0 (25.1)	55.0 (1.4)
5	549.0 (9.7)	82.2 (5.2)	107.9 (8.1)	66.2 (5.2)	237.7 (2.4)	39.5 (5.8)	334.0 (24.8)	58.8 (2.6)
6	101.8 (5.2)	70.5 (4.3)	480.6 (8.8)	87.6 (1.1)	89.2 (6.5)	63.8 (4.8)	230.7 (19.0)	45.8 (10.3)
7	81.8 (4.6)	50.6 (2.7)	430.0 (6.9)	88.0 (3.4)	218.2 (12.7)	46.5 (1.3)	281.6 (2.6)	84.0 (6.7)
8	80.6 (5.1)	52.9 (2.6)	390.1 (4.9)	93.9 (3.4)	220.3 (13.3)	55.3 (2.5)
24	32.3 (3.4)	40.7 (2.8)	79.8 (6.7)	75.2 (10.3)	77.1 (10.6)	52.8 (3.1)	41.8 (4.4)	59.0 (4.6)

Note.—SAS = subarachnoid space; cord = spinal cord.
 * 1023 H is the highest CT number recordable with the scanner mode used.

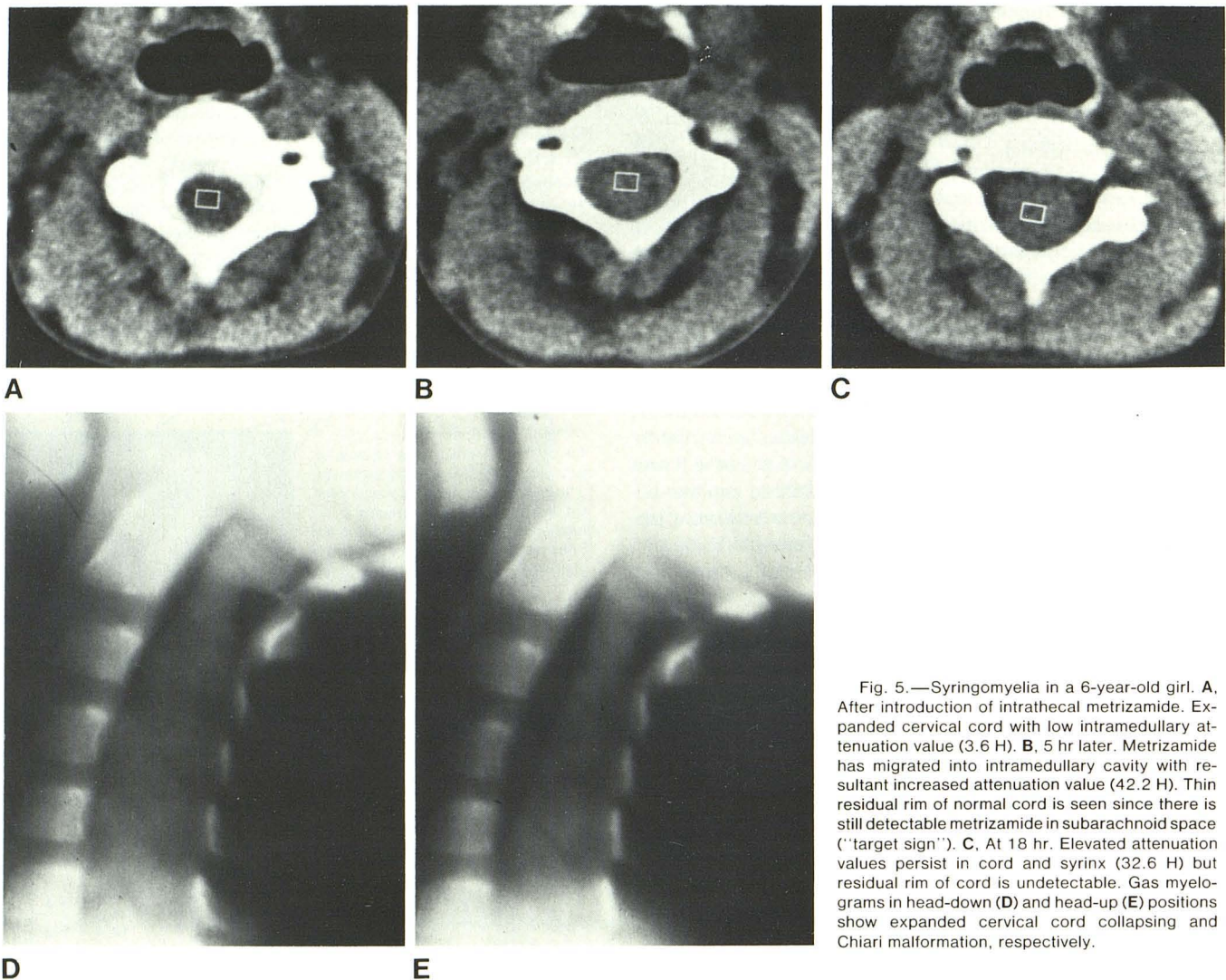


Fig. 5.—Syringomyelia in a 6-year-old girl. **A**, After introduction of intrathecal metrizamide. Expanded cervical cord with low intramedullary attenuation value (3.6 H). **B**, 5 hr later. Metrizamide has migrated into intramedullary cavity with resultant increased attenuation value (42.2 H). Thin residual rim of normal cord is seen since there is still detectable metrizamide in subarachnoid space ("target sign"). **C**, At 18 hr. Elevated attenuation values persist in cord and syrinx (32.6 H) but residual rim of cord is undetectable. Gas myelograms in head-down (**D**) and head-up (**E**) positions show expanded cervical cord collapsing and Chiari malformation, respectively.

over several hours as determined *in vivo* using CT scanning. This nonionic, water-soluble contrast agent (molecular weight 789) therefore crosses the cerebrospinal fluid-spinal cord barrier to enter the parenchyma of the cord as it does in the brain [2, 3]. The maximum cord enhancement is delayed in onset occurring at a time when the iodine concentration in both the subarachnoid space (by Hounsfield units) and the circulating blood (by fluorescence excitation analysis [Sage MR, Dubois PJ, Drayer BP, et al., unpublished data]) have decreased considerably. The magnitude of the increase in cord attenuation values is not accurately quantitated by this study because of the small number of animals studied and since different doses and routines of administration were used.

Our findings suggest that metrizamide used in conjunction with serial CT imaging may provide an *in vivo* technique for analyzing the extracellular space of the spinal cord and brain. The bulk of current evidence suggests that cerebrospinal fluid solutes entering the cerebral parenchyma do so

by simple diffusion to enter the extracellular space [4, 5]. After crossing the pia-glial and ependymal membranes, lipid insoluble metabolically inert molecules (e.g., inulin, horseradish peroxidase, sulfate, and mannitol) are distributed in the interstitial fluid of the neuropil and for practical purposes do not cross the blood-brain barrier. Water, potassium, and certain metabolically active molecules (e.g., cycloleucine, 2-deoxyglucose) are distributed intra- as well as extracellularly [6]. While the fate of intracerebral metrizamide is unknown, it seems reasonable to assume a predominantly extracellular distribution [7, 8]. Small molecular weight "extracellular" markers are known to traverse the blood-brain barrier [9] presumably by active transport, but the extremely slow rate of such a process suggests its effect would be negligible in the removal of metrizamide from the interstitial space of the brain.

While studies of molecular diffusion from cerebrospinal fluid to the parenchyma of the neuraxis have been largely confined to the brain, similar mechanisms likely pertain in

the spinal cord. Lee and Olszewski [10] noted that intrathecally injected radioactive bovine albumin entered the periphery of the spinal cord in the cat and the dog; fluorescein-labeled serum proteins [11] and a copper-albumin complex [12] similarly penetrated the periphery of animal spinal cords at varying times after injection into the subarachnoid space. Thus, parenchymal penetration of intrathecally injected metrizamide into the spinal cord, as in the brain, is not an unexpected phenomenon.

If intramedullary metrizamide penetration occurs in man, the time frame over which this phenomenon occurs may be similar to that demonstrated in dogs. Such penetration would help explain the occasional cases of lower limb myoclonus encountered hours after lumbar metrizamide myelography [13]. In addition, such penetration would explain occasional difficulty detecting the residual rim of normal spinal cord surrounding the opacified central cavity in delayed metrizamide CT myelography in syringohydromyelia (fig. 5C).

Isherwood et al. [14] observed a 20 H increase of attenuation values in the human spinal cord in the first hour after intrathecal introduction of metrizamide with a progressive diminution of cord attenuation values over the subsequent 5 hr. They noted a later maximum peak in cord attenuation values at 3–6 hr in some subjects. Although these latter results were not statistically significant, they clearly conform to the experimental results in the present work in dogs. Further studies to determine the time frame over which peak cord penetration occurs in humans using a late generation CT scanner with increased spatial resolution are currently in progress.

Initially it was proposed that late migration of intrathecally injected metrizamide into syringohydromyelic cavities as shown by CT indicated a communication between the intramedullary cavity and the fourth ventricle [15]. The present study suggests the possibility that such delayed intracavitary opacification may result from a slow diffusion of metrizamide through the attenuated rim of residual normal cord parenchyma, and thus may occur independent of ventricular communication. If this mechanism indeed applies, it appears that intraventricular introduction of metrizamide [16] with subsequent search for rapid opacification of the intramedullary cavity by CT may provide a potentially more reliable, albeit more invasive, technique to determine whether there is communication between a demonstrated syringomyelic cavity and the fourth ventricle.

REFERENCES

- Vignaud J, Aubin ML. Kystes syringomyeliques: mise en évidence par le transit à la metrizamide avec tomodensitométrie. *Presse Med* **1979**;33:2691–2692
- Golman K. Distribution and retention of ¹²⁵I-labeled metrizamide after intravenous and suboccipital injection of rabbit, rat and cat. *Acta Radiol [Suppl]* **1973**;335:300–311
- Drayer BP, Rosenbaum AE. Metrizamide brain penetration. *Acta Radiol [Suppl]* **1977**;355:280–293
- Dunker RO, Harris AB, Jenkins DP. Kinetics of horseradish peroxidase migration through cerebral cortex. *Brain Res* **1976**;118:199–217
- Cserr HF. Relationship between cerebrospinal fluid and interstitial fluid of brain. *Fed Proc* **1974**;33:2075–2078
- Oldendorf WH, Davson H. Brain extracellular space and the sink action of cerebrospinal fluid. *Arch Neurol* **1967**;17:196–205
- Levin I, Sisson WB. The penetration of radiolabeled substances into rabbit brain from subarachnoid space. *Brain Res* **1972**;41:145–153
- Winkler SS, Sackett JF. Explanation of metrizamide brain penetration: a review. *J Comput Assist Tomogr* **1980**;4:191–193
- Reed DJ, Woodbury DM. Kinetics of movement of iodide, sucrose, inulin and radio-iodinated serum albumin in the central nervous system and cerebrospinal fluid of the rat. *J Physiol (Lond)* **1963**;169:816–850
- Lee JC, Olszewski J. Penetration of radioactive bovine albumin from cerebrospinal fluid into brain tissue. *Neurology (NY)* **1960**;10:814
- Klatzo I, Miquel J, Ferris PJ, Prokub JD, Smith DE. Observations on the passage of the fluorescein labeled serum proteins (FLSP) from the cerebrospinal fluid. *J Neuropathol Exp Neurol* **1964**;23:18–35
- Vogel FS, Evans JW. Morphologic alterations produced by copper in neural tissues with consideration of the role of the metal in the pathogenesis of Wilson's disease. *J Exp Med* **1961**;113:997–1004
- Hilal SK, Dauth GW, Burger LC, Gilman S. Effect of isotonic contrast agents on spinal reflexes in the cat. *Radiology* **1977**;122:149–155
- Isherwood I, Fawcitt RA, Forbes W, Nettle JRL, Pullan BR. Computer tomography of the spinal canal using metrizamide. *Acta Radiol [Suppl]* **1977**;355:299–305
- Vignaud J, Aubin ML, Jarden C. CT in 25 cases of syringomyelia. Presented at the annual meeting of the American Society of Neuroradiology, Toronto, Canada
- Crolla D, Hens L, Wilms G, et al. Metrizamide enhanced CT in hydrosyringomyelia. *Neuroradiology* **1980**;19:39–41