

Are your MRI contrast agents cost-effective?

Learn more about generic Gadolinium-Based Contrast Agents.



**FRESENIUS
KABI**

caring for life

AJNR

**Noninvasive Testing for Carotid Artery Stenosis:
II. Clinical Application of Accuracy Assessments**

Daniel H. O'Leary, Melvin E. Clouse, Alfred V. Persson and Sally Ann Edwards

AJNR Am J Neuroradiol 1981, 2 (6) 565-567

<http://www.ajnr.org/content/2/6/565>

This information is current as
of April 28, 2024.

Noninvasive Testing for Carotid Artery Stenosis: II. Clinical Application of Accuracy Assessments

Daniel H. O'Leary¹
Melvin E. Clouse¹
Alfred V. Persson²
Sally Ann Edwards¹

Determination of the specificity, sensitivity, and accuracy of diagnostic tests usually identifies the value of the tests in isolation, but the clinical significance of the findings is less clear. In this study the accuracies of direct continuous wave color-coded Doppler imaging (DDI), periorbital directional Doppler ultrasonography (PDDU), and oculoplethysmography-carotid phonangiography (OPG-CPA) were calculated for each examination alone and in combination with others for 176 patients who had been studied by all three noninvasive methods for suspected extracranial carotid arterial disease. When evaluated alone, DDI yielded the highest accuracy, 94%. In 89% of the population, DDI agreed with at least one of the other two tests. When this occurred, the majority finding was correct in 98%. When DDI disagreed with the other two tests (11% of cases), it was correct in only 50%. These findings suggest a clinical approach which would minimize testing while achieving a high accuracy for most patients and identifying those patients whose carotid status could not be discerned with these studies.

In reviewing the results of a 2 year prospective study assessing the reliability of three noninvasive tests in detecting significant carotid artery stenosis, it seemed that the accuracy of any of these tests varied markedly depending on its agreement or disagreement with the other noninvasive tests. The concept of a battery of noninvasive tests to improve diagnoses, proposed by Ackerman and others [1-3], seemed applicable to our situation and worthy of investigation.

With that in mind, we reviewed the data from our own study and found that 176 of the 216 patients had been examined by all three methods. These 176 patients provided the basis for an analysis of agreement and disagreement among the studies and determination of the implications for clinical care.

Materials and Methods

The study group was 176 patients who were scheduled for cerebral angiography for suspected cerebral vascular disease between June 1979 and December 1980. Indications for angiographic study included transient ischemic attack (108 patients), complete stroke (12), asymptomatic bruit (38), and syncope, dizziness, or other nonfocal symptom (18). All patients had been examined with the White-Curry continuous-wave color-coded directional Doppler Echoflow scanner (DDI), periorbital directional Doppler ultrasonography (PDDU), and oculoplethysmography-carotid phonoangiography (OPG-CPA) before angiography.

Doppler scanning of the carotid bifurcation detects alterations in the peak velocity of moving erythrocytes, thus directly sampling carotid artery hemodynamics. Oculoplethysmography and periorbital directional Doppler ultrasonography indirectly monitor carotid artery hemodynamics by detecting alterations in blood flow and pressure in the ophthalmic artery and its branches. The instrumentation, examination techniques, and criteria for interpretation of findings have been described [4]. Angiography served as the standard against which the correctness of each noninvasive test was measured. The percentage of stenosis was determined by measuring the narrowest diameter seen on any angiographic view and dividing this by the diameter of the normal vessel distal to the stenosis. Narrowing of the residual lumen by 65% or greater on either view was considered significant.

This article appears in the November/December 1981 issue of *AJNR* and the January 1982 issue of *AJR*.

Received January 26, 1981; accepted after revision May 26, 1981.

¹ Department of Radiology, Harvard Medical School, New England Deaconess Hospital, 185 Pilgrim Rd., Boston, MA 02214. Address reprint requests to D. H. O'Leary.

² Department of General Surgery, Lahey Clinic Foundation, Burlington, MA 01803.

AJNR 2:565-567, November/December 1981
0195-6108/81/0206-0565 \$00.00
© American Roentgen Ray Society

TABLE 1: Efficacy of DDI, PDDU, and OPG-CPA

	DDI	PDDU	OPG-CPA
True positive	90	58	77
True negative	76	81	71
False positive	8	3	13
False negative	2	34	15
Accuracy	94% (166/176)	80% (148/176)	84% (148/176)
Sensitivity	98% (90/92)	63% (58/92)	84% (77/92)
Specificity	90% (76/84)	96% (81/84)	85% (71/84)

Note.—Data on 176 patients, 92 with significant carotid stenosis, 84 without.

TABLE 2: Accuracy of a Consensus for DDI, PDDU, and OPG-CPA

When Agreement Occurred Between	With Agreement, Result was Correct This % (Fraction) of the Time	Such Agreement Occurred This % (Fraction) of the Time
DDI, PDDU, and OPG-CPA	99 (116/117)	66 (117/176)
DDI and PDDU	99 (130/131)	74 (131/176)
DDI and OPG-CPA	98 (142/145)	82 (145/176)
DDI and either PDDU or OPG-CPA	98 (154/157)	89 (157/176)
PDDU and OPG-CPA which disagree with DDI	50 (9/19)	9 (19/176)

The sensitivity of each noninvasive test was determined by dividing the number of true-positive noninvasive studies by the total number of abnormal angiographic studies, the true-positive rate. Specificity was calculated by dividing the number of true-normal noninvasive studies by the number of angiograms that were interpreted as not showing significant disease, the true-negative rate. The accuracy of each noninvasive method was calculated by adding the true-positive and true-negative noninvasive results and then dividing by the total number of patients in the study [5, 6].

The accuracy of a consensus agreement between tests (e.g., DDI and PDDU) is the percentage correctly diagnosed when the tests agree as specified. That is, the accuracy of a consensus is the number of true-positive and true-negative tests where the agreement occurred divided by the number of times the agreement occurred. The accuracy of a consensus gives no information about what happens when agreement does not occur.

Results

Of the 176 patients studied noninvasively, 92 patients were found to have significant stenosis at angiography and 84 patients did not. The individual test results are reported in Table 1. The sensitivity of DDI for determining stenosis was 98%, its specificity was 90%, and the accuracy of the test proved to be 94%. OPG-CPA had a sensitivity of 84% and a specificity of 85%. The sensitivity of PDDU was 63%, lowest of the three tests, but its specificity of 96% was highest.

The various test results were then analyzed for patterns of agreement and disagreement. The accuracy of consensus agreement is reported in table 2. All three noninvasive tests, whether normal or abnormal, agreed on the diagnosis of 117 individuals, for whom subsequent angiography proved the noninvasive tests to be correct in all but one

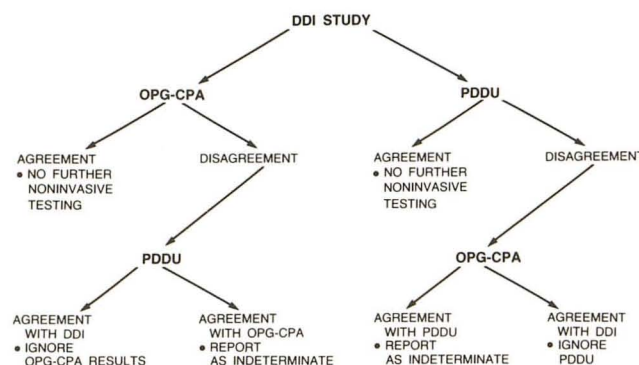


Fig. 1.—Decision tree for noninvasive examination in suspected carotid artery stenosis. After initial DDI study, patient undergoes OPG-CPA or PDDU, whichever is more convenient or readily available. If interpretation of second study agrees with DDI study, no further noninvasive testing is necessary. If second study does not agree with DDI results, third study should be performed. If third study agrees with DDI, that diagnosis should be used and findings from second study ignored. If neither of indirect studies agrees with DDI study, noninvasive findings should be reported as indeterminate.

instance for an accuracy of consensus of 99%. DDI and PDDU were found to be in agreement in 131 cases. These paired composite tests were also proven correct by angiography in all but one case. DDI and OPG-CPA agreed in 145 instances, but were incorrect three times for a slightly diminished accuracy of 98%. DDI agreed with one of the other two tests in 157 patients. The combination of agreement between DDI and either PDDU or OPG-CPA was wrong three times for an accuracy of 98%.

Discussion

There is growing agreement among clinicians that individuals experiencing a classic transient ischemic attack should undergo angiography followed by endarterectomy if a suitable lesion is demonstrated [7–10]. For such patients and their doctors, the noninvasive laboratory has little relevance in the diagnostic scheme. For other individuals, who have spells somewhat suggestive of a cerebral ischemic episode, a strong family history of stroke accompanied by multiple risk factors, asymptomatic bruits, or scheduled major surgery and a greater than normal operative risk, the results of the noninvasive tests may well be critical. Such patients make up the majority of those evaluated routinely in almost every noninvasive facility.

In these instances the referring physician attempts to use the test results to decide whether to proceed to invasive angiography. Since these patients are not clearly symptomatic, it is desirable to avoid the risks of angiography unless there is a high probability of uncovering significant disease. While the definition of significant disease will vary among institutions, there is normally more concern with uncovering a major flow-reducing lesion, rather than an ulcerative plaque that is clinically silent.

Ideally, noninvasive screening tests should have a high sensitivity and specificity. Direct carotid Doppler sampling of blood velocities in the region of the carotid bifurcation gave superior results to OPG-CPA and PDDU testing, but the highest overall diagnostic accuracy in our series was obtained by combining results obtained by both direct and indirect sampling of carotid artery hemodynamics. In the 117 instances when all three tests were in agreement, these were proven correct by angiography 116 times for an overall combined diagnostic accuracy of 99%. For the remaining 59 patients, one-third of the total study, there was disagreement among the three tests, leaving them in a suspect category.

Agreement between DDI and one of the other tests occurred in about 90% of the studies. In our series when such agreement occurred between DDI and PDDU, an accuracy rate of 99% was achieved. When agreement between DDI and OPG-CPA occurred, they were correct 98% of the time.

After analyzing these results, we attempted to devise a clinical approach that would offer the best chance of an accurate diagnosis, would minimize the number of noninvasive tests required to obtain that diagnosis, and would identify those patients whose diagnosis could not be determined with any confidence by these noninvasive means. The decision tree in figure 1 reveals the clinical approach supported by our combined accuracy data. In this schema all patients are first examined by DDI and then undergo a second study, either OPG-CPA or PDDU. If there is agreement, no further noninvasive tests are needed and the accuracy will be 98%–99%, depending on whether PDDU or OPG-CPA testing is first obtained. If there is disagreement, a third noninvasive test should be performed. If this third test agrees with DDI, that diagnosis would be 98%–99% accurate and the second test result would be disregarded.

With this schema, about 10% of patients would have a DDI diagnosis inconsistent with both the other tests. Re-

gardless of whether continuous wave Doppler imaging of the carotid bifurcation was normal or abnormal, we found it was correct in 50% of such studies and the two other tests were correct in the remaining 50%. Thus we report such a pattern of disagreement as indeterminate.

This clinical approach to the noninvasive diagnosis of extracranial carotid artery disease minimizes the number of tests required for each individual. Application of direct Doppler imaging with these other noninvasive tests is an important advance because of the great accuracy with which one may identify patients for whom angiography would contribute no useful information.

ACKNOWLEDGMENT

We thank Paula Goldman for assistance in manuscript preparation.

REFERENCES

1. Ackerman RH. A perspective on noninvasive diagnosis of carotid disease. *Neurology* 1979;29:615–622
2. O'Donnell TF Jr, Pauker SG, Callow AD, Kelly JJ, McBride KJ, Korwin S. The relative value of carotid noninvasive testing as determined by received operator characteristic curves. *Surgery* 1980;87:9–19
3. Kornhuber HH, Wider B. The prevention of strokes: which are the best methods to detect carotid stenosis? *Arch Psychiatr* 1980;228:11–20
4. O'Leary DH, Persson AV, Clouse ME. Noninvasive testing for carotid artery stenosis. I. Prospective analysis of three modalities. *AJNR* 1981;2:437–442
5. McNeil BJ, Keeler E, Adelstein SJ. Primer on certain elements of medical decision making. *N Engl J Med* 1975;293:211–215
6. Block S, Baltaxe HA, Shoumaker RD. Reliability of Doppler scanning of the carotid bifurcation: angiographic correlation. *Radiology* 1979;132:687–691
7. McDowell FH, Millikan CH, Goldstein M. Treatment of impending stroke. *Stroke* 1980;11:1–3
8. Sandok BA, Furlan AJ, Whisnant JP, Sundt TM. Guidelines for the management of transient ischemic attacks. *Mayo Clin Proc* 1978;53:665–674
9. Mohr JP. Transient ischemic attacks and the prevention of strokes. *N Engl J Med* 1978;299:93–95
10. Byer JA, Easton JD. Therapy of ischemic cerebrovascular disease. *Ann Intern Med* 1980;93:742–756