

Generic Contrast Agents

Our portfolio is growing to serve you better. Now you have a *choice*.



[VIEW CATALOG](#)

AJNR

Risk of Clot Formation in Femoral Arterial Sheaths Maintained Overnight for Neuroangiographic Procedures

Robert A. Koenigsberg, Michael Wysoki, Jeffrey Weiss, Scott H. Faro and Fong Y. Tsai

This information is current as of April 19, 2025.

AJNR Am J Neuroradiol 1999, 20 (2) 297-299
<http://www.ajnr.org/content/20/2/297>

Risk of Clot Formation in Femoral Arterial Sheaths Maintained Overnight for Neuroangiographic Procedures

Robert A. Koenigsberg, Michael Wysoki, Jeffrey Weiss, Scott H. Faro, and Fong Y. Tsai

BACKGROUND AND PURPOSE: The purpose of this study was to evaluate the presence of blood clots in femoral arterial sheaths maintained after cerebral angiography and the effect of heparinized saline on clot formation.

METHODS: Twenty-three sheaths were evaluated in 18 patients. Sheaths were maintained for 14 to 80 hours (average, 33 hours; median, 24 hours). After the sheaths were removed, they were vigorously flushed with 60 mL of normal saline and the number and size of clots found in each sheath were recorded. Additionally, patients' age, catheter size, presence of heparin, amount of time the sheath was kept in the artery, and patients' coagulation status were recorded.

RESULTS: Clots were found in 17 (74%) of the 23 sheaths. Ten catheters had continuous heparin drip, of which seven (70%) sustained clots. Of the 13 sheaths without heparin, 10 sustained clots (77%). The difference was not statistically significant. The average number of clots was 2.2, and the maximal length of clots ranged from 0.5 to 105 mm. No thromboembolic complications associated with sheath placement were encountered in our patient population.

CONCLUSION: Blood clots are present in the vast majority of intraarterial sheaths maintained after cerebral angiography. These clots constitute a risk of thromboembolic complications in the event of repeat angiography. Sheath exchange should be considered before obtaining repeat cerebral angiograms.

The use of femoral sheaths for arterial vascular access is a common interventional neuroradiologic practice. Sheaths are used for both short-term access in routine diagnostic angiography as well as for prolonged neurointerventional procedures. Typically, diagnostic angiographic procedures use smaller access sheaths of 4F to 6F, whereas interventional neuroradiologic procedures frequently require larger guidecatheters, necessitating the placement of larger femoral sheaths. The latter are usually in the 6F to 10F range, depending on the needs of a specific case.

Commonly, a heparinized saline flush is used in an effort to prevent in vivo clot formation within the sheath lumen. However, the use of heparin in arterial sheath flush lines is controversial, because it may aggravate acute intracranial hemorrhage. With the introduction of percutaneous treatment techniques for cerebrovascular disorders, particularly the use of detachable coils in the treatment of ruptured aneurysms, the short-term use of heparin has become common practice in reducing throm-

boembolic catheter-related complications. However, the relatively prolonged use of heparin in flush lines remains controversial, regardless of whether the patient requires percutaneous or surgical intervention.

Indications for long-term arterial sheath placement include the need for follow-up angiograms after clipping or coiling of intracranial aneurysms, the anticipated use of intraoperative angiography in patients with previous arterial sheath placement, and the need for numerous repeat follow-up angiograms for intracranial vasospasm treatments, arterial blood pressure monitoring, or simply until systemic anticoagulation is reversed, allowing for safe sheath removal. This study was undertaken to evaluate the effect of heparinized flush versus saline flush on clot formation within arterial sheaths maintained overnight.

Methods

Patients were included in our study if a femoral arterial sheath was maintained for more than 12 hours. Sheaths included in this study were placed and removed by our neuroradiology service. All sheaths were manufactured by Terumo (Tokyo, Japan) under the brand name Pinnacle. Patients were randomized into two groups, one receiving heparinized saline (2000 U/L) and the other receiving normal saline. All sheaths were maintained with a transducer-monitored flushing system,

Received June 22, 1998; accepted after revision October 16.

From the Department of Radiology, MCP/Hahnemann University, 3300 Henry Ave, Philadelphia, PA 19129.

Address reprint requests to Robert A. Koenigsberg, DO.

Patient characteristics

Patient	Sex/Age (y)	Sheath Size (F)	Hours in Artery	Heparin Drip	PT/PTT	Number of Clots	Maximal Clot Size (mm)
1	M/41	7	21	+	12.1/32.3	3	1
2	M/56	8	40	-	14.4/26	6	7
3	F/47	9	14	+	15/88	1	17
4	F/47	5	14	+	15/88	None	...
5	F/53	7	72	-	12.7/21.9	1	15
6	F/62	6	72	-	12.4/23.2	2	12
7	F/54	7	42	-	12.6/27.2	7	10
8	F/49	7	24	+	12/27	None	...
9	F/53	8	21	+	13.5/25.4	2	20
10	F/43	5	14	-	13.4/26.2	None	...
11	F/48	5	27	-	12.1/22.1	2	0.5
12	F/43	6	24	+	13/26.9	3	2
13	F/56	4	25	-	13.2/32	1	2
14	F/15	4	24	-	14.5/25.9	2	2
15	F/65	6	18	-	...	1	3
16	M/63	4	41	-	15/200	None	...
17	M/63	6	24	-	14.7/26.4	1	10
18	F/42	5	16	-	11.9/27	2	3
19	F/63	5	80	+	/54	1	12
20	F/63	6	80	+	/54	1	105
21	F/62	7	19	-	...	None	...
22	M/21	6	32	+	13.6/23.9	None	...
23	F/53	6	22	+	13.1/24.7	1	4

Note.—PT indicates prothrombin time; PTT, partial thromboplastin time; +, with heparin; -, without heparin.

with a flush rate of 3 mL per hour, according to our intensive care unit protocol. Each time a study sheath was removed from a patient, the sheath was immediately evaluated at bedside for indwelling clots by means of vigorous flushing with 60 mL of normal saline solution. The sheath was then examined for the presence of any residual clots. The number and size of clots were recorded. Additionally, the patients' age and sex, the catheter size, the duration of sheath placement, and the patients' coagulation status during the time the sheath was in place were recorded (see Table).

Results

Twenty-three sheaths were evaluated in 18 patients (see Table). Sheaths were maintained for 14 to 80 hours (average, 33 hours; median, 24 hours). Clots were found in 17 (74%) of the 23 sheaths. Ten catheters had continuous heparin drip, of which seven (70%) sustained clots. Of the 13 sheaths without heparin, 10 sustained clots (77%). The difference was not statistically significant ($P = 1.0$, Fisher exact test). The average number of clots was 2.2, and the maximal length of clots ranged from 0.5 to 105 mm. No thromboembolic complications associated with sheath placement were encountered in our patient population. One of the larger clots obtained in our study group is shown in Figure 1.

Discussion

Known complications of femoral arterial puncture include groin hematomas, pseudoaneurysm formation, local femoral or iliac arterial dissection caused by local arterial wall trauma, infection, re-

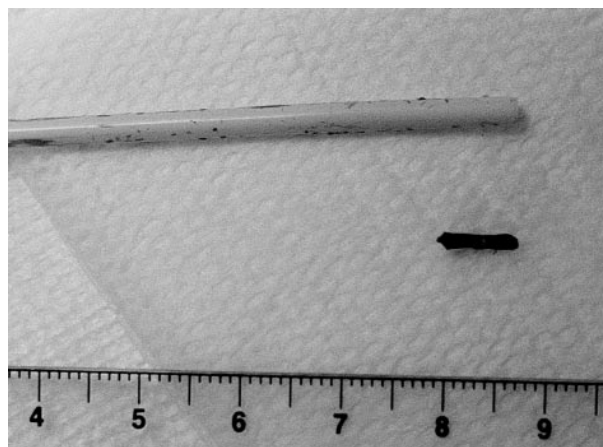


FIG 1. Photograph of a typical clot obtained from an arterial sheath.

troperitoneal hemorrhage, arteriovenous fistula, and emboli, with an overall complication rate of 0.5%. The risk of thromboembolic complications related to prolonged maintenance of femoral arterial sheaths is low (1-5).

Findings reported in the current nursing literature support the use of saline flushing alone in the maintenance of peripheral venous access or arterial pressure monitoring catheters without added heparin because of its proved efficacy in maintaining the patency of both peripheral intravenous locks and radial arterial pressure monitoring lines (6-9). Interventional neuroradiology practices, however, are unique, in that typically larger caliber sheaths are

used and may be repeatedly traversed with inner catheters for follow-up angiograms. Clots were found in 77% of the nonheparinized sheaths and in 70% of the heparinized sheaths. We found the difference to be not statistically significant, possibly because of the small number of patients in our series. However, even if heparin does reduce the risk of clot formation in the sheath, it definitely does not prevent clots from forming.

Before this study, we did not exchange an indwelling sheath before every repeat neuroangiographic study. It has not been our experience to see distal embolic complications when reusing sheaths that had not been exchanged. However, we theorize that there is potential, though small, for small emboli to be pushed out of the sheath into the arterial tree by an inner catheter. We suspect that these emboli are frequently silent and most likely lyse without sequelae. However, larger clots, as large as the ones seen in our study, may be a problematic cause for significant thromboembolic complications.

Conclusion

This study confirms that small emboli do form within indwelling femoral arterial sheaths maintained "overnight." This occurs regardless of the addition of heparin to the flush solution. In this study, we did not evaluate the effect of flush rates on clot formation. We can only speculate that, when possible, a faster rate of flushing can add an additional level of effectiveness in the prevention

of clots within sheaths. Therefore, we advise caution when reusing long-term arterial sheaths for follow-up angiographic procedures. In the event of repeat cerebral angiographic procedures through an existing femoral arterial sheath, sheath exchange should be strongly considered.

References

1. Fruwirth J, Pascher O, Hauser H, Amann W. **Local vascular complications after iatrogenic femoral artery puncture.** *Wien Klin Wochenschr* 1996;108:196-200
2. Katzenschlager R, Ugurluoglu A, Ahmadi A. **Incidence of pseudoaneurysm after diagnostic and therapeutic angiography.** *Radiology* 1995;195:463-466
3. Altin RS, Flicker S, Naidech HJ. **Pseudoaneurysm and arteriovenous fistula after femoral artery catheterization: association with low femoral punctures.** *AJR Am J Roentgenol* 1989;152:629-631
4. Lodge JP, Hall R. **Retroperitoneal haemorrhage: a dangerous complication of common femoral arterial puncture.** *Eur J Vasc Surg* 1993;7:355-357
5. Spies JB, Berlin L. **Complications of femoral artery puncture.** *AJR Am J Roentgenol* 1998;170:9-11
6. Kulkarni M, Elsner C, Ouellet D, Zeldin R. **Heparinized saline versus normal saline in maintaining patency of the radial artery catheter.** *Can J Surg* 1994;37:37-42
7. Gyr P, Burroughs T, Smith K, Mahl C, Pontious S, Swerczek L. **Double blind comparison of heparin and saline flush solutions in maintenance of peripheral infusion devices.** *Pediatr Nurs* 1995;21:383-389
8. Meyer BA, Little CJ, Thorp JA, Cohen GR, Yeast JD. **Heparin versus normal saline as a peripheral line flush in maintenance of intermittent intravenous lines in obstetric patients.** *Obstet Gynecol* 1995;85:433-436
9. Kleiber C, Hanrahan K, Fagan CL, Zittergruen MA. **Heparin vs. saline for peripheral i.v. locks in children.** *Pediatr Nurs* 1993;19:405-409