

# Generic Contrast Agents

Our portfolio is growing to serve you better. Now you have a *choice*.



FRESENIUS  
KABI

[VIEW CATALOG](#)

# AJNR

## Successful Radiosurgical Treatment of Arteriovenous Malformation Accompanied by Venous Malformation

Hiroki Kurita, Tomio Sasaki, Masao Tago, Yuu Kaneko and  
Takaaki Kirino

This information is current as  
of May 9, 2025.

*AJNR Am J Neuroradiol* 1999, 20 (3) 482-485  
<http://www.ajnr.org/content/20/3/482>

## Case Report

# Successful Radiosurgical Treatment of Arteriovenous Malformation Accompanied by Venous Malformation

Hiroki Kurita, Tomio Sasaki, Masao Tago, Yuu Kaneko, and Takaaki Kirino

**Summary:** We present a patient with a rare cerebrovascular malformation consisting of a typical arteriovenous malformation (AVM) with a nidus and a venous malformation (VM) in a single lesion. The AVM component was successfully obliterated by radiosurgery, whereas the VM was completely preserved. Radiosurgery can be an effective treatment technique for treating this type of malformation because it allows targeted obliteration of the AVM yet carries a low risk of damaging the venous drainage toward and away from the VM.

Various associations of two discrete vascular malformations of the brain are known, and each combination is recognized as a distinct clinicopathologic entity (1, 2). Several authors have described venous malformation (VM) with arteriovenous shunting that can be considered an immature form of arteriovenous malformation (AVM). Nonetheless, coexistence of an AVM and a VM within a single lesion is extremely rare. We report a case of true AVM-VM coexistence that was successfully treated by gamma-knife radiosurgery. Our experience adds to the knowledge concerning the clinical features of and therapeutic strategies for this peculiar cerebrovascular malformation.

## Case Report

A 39-year-old man noticed transient dysarthria in June 1996, and underwent neuroradiologic examination at a local hospital. MR imaging showed an infarction affecting the left corona radiata, and an unruptured vascular malformation in the right temporal lobe (Fig 1A). He was treated conservatively for his ischemic event, and then was referred to us for further evaluation.

Physical and neurologic examinations were normal. Thin-slice dynamic CT revealed small nidus enhancement and a large draining vein (Fig 1B and C). Cerebral angiography showed a right temporal AVM that was fed by a branch of the middle cerebral artery. After forming a distinct nidus, the

draining vein of this AVM was connected to an abnormal vein, into which many other finer veins also drained to form a typical “caput medusae” appearance of a venous malformation. The abnormal central vein drained into the right sphenopetrosal vein. Dysmorphism of the sylvian veins was also evident (Fig 2).

The patient underwent gamma-knife radiosurgery in October 1996. The treatment strategy was to irradiate only the nidus of the AVM to prevent obstructing the regional venous outflow through the VM. Isodose planning was performed on the basis of stereotactic cerebral angiography and CT. Radiation (25 Gy) was delivered to the periphery of the nidus in a single dose using one isocenter (Fig 3).

The postradiosurgical course was uneventful. At the patient's 1-year follow-up, MR imaging revealed no parenchymal radiation injury, hemorrhage, or ischemia (Fig 4A). CT showed disappearance of nidus enhancement (Fig B and C). Cerebral angiography showed total obliteration of the AVM and preservation of the VM (Fig 5).

## Discussion

There have been several reports describing a hybrid malformation consisting of an AVM and VM as a rare subset of mixed cerebrovascular malformations (1, 3–8). The majority of the reported cases, however, are in fact a combination of a typical VM with its classic triad (regional venous dysmorphism, convergence of deep collecting veins, and a deep central draining vein) and additional arteriovenous shunting (1, 3–5, 8). Such anomalies, named “arterialized VMs” by some authors (1, 7), do not have a discrete nidus but a single or multiple arterial fistulization, and therefore are considered to be a transitional form between an AVM and a VM. A hybrid malformation consisting of a typical AVM with a nidus and a classic VM in a single lesion is extremely rare. To our knowledge, the present case is only the third instance of this type of malformation (6, 8).

It is now accepted that VMs are a congenital anatomic variant of normal venous drainage that generally follow a benign clinical course (9–12). Hemorrhagic complications are rare, and many of the hemorrhagic cases are ascribed to other coexisting VMs (1). The risk of cerebral venous infarction occurring after excision or obliteration of a VM is significant and well known (1, 6, 9, 12). Consequently, when an AVM and VM coexist, it is advisable to treat the AVM while preserving the VM, which should serve as an important channel of the venous drainage from the regional brain (1,

Received in original form May 28, 1998; accepted after revision September 8, 1998.

From the Departments of Neurosurgery (H.K., T.S., T.K.) and Radiology (M.T.), Faculty of Medicine, University of Tokyo, Tokyo, Japan.

Address reprint requests to Hiroki Kurita, M.D., Ph.D., Neurochirurgische Universitätsklinik, Albert-Ludwigs-Universität Freiburg, Breisacher Straße 64, D-79106, Freiburg, Germany.

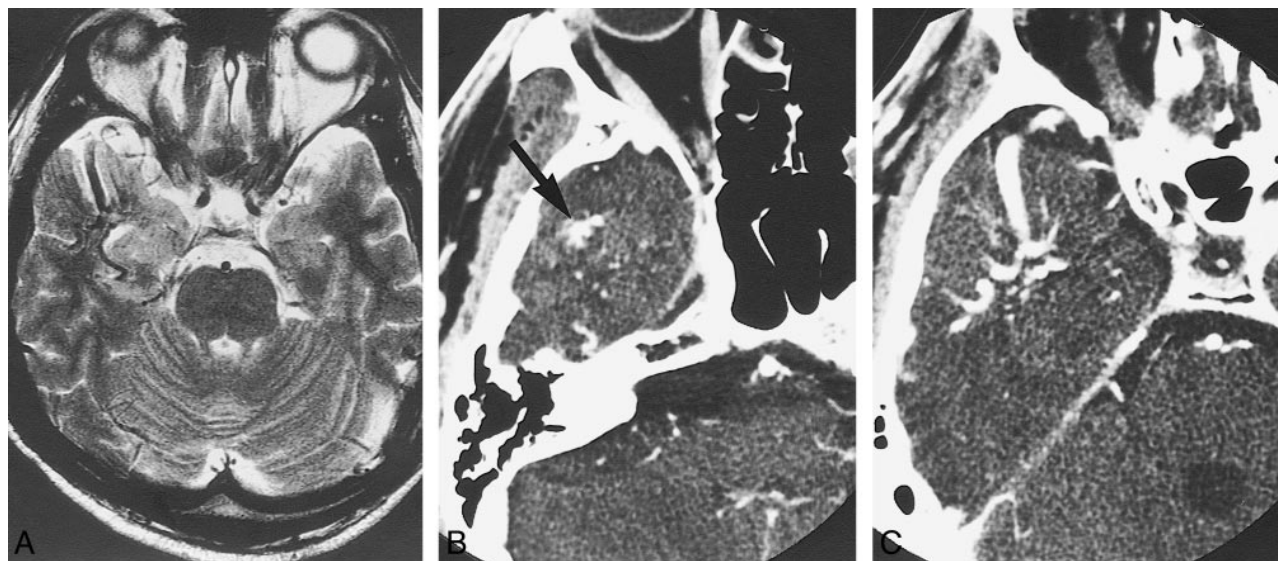


FIG 1. T2-weighted MR image (3500/96/1) shows unruptured VM of the right antero-temporal lobe (A), and thin-slice dynamic CT shows disappearance of nidus enhancement (arrow) and large draining vein (B and C).

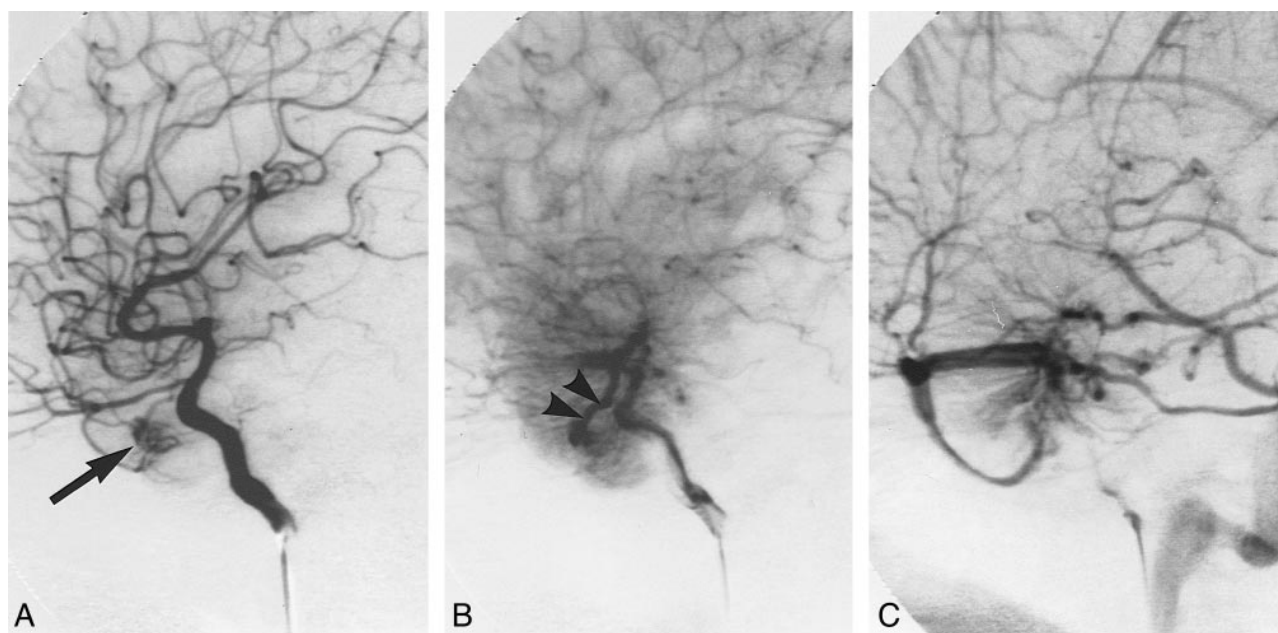


FIG 2. Serial right internal carotid angiogram reveals the AVM-VM malformation.

A, Arterial phase shows a small AVM nidus fed by the branch of the middle cerebral artery (arrow).

B, Later arterial phase shows a single AVM drainer (arrow heads) joining collecting veins along with converging small medullary veins.

C, Venous phase shows the typical "caput medusae" appearance of a VM. Note the dysmorphism of the sylvian vein.

6, 8). Limited surgical excision of the AVM component would be a valid option (1, 6) if the nidus is well separated from the major portion of the associated VM. Nonetheless, there remains a risk of unintentional damage to the venous return that could lead to a hemorrhagic or ischemic complication (6). Endovascular embolization can also be considered, but the blood-flow pattern around the

lesion can be complicated, and may hinder the total obliteration. Although there are limitations regarding lesion size, radiosurgery would be a treatment of choice when the two lesions are located too closely for a safe surgical excision or embolization of the AVM.

Several authors have discussed the use of radiosurgery for the management of AVM-VM coex-



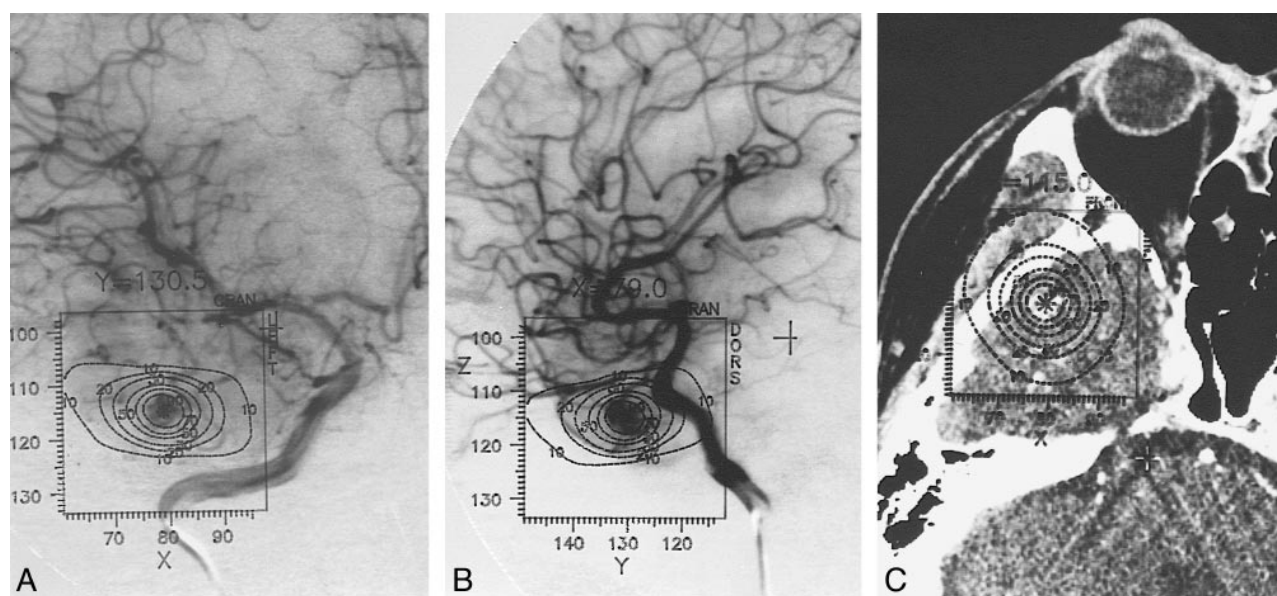


FIG 3. Anteroposterior (A) and lateral (B) views on a stereotactic right internal carotid angiogram, and stereotactic CT (C) show AVM component of lesion. At radiosurgery, 25 Gy is delivered to 50% isodose line using 1 isocenter (maximum dose 50 Gy).

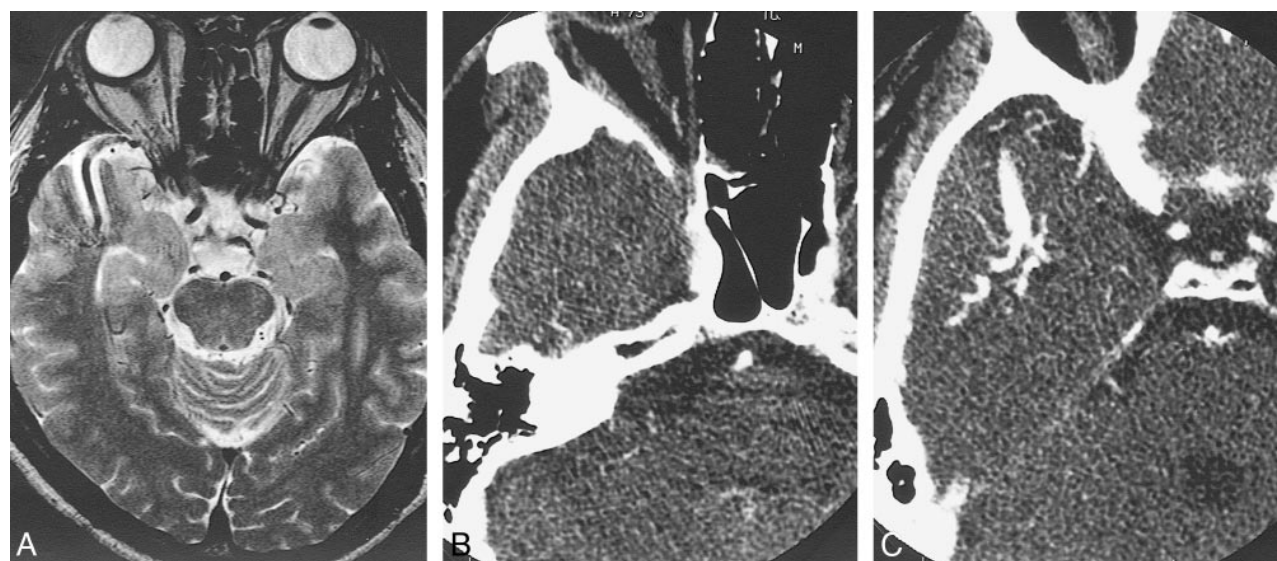


FIG 4. T2-weighted MR image obtained 1 year after radiosurgery shows no hemorrhagic or ischemic complications (A). Thin-slice dynamic CT shows absence of nidus enhancement (B and C).

istence. In their radiosurgical series of VMs, Lindquist et al (5) reported two arterialized VM cases in which the component detected in the arterial phase was irradiated, resulting in disappearance of the arteriovenous shunt. On the contrary, Mullan et al (7) mentioned similar transitional forms of AVMs and VMs that persisted despite radiosurgical treatment. These reports indicate that radiosurgery effectively occludes the arteriovenous fistula in selected patients with arterialized VM. The results remain controversial, however, because it is sometimes difficult to target small or multiple arteriovenous fistulas for obliteration by radiation.

## Conclusion

We report a case of an AVM-VM coexistence that was successfully treated by radiosurgery. Although rare, the case presented here represents another good indication for radiosurgical treatment.

## Acknowledgments

We are grateful to Bernhard Meyer of the Department of Neurosurgery, University of Bonn, and to Keisuke Ueki of the Department of Neurosurgery, University of Tokyo, for their helpful comments and suggestions.

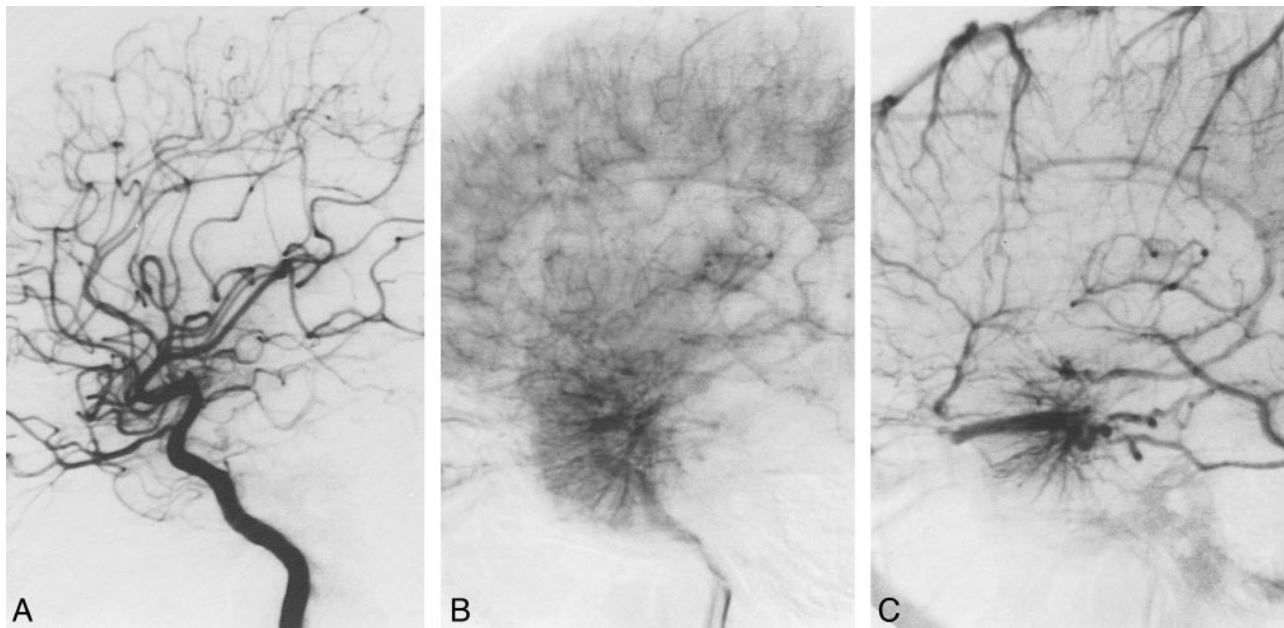


FIG 5. Serial right internal carotid angiogram obtained 1 year after radiosurgery shows total obliteration of the AVM and preservation of the VM during the arterial (A), late arterial (B), and venous (C) phases.

### References

1. Awad IA, Robinson JR Jr, Mohanty S, Estes ML. **Mixed vascular malformations of the brain: clinical and pathogenetic considerations.** *Neurosurgery* 1993;33:179-188
2. Robinson JR Jr, Award IA, Masaryk TJ, Estes ML. **Pathological heterogeneity of angiographically occult vascular malformations of the brain.** *Neurosurgery* 1993;33:547-555
3. Fierstien SB, Pribram HW, Hieshima G. **Angiography and computed tomography in the evaluation of cerebral venous malformations.** *Neuroradiol* 1979;17:137-148
4. Hirata Y, Matsukado Y, Nagahiro S, Kuratsu J. **Intracerebral venous angioma with arterial blood supply: a mixed angioma.** *Surg Neurol* 1986;25:227-232
5. Lindquist C, Guo WY, Karlsson B, Steiner L. **Radiosurgery for venous angiomas.** *J Neurosurg* 1993;78:531-536
6. Meyer B, Stangl AP, Schramm J. **Association of venous and true arteriovenous malformation: a rare entity among mixed vascular malformation of the brain.** *J Neurosurg* 1995;83:141-144
7. Mullan S, Mojtahedi S, Johnson DL, MacDonald RL. **Cerebral venous malformation-arteriovenous malformation transition forms.** *J Neurosurg* 1996;85:9-13
8. Itoyama Y, Kitano I, Fujioka S, et al. **[Mixed angioma of the brain: report of two cases.]** *No Shinkei Geka* 1994;22:465-469 (Jpn)
9. Garner TB, Curling OD, Kelly DL Jr, Laster DW. **The natural history of intracranial venous angiomas.** *J Neurosurg* 1991;75:715-755
10. Kondziolka D, Dempsey PK, Lunsford LD. **The case for conservative management of venous angiomas.** *Can J Neurol Sci* 1991;18:295-299
11. Rigamonti D, Spetzler RF, Medina M, Rigamonti K, Geckle DS, Pappas C. **Cerebral venous malformations.** *J Neurosurg* 1990;73:560-564
12. Lasjaunias P, Burrows P, Planet C. **Developmental venous anomalies (DVA): the so-called venous angioma.** *Neurosurg Rev* 1986;9:233-242