

Are your **MRI contrast agents** cost-effective?

Learn more about generic **Gadolinium-Based Contrast Agents**.



FRESENIUS  
KABI

caring for life

**AJNR**

## **Superselective Intraarterial Fibrinolysis in Central Retinal Artery Occlusion**

Riccardo Padolecchia, Michele Puglioli, Maria Cristina Ragone,  
Andrea Romani and Paolo Luigi Collavoli

*AJNR Am J Neuroradiol* 1999, 20 (4) 565-567

<http://www.ajnr.org/content/20/4/565>

This information is current as  
of April 20, 2024.

# Superselective Intraarterial Fibrinolysis in Central Retinal Artery Occlusion

Riccardo Padolecchia, Michele Puglioli, Maria Cristina Ragone, Andrea Romani, and Paolo Luigi Collavoli

**Summary:** Intraarterial fibrinolysis was performed in three patients with acute central retinal artery occlusion using recombinant tissue plasminogen activator as a fibrinolytic agent. In two cases the ophthalmic artery was selectively catheterized, and in the other a thrombolytic drug was infused into the ophthalmic artery by way of the meningeal collaterals. All patients experienced visual improvement. Fibrinolysis can produce better results than obtained from conservative treatment. A good prognosis can be achieved if the treatment starts within the first 4 to 5 hours after occlusion.

Intraarterial fibrinolysis has primarily been used in the treatment of thromboembolic occlusion of the cerebral arteries, with good results (1-4). Early applications in the ophthalmic territory produced a high rate of recanalization of the central retinal artery, with better outcomes than achieved with conservative treatment (5-7). The therapeutic goal in central retinal artery occlusion (CRAO) is to restore the retinal blood flow as soon as possible. Marked improvement has been reported when fibrinolysis was initiated within the first hours after occlusion (5-7).

We describe three patients with CRAO treated by superselective intraarterial fibrinolysis using a short-acting fibrinolytic agent, such as recombinant tissue plasminogen activator (rTPA).

## Case Reports

### Case 1

A 76-year-old man with low-grade stenosis of the right internal carotid artery (ICA) suffered loss of vision in his right eye. The fundus showed retinal edema, a cherry-red macular spot, and deficient retinal perfusion. Fluorescein angiography revealed marked delay in filling in the retinal vessels. Intraarterial fibrinolysis was carried out through a coaxial catheter system using a Tracker 18 microcatheter (Target Therapeutics, Fremont, CA) in the origin of the ophthalmic artery on the side of the CRAO (Fig 1). Treatment was initiated 6 hours

30 minutes after the onset of symptoms with a total dose of 70 mg of rTPA injected by hand at a rate of about 1 mL/min over 1.5 hours. Heparin (3000 IU) was administered intravenously at the beginning of the procedure and continued with low-molecular-weight heparin for 1 week. Improvement of flow in the retinal vessels was observed ophthalmologically during fibrinolysis; at the end of the procedure, partial recovery of vision was obtained. The result was confirmed by fluorescein angiography. No complications occurred during catheterization of the vessels, and no systemic, cerebral, or retinal bleeding was caused by the treatment. A 5-month clinical follow-up examination showed persistency of the results.

### Case 2

A 62-year-old man with arterial disease was admitted after acute onset of blindness in his left eye. The fundus showed typical macular edema with a cherry-red spot and significant reduction of the retinal circulation. Fluorescein angiography revealed a diffuse microembolism and hypoperfusion of the retinal vessels (Fig 2A). Diagnosis of the CRAO was established. Through a coaxial system, a Tracker 18 microcatheter was placed selectively in the proximal section of the left ophthalmic artery. Fibrinolytic therapy was performed within 4.5 hours after occlusion with 60 mg of rTPA over 80 minutes. Progressive improvement in vision was achieved during lysis, and increased flow was observed by ophthalmologic checking. The patient experienced complete recovery of his vision. Fluorescein angiography performed immediately after treatment revealed almost complete retinal vessel recanalization (Fig 2B). Findings at follow-up fluorescein angiography 2 days later were normal (Fig 2C). Systemic heparinization was performed during the treatment (3000 IU) followed by low-molecular-weight heparin for 1 week. No complications occurred during the procedure. The patient's visual acuity and visual field were normal at the 5-month follow-up examination.

### Case 3

A 70-year-old man was found to have a CRAO in his left eye. Diagnosis was based on a sudden loss of vision accompanied by retinal edema, a cherry-red macular spot, and deficient circulation through the retinal vessels. Fluorescein angiography was performed before thrombolysis and revealed marked delay in filling of the arteries and veins. Fibrinolytic therapy, because of the presence of ICA occlusion on the side of the CRAO, was carried out indirectly via meningeal-ophthalmic anastomosis through a Tracker 18 microcatheter placed in the middle meningeal artery (Fig 3). Thrombolysis was performed by administering 40 mg of rTPA over 45 minutes, injected within 4.5 hours after the CRAO. Marked improvement of vision, with increased retinal flow, was established through continuous ophthalmologic checking. The patient recovered completely, and fluorescein angiography confirmed total retinal vessel recanalization. Intraarterial fibrinolysis was carried out under systemic heparinization (3000 IU), extended for 1 week with low-molecular-weight heparin. The procedure was performed without any complications. A 5-month clinical follow-up examination showed no

Received May 26, 1998; accepted after revision September 28.

From the Section of Neuroradiology (R.P., M.P., P.L.C.) and the Department of Neurosciences (Section of Ophthalmology) (M.C.R., A.R.), S. Chiara Hospital, Pisa University, Italy.

Address reprint requests to Riccardo Padolecchia MD, Section of Neuroradiology, S. Chiara Hospital, Via Roma 67, 56100 Pisa, Italy.

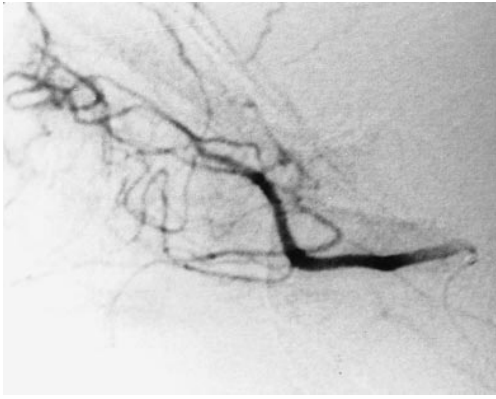


FIG 1. Case 1: Lateral subtraction angiogram of the right ICA. The microcatheter is placed at the origin of the ophthalmic artery.

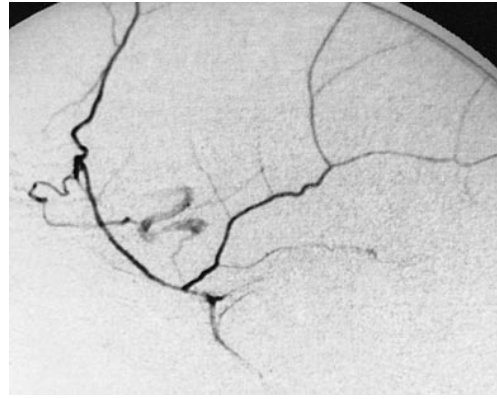


FIG 3. Case 3: Lateral subtraction angiogram of the left external carotid artery. The microcatheter is placed in the middle meningeal artery, which reaches the ophthalmic artery via an anastomosis on the side of the CRAO.

change, with complete recovery of visual acuity and visual field.

### Discussion

CRAO is among the most severe of ophthalmologic events, and it is mandatory to restore the retinal flow as soon as possible. According to previous reports, superselective fibrinolysis with a high local concentration of fibrinolytic agent can be considered the treatment of choice for CRAO (5-7). This is particularly desirable, because the prognosis for vision in untreated CRAO is poor, as Schumacher et al (6) and Weber et al (7) reported in their comparative studies. Moreover, conventional therapeutic procedures, including paracentesis, ocular massage, carboanhydrase inhibitors, and hemodilution, are not as effective as selective intra-arterial thrombolysis (8, 9). According to Duker et al (10), only two of 33 patients who underwent these different types of treatment experienced significant improvement in vision. Other investigators have reported marked immediate results during CRAO and a better outcome when the delay between the onset of symptoms and the beginning of

treatment was short (5, 6). In fact, two of our patients (cases 2 and 3), who had fibrinolysis within 4.5 hours after the onset of CRAO, recovered completely. Conversely, our third patient (case 1), in whom fibrinolysis was initiated 6.5 hours after occlusion, experienced only partial recovery. The time interval between the onset of symptoms and the start of treatment is the most important factor in determining outcome in patients with CRAO. Additionally, a better outcome is obtained when some vision remains and when no severe retinal edema is present before treatment (4, 5, 9).

All our patients were treated with a fibrinolytic agent, such as rTPA, for its short half-life and its more thrombolytic action, even when not directly introduced into the thrombus itself, as in case 3, in whom selective catheterization of the ophthalmic artery was impossible because of ICA occlusion. That, again, supports the use of thrombolysis even when the ophthalmic artery must be reached via an anastomosis (6).

As in previous reports (5, 6), the total dose was determined partly by clinical response, which was

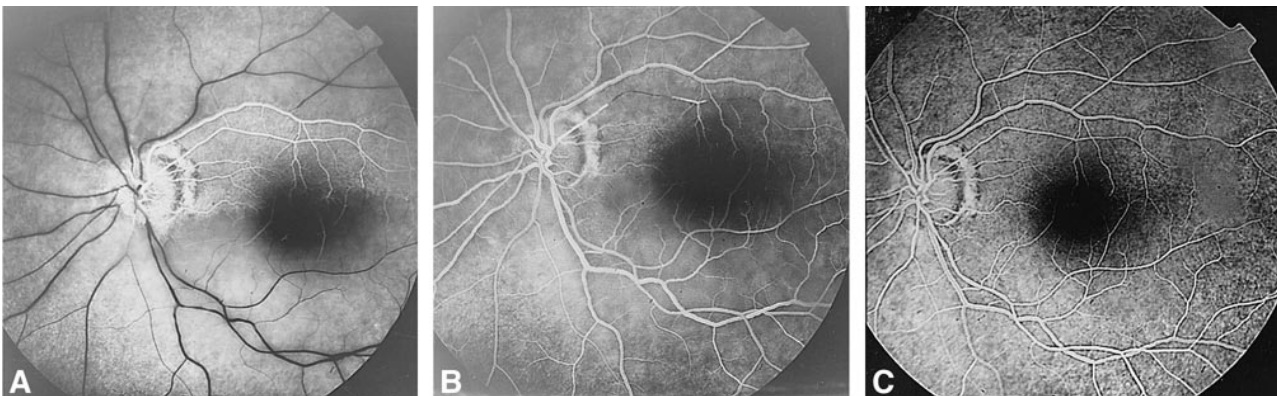


FIG 2. Case 2: Fluorescein angiography.

A, Before treatment, diffuse hypoperfusion of the retinal vessels is seen.

B, Immediately after treatment, nearly complete recanalization of the retinal vessels is detectable, with some small emboli present in the superior temporal quadrant.

C, Two days after thrombolysis, recanalization is complete.

evaluated by continuous ophthalmologic checking, and partly by the need to avoid high drug levels, which might provoke systemic complications. Treatment was halted upon the observation of improvement in vision and an increase in retinal blood flow.

### Conclusion

Our experience suggests that superselective fibrinolytic treatment may be a promising alternative to conservative and conventional therapeutic procedures for patients with CRAO. This technique requires close cooperation between ophthalmologists and neuroradiologists to select and treat patients as early as possible. Marked improvement or complete recovery can be achieved if the therapy is performed within the first 4 to 5 hours after the onset of visual impairment.

### References

1. Freitag HJ, Becker VU, Thie A, et al. **Lys-plasminogen as an adjunct to local intra-arterial fibrinolysis for carotid territory stroke: laboratory and clinical findings.** *Neuroradiology* 1996; 38:181-185
2. Nesbit GM, Clark WM, O'Neil OR, Barnwell SL. **Intracranial intraarterial thrombolysis facilitated by microcatheter navigation through an occluded cervical internal carotid artery.** *J Neurosurg* 1996;84:387-392
3. Urbach H, Ries F, Ostertun B, Solymosi L. **Local intra-arterial fibrinolysis in thromboembolic "T" occlusions of the internal carotid artery.** *Neuroradiology* 1997;39:105-110
4. Zeumer H, Freitag HJ, Knosp V. **Intravascular thrombolysis in central nervous system cerebrovascular disease.** In: Vinuela F, Dion J, Duckwiler G, eds. *Neuroimaging Clinics of North America: Interventional Neuroradiology*. Philadelphia: Saunders; 1992; 2:359-369
5. Schmidt D, Schumacher M, Wakhloo AK. **Microcatheter urokinase infusion in central retinal artery occlusion.** *Am J Ophthalmol* 1992;113:429-434
6. Schumacher M, Schmidt D, Wakhloo AK. **Intra-arterial fibrinolytic therapy in central retinal artery occlusion.** *Neuroradiology* 1993;35:600-605
7. Weber J, Lovblad KO, Remonda L, et al. **Intraarterial fibrinolysis in central retinal artery occlusion.** *Neuroradiology* 1997; 39(Suppl 1):S43
8. Gold D. **Retinal arterial occlusion.** *Am Acad Ophthalmol Otolaryngol* 1977;83:392-406
9. Simmonds NT. **Embolus of central retinal artery: successfully treated by paracentesis.** *Am J Ophthalmol* 1962;54:1129-1130
10. Duker JS, Sivalingam A, Brown GC, Reber R. **A prospective study of acute central retinal artery obstruction: the incidence of secondary ocular neovascularization.** *Arch Ophthalmol* 1991; 47:690-703