

# Generic Contrast Agents

Our portfolio is growing to serve you better. Now you have a *choice*.



FRESENIUS  
KABI

[VIEW CATALOG](#)

# AJNR

## Posterior Fossa Epithelial Cyst: Case Report and Review of the Literature

Hani Elmadbouh, Shawn F. S. Halpin, Jim Neal, Richard H. Hatfield and Margaret D. Hourihan

*AJNR Am J Neuroradiol* 1999, 20 (4) 681-685

<http://www.ajnr.org/content/20/4/681>

This information is current as of May 8, 2025.

## Posterior Fossa Epithelial Cyst: Case Report and Review of the Literature

Hani Elmadbouh, Shawn F. S. Halpin, Jim Neal, Richard H. Hatfield, and Margaret D. Hourihan

**Summary:** A 49-year old woman with progressive cranial nerve signs and hemiparesis was found at MR imaging and at surgery to have a cyst at the foramen magnum. Immunohistochemistry and electron microscopy showed an epithelial cyst of endodermal origin. MR findings were of an extraaxial mass, with short T1 and T2 times. Unless immunohistochemistry and electron microscopy are used in the final diagnosis of such cysts, all posterior fossa cysts lined by a single layer of epithelium should be described simply as epithelial cysts.

Cysts lined by a single layer of epithelium are generically described as epithelial cysts. There are, however, two distinctive types of epithelial cysts, characterized according to their origin as either endodermal or neuroepithelial. Unfortunately, these cysts have also been described as colloid (1–3), ependymal (4, 5), choroidal (6, 7), neuroepithelial (8, 9), enterogenous (10–12), neurenteric (13, 14), respiratory epithelial (15, 16), epithelial of endodermal origin (17), and epithelial (18–20). Most of these have been characterized by intraoperative observations and light microscopy, but recent developments in immunohistochemistry and electron microscopy have played an important role in the final diagnosis of these cysts.

We present a case of a posterior fossa epithelial cyst of endothelial origin, which was remarkable for its bright signal on T1-weighted MR images. This case illustrates the difficulty in making an accurate preoperative diagnosis of such a lesion.

### Case Report

A previously well 49-year-old woman had a 5-week history of progressive diplopia. She had also noticed mild right-sided weakness. The only abnormal findings on examination were a mild right hemiparesis and left fourth nerve palsy. MR images showed a mass extending from the foramen magnum, indenting the anterior surface of the medulla oblongata and lower pons. The mass was of high signal on T1-weighted images and

of mixed high and low signal on T2-weighted images (Fig 1A–D). There was no enhancement after injection of contrast material (Fig 1C). Vertebral angiography was unremarkable.

The preoperative radiologic diagnosis was of an extraaxial mass. We believed an unusual cyst to be the most likely diagnosis, but also considered a thrombosed aneurysm or dermoid in the differential diagnosis. A lobulated yellowish mass anterior to the brain stem was seen at surgery. When incised, a small amount of yellow fluid, with the appearance of pus, was drained. The larger part of the lesion was of a semisolid gelatinous consistency, which easily passed into a syringe. Part of this material, and the cyst wall, were sent for histopathologic examination. The clinical deficits resolved postoperatively, and a follow-up MR examination 1 year later showed resolution of mass effect and no evidence of cyst recurrence (Fig 1E). The patient remained asymptomatic 2 years later.

Pathologic study showed the lesion to be a cyst, the wall of which was composed of a thin layer of mostly columnar epithelium alternating with pseudostratified epithelium lying on a thin layer of connective tissue (Fig 1F–H). The columnar epithelium was ciliated and contained occasional cells with histologic features associated with mucin production, although they did not stain positively for PAS. Electron microscopy showed that the columnar and nonciliated pseudostratified epithelium alternated in distribution. The cytoplasm contained electron-dense granules within vacuoles (Fig 1H).

Immunohistochemistry showed positive staining of the cyst wall epithelium with cytokeratin and CAM 5.2 antibodies and negative staining with antigial fibrillary acidic protein (GFAP); in other words, the features of a colloid or endodermal cyst.

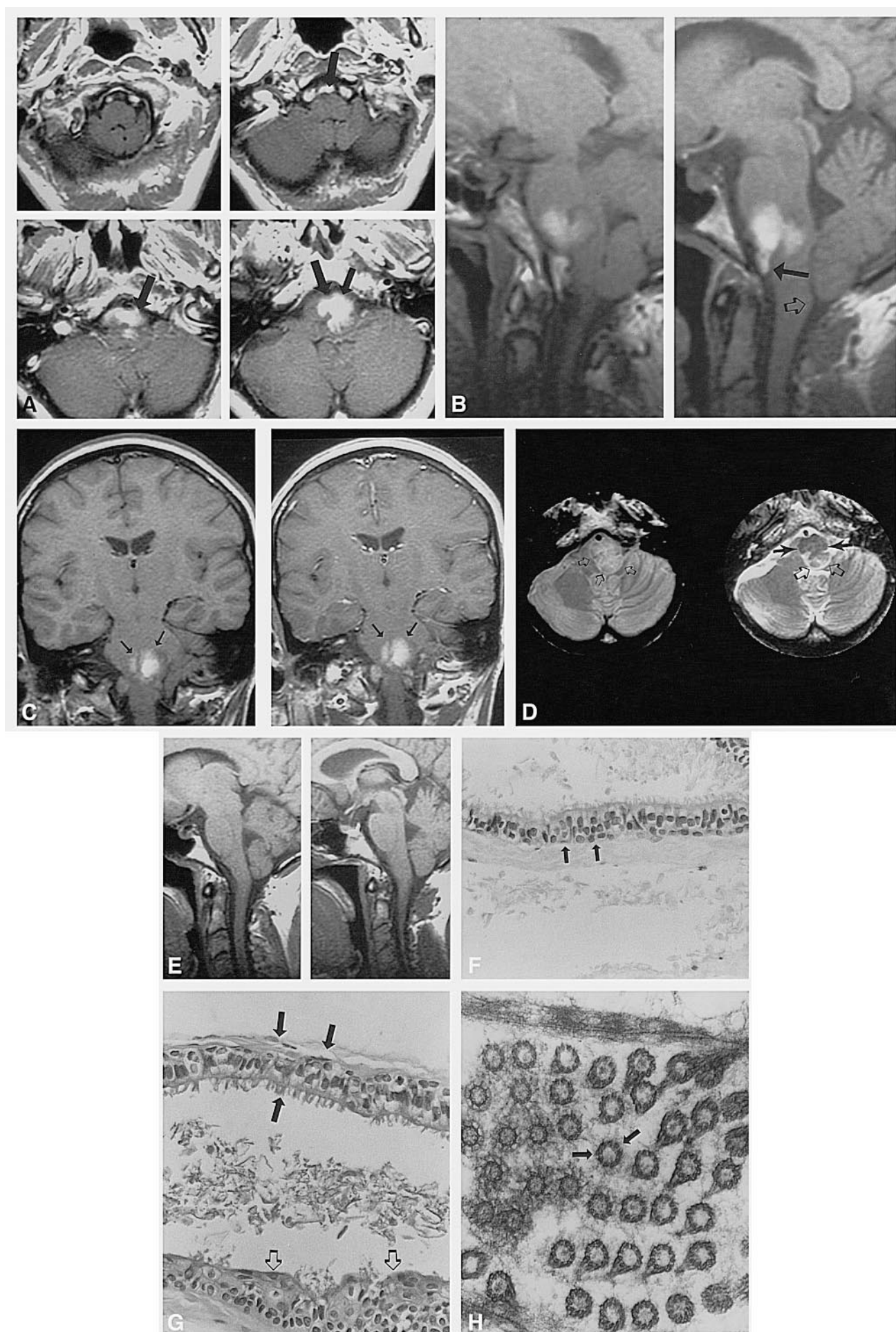
### Discussion

Cysts lined by a single layer of epithelium occur rarely in the posterior fossa, and an atypical imaging appearance, such as in this patient, may mean that the correct diagnosis is not immediately apparent. The neurosurgical approach to a cyst may be less invasive or complex than that for a tumor, and so familiarity with the possible radiologic appearances of this lesion may aid diagnosis and pre-surgical planning, and direct the prognostic advice given to the patient.

The diagnosis is most often made by intraoperative observation and light microscopy. The numerous synonyms for these cysts illustrate a degree of confusion regarding their histogenesis, but they fall into two main groups: endodermal or neuroectodermal (Table). Within the former category are epithelial cysts, which have connective tissue stroma, are lined by cuboidal or columnar epithelium, and have no definite histologic evidence of origin. When they occur within the ventricular system they are termed colloid cysts (1); otherwise, they are

Received January 26, 1998; accepted after revision August 17. From the Departments of Neuroradiology (H.E., S.F.S.H., M.D.H.), Neuropathology (J.N.), and Neurosurgery (R.H.H.), University Hospital of Wales, Heath Park, Cardiff.

Address reprint requests to Dr. Shawn F. S. Halpin, Department of Neuroradiology, University Hospital of Wales, Heath Park, Cardiff, Wales CF4 4XW.





called enterogenous or neurenteric (13–17), or simply epithelial cysts. Ependymal and choroidal cysts fall into the second category. Light microscopy often fails to differentiate between these cysts: for example, cilia are common to both ependymal and enterogenous cysts and there is a histologic similarity between these two entities and colloid cysts.

Electron microscopy, helps to further identify posterior fossa epithelial cysts. The walls of enterogenous cysts and colloid cysts are characterized by the presence of both columnar ciliated and nonciliated lining. The ciliated cells show a characteristic “9 + 2” structure (histologically, cilia are composed of 11 microtubules with nine arranged around the periphery and two in the center) with no granular coating material. Nonciliated cells with microvilli are present in every case with characteristic surface granular glycocalyx coating. They possess features of secretory function, have prominent nuclei, and, in some cases, tight junctions are present. The appearance is similar to that of respiratory epithelium and is consistent with an endodermal origin (13, 21, 22). In contrast, cysts with ependymal and choroid plexus lining are composed of a single cell type and show no signs of keratinization, mucin production, or glycocalyx coating.

Immunohistochemical techniques provide information about the origin of the cyst but do not always allow a definitive diagnosis (9, 23–25). The epithelium of choroid and ependymal cysts shows strong immunoreactivity for their corresponding epithelial markers, particularly GFAP and S100, while colloid and enterogenous cysts react to their tissue-specific epithelial markers, particularly CEA, but not to neuroepithelial markers. Immunohistochemistry, therefore, supports the neuro-origin of ependymal and choroid cysts and the endodermal nature of colloid and enterogenous cysts. Colloid cysts have a more disputed origin: although their microscopic and immunohistochemical reactivity indicate an endodermal origin, the diversity of the

normal ventricular lining has led some authors to make an analogy between colloid cyst and normal ventricular lining, since it is only the large secretory component responsible for the cyst that is unusual (26).

While electron microscopy and immunohistochemical studies suggest that epithelial cysts can be either endodermal or neuroectodermal in origin, only nine reported cases have been studied with both immunohistochemistry and electron microscopy. An endodermal origin was described for five of these (10) and the remainder (4, 6, 7) were reported to be of neuroepithelial origin.

Posterior fossa epithelial cysts resemble other developmental cysts on CT scans and appear as noncalcified low-density masses that do not enhance with contrast medium. It is usually not possible to differentiate among the many histologically distinct cystic lesions of the posterior fossa on CT studies. MR imaging is superior to CT, because coronal and sagittal views better depict anatomic relationships with the surrounding neural structures. The MR signal intensity helps to further characterize the composition and viscosity of the cyst contents (27, 28). MR imaging techniques, such as steady-state free precession, may provide better characterization of complex cystic masses and facilitate more appropriate preoperative diagnosis and planning (29). The MR signal intensity of epithelium-lined cysts is variable and depends on the secretory and breakdown products from the epithelium lining. These cysts may appear hypo-, iso-, or hyperintense relative to CSF on both short and long TR sequences (11, 14, 15, 17). Unfortunately, given the confused terminology of many descriptions of these cysts in the literature, it is difficult to ascertain whether the imaging characteristics will allow differentiation between endodermal and neuroepithelial cysts. Because only endodermal cysts produce mucin, one might speculate that a cyst with short T1 or CT hyperdensity is much more

←

FIG 1. 49-year-old woman with 5-week history of progressive diplopia.

A, Axial spin-echo T1-weighted noncontrast MR image (400/16/1 [TR/TE/excitations]; 256 × 192 matrix) shows a lesion with a short T1 signal projecting into the lower pons and upper medulla from an anterior extraaxial location (*arrows*).

B, Sagittal spin-echo T1-weighted image more clearly shows the extraaxial origin of the lesion (*closed arrow*). The brain stem is not significantly compressed or displaced, but the cervicomedullary junction and biventral lobules just project through the foramen magnum (*open arrow*).

C, Coronal T1-weighted images before (*left*) and after (*right*) contrast enhancement show no enhancing component to the lesion (*arrows*).

D, Axial fast spin-echo spin density-weighted (3700/19/1; echo train length, 3) (*left*) and T2-weighted (4200/92/1; echo train length, 8) (*right*) images. The cyst is of relatively high intensity on the spin density-weighted image (*small open arrows*) and of mixed intensity on the T2-weighted image, where a ventral short T2 component is seen (*closed arrows*) as well as a more dorsal component, which is approximately isointense with gray matter (*large open arrows*). It extends into the brain stem from an anterior and left-sided extraaxial location.

E, T1-weighted spin-echo image 1 year after surgery shows no evidence of recurrence of the lesion. The cervicomedullary junction has not changed its position, despite removal of the cyst.

F, Photomicrograph shows part of the cyst wall containing pseudostratified columnar epithelium (*arrows*) (hematoxylin-eosin, original magnification ×150).

G, Photomicrograph of part of the cyst wall containing columnar ciliated (*closed arrows*) and nonciliated pseudostratified columnar epithelium (*open arrows*) (hematoxylin-eosin, original magnification ×150).

H, Electron micrograph of the columnar ciliated epithelium shows the ultrastructural details of transversely cut microvilli demonstrating the “9 + 2” configuration (*arrows*). Note the prominent desmosomes between the adjacent cells (original magnification ×18,000).

Location and histologic features of endodermal and neuroectodermal cysts

	Location	Light Microscopy	Electron Microscopy	Immunohistochemistry
Endodermal				
Enterogenous/neuroenteric	Spine/posterior fossa	Mucus cells, double layer of cuboidal epithelium	Ciliated and nonciliated cells, tight junctions, microvilli and glycocalyx coat on nonciliated cells	Cytokeratin, epithelial membrane antigen, and carcino-embryonic antigen
Colloid	Intraventricular			
Neuroectodermal	Most common around choroidal fissures			
Choroid	Most common at trigones of lateral ventricles	Single layer of cuboidal epithelium, no mucus cells	Single cell type, no keratin, mucin, glycocalyx coat, or tight junctions	S100, GFAP
Ependymal	In the posterior fossa, most common at the cerebellopontine angle			
Arachnoid				

likely to be of endodermal origin. Although cholesterol breakdown products theoretically might be produced in either lesion if there is sufficient cellular desquamation, arachnoid, choroid plexus, and ependymal cysts nearly always have T1 and T2 MR signal characteristics similar to water, but may be hyperintense relative to water on spin-density images (30). If one accepts the colloid cyst, which very commonly has short T1 characteristics, as an endodermal lesion, then the presence of bright T1 signal in this patient's cyst adds further support to a hypothesis that uniformly bright cysts on T1-weighted MR images are most likely of endodermal rather than neuroectodermal origin. Hemorrhage into the cyst may be a confounding factor leading to T1 shortening, but this is not usually homogeneous in signal intensity, and will vary over time.

In contradistinction, since mucus is not always present in an endodermal cyst, a cyst that is isointense with CSF could be of either endodermal or neuroectodermal origin, and anatomic localization becomes the primary distinguishing radiologic feature.

The radiologic differential diagnosis will depend on the imaging characteristics of the lesion. If the cyst is iso- or hyperdense on CT scans, or has short T1, the differential diagnosis would include hemorrhage into an arachnoid cyst, an epidermoid cyst, a lipoma, or a thrombosed aneurysm. These four entities would not have been seriously considered in our patient because of the lesion location and the lack of overlying bone thinning militating against arachnoid cyst. Signal characteristics and CT density of epidermoid cysts are usually similar to CSF, so that they can be very difficult to outline; a lipoma would not give as low T2 signal on FSE T2-weighted images; and thrombus within an aneurysm is unlikely to return uniform signal, owing to the presence of more than one hemoglobin breakdown product. Dermoid cysts may contain fat, but usually also contain calcification or soft tissue so are not uniform in signal.

If a cyst has waterlike density or intensity, the differential would include simple arachnoid cyst, cystic schwannoma, and an inflammatory cyst, such as cysticercosis. A schwannoma would have an enhancing noncystic portion, and would usually show bone remodeling. Cysticercosis could be excluded in our patient because of lack of exposure, but a solitary cysticercosis cyst could be confused with an epithelial cyst.

Further subdivision of posterior fossa cysts beyond the major endodermal or neuroectodermal classification may not be clinically useful. Electron microscopy and immunohistochemistry can usually distinguish between the two neuroectodermal cysts, but this is unlikely to influence management. An intraventricular endodermal cyst is usually termed a colloid cyst simply because of its location, while a histologically identical extraaxial cyst would usually be termed neurenteric or enterogenous. Al-

though nearly half of neurenteric cysts in the spinal canal will be associated with a bony defect (31), this may simply reflect the embryologic passage of the cyst. The true prevalence of such bony defects in the posterior fossa is difficult to assess owing to the rarity of the lesion and the confusing nomenclature; certainly, such a defect was not present in our patient, although if such a defect were present, it would be important to point it out to the neurosurgeon to facilitate surgical planning.

Excision is the treatment of choice for small lesions, but may not relieve cranial nerve deficit (12). Incomplete excision has been reported (14). One cyst recurred 14 years after the initial procedure (12) and another 3 months (30) after incomplete excision. Seeding of the cyst contents during surgery has been suggested (14). Decompression and marsupialization into the subarachnoid space appears to be sufficient for large cysts.

### Conclusion

Detailed imaging and histologic findings in our patient suggest an endodermal origin to the cyst, but, in general, two distinctive types of posterior fossa epithelial cysts exist: cysts of endodermal origin (enterogenous and colloid) and cysts of neuroectodermal origin (ependymal, choroidal, arachnoid). The differentiation between these at light microscopy is sometimes difficult, and unless immunohistochemistry and electron microscopy are used in the final diagnosis, posterior fossa cysts lined by epithelium should be described simply as epithelial cysts, regardless of location.

### Acknowledgment

We are grateful for the expert technical assistance of A. Oversby, Electron Microscopy Unit, University Hospital of Wales, for the preparation of the electron microscopy material.

### References

- Parkinson D, Childe AE. Colloid cyst of the fourth ventricle: report of a case of two colloid cysts of the fourth ventricle. *J Neurosurg* 1952;9:404-409
- Shuangshoti S, Netsky MG. Neuro-epithelial (colloid) cysts of the nervous system: further observation on pathogenesis, location, incidence and histochemistry. *Neurology* 1966;16:887
- Shuangshoti S, Roberts MP, Netsky MG. Neuroepithelial (colloid) cysts: pathogenesis and relation to choroid plexus and ependyma. *Arch Pathol Lab Med* 1965;80:214-244
- Ho KL, Chason JL. A gliopendymal cyst of the cerebellopontine angle: immunohistochemical and ultrastructural studies. *Acta Neuropathol* 1987;74:382-388
- Rillet B, Berny J. Benign ependymal cyst of the pons. *Childs Brain* 1981;8:1-8
- Fakushima T, Hirakawa T, Tanaka A, et al. Choroidal epithelial cyst of the prepontine region: case report and ultrastructural study. *Neurosurgery* 1988;22:128-133
- Inoue T, Kuramatsu C, Lwata Y, et al. Symptomatic choroidal epithelial cyst of the fourth ventricle. *Surg Neurol* 1985;24:57-62
- Andrews BT, Halks-Miller M, Berger MS, Rosenblum ML, Wilson CB. Neuroepithelial cyst of the posterior fossa: pathogenesis and report of two cases. *Neurosurgery* 1984;15:91-95
- Shuangshoti S, Pitakdamrongwong N, Ponprasert B, Bhavilai D, Kasantikul V. Symptomatic neuroepithelial cysts in the posterior cranial fossa: immunohistochemical and electronmicroscopic studies. *Surg Neurol* 1988;30:298-304
- Walls TJ, Purohit DP, Aji WS, Achofield IS, Barwick DD. Multiple intracranial enterogenous cysts. *J Neurol Neurosurg Psychiatry* 1986;49:438-441
- Kak VK, Gupta RK, Sharma BS, Banerjee AK. Craniospinal enterogenous cyst: MR findings. *J Comput Assist Tomogr* 1990;14:470-472
- Chavda S, Davies AM, Cassa Pullicino VN. Enterogenous cysts of the central nervous system: a report of eight cases. *Clin Radiol* 1985;36:245-251
- Zalatani A. Neurenteric cyst of medulla oblongata: a curiosity. *Neuropediatrics* 1987;18:40-41
- Malcom GP, Symon L, Kendall B, Pires M. Intracranial neurenteric cysts: report of two cases. *J Neurosurg* 1991;75:115-20
- Del Bigio MR, Jay V, Drake JM. Prepontine cyst lined by respiratory epithelium with squamous metaplasia: immunohistochemical and ultrastructural study. *Acta Neuropathol* 1992;82:564-568
- Schelper RL, Kagan-Hallet KS, Huntington HW. Brain stem subarachnoid respiratory epithelial cysts: report of two cases and review of the literature. *Hum Pathol* 1986;17:417-422
- Mackenzie IR, Gilbert JJ. Cysts of the neuroaxis of endodermal origin. *J Neurol Neurosurg Psychiatry* 1991;54:572-575
- Umetzu Y, Rojas-Corona RR, Llana JF, Hirano A. Epithelial cysts in the central nervous system, characteristic expression of cytokeratins in an immunohistochemical study. *Acta Neurochir* 1990;107:93-101
- Clark C, Woodwall W, Nicoll JAR, Coakham HB. Intracerebral epithelial cyst: immunohistochemical diagnosis and endosurgical treatment. *Br J Neurosurg* 1989;3:507-512
- Ghatak NR, Hirano A, Kasoff SS, et al. Fine structure of an intracerebral epithelial cyst. *J Neurosurg* 1974;41:75-82
- Ho KL, Garcia JH. Colloid cysts of the third ventricle: ultrastructural features are compatible with endodermal derivation. *Acta Neuropathol* 1992;83:605-612
- Lach B, Scheithauer BW. Colloid cyst of the third ventricle: a comparative ultrastructural study of the neuroaxis cysts and the choroid plexus epithelium. *Ultrastruct Pathol* 1992;16:331-349
- Coca S, Martinez A, Vaquero J, et al. Immunohistochemical study of intracranial cysts. *Histol Histopathol* 1993;8:651-654
- Inoue T, Masushima T, Fukui M, Iwaki T, Takeshita I, Kuromatsu C. Immunohistochemical study of intracranial cysts. *Neurosurgery* 1988;23:567-581
- Inagaki H, Hori T, Ohama E. Immunohistochemical studies on choroidal epithelial cyst and neuroepithelial cyst: in comparison with normal choroid plexus and ependyma. *Noshuyo Byori* 1993;10:57-62
- Leech RW, Freeman T, Johnson R. Colloid cyst of the third ventricle: a scanning and transmission electron microscopic study. *J Neurosurg* 1982;57:108-113
- Ahmadi J, Savabi F, Apuzzo ML, Segall HD, Hinton D. Magnetic resonance imaging and quantitative analysis of intracranial cystic lesions: surgical implication. *Neurosurgery* 1994;35:199-207
- Kjos BO, Brant-Zawadzki M, Kucharczyk W, Kelly WM, Norman D, Newton TH. Cystic intracranial lesions: magnetic resonance imaging. *Radiology* 1985;155:363-369
- Tien RD, MacFall J, Heinz R. Evaluation of complex cystic masses of the brain: value of steady-state free-precession MR imaging. *AJR Am J Roentgenol* 1992;159:1049-1055
- Numaguchi Y, Kumra A, Schmidt Martino C. Non colloid neuroepithelial cysts in the lateral ventricles: MR features. *J Comput Assist Tomogr* 1988;12:174-181
- Osborn AG. Normal anatomy and congenital anomalies of the spine and spinal cord. In: *Diagnostic Neuroradiology*. St Louis: Mosby; 1994:813-815