

Generic Contrast Agents

Our portfolio is growing to serve you better. Now you have a *choice*.



FRESENIUS
KABI

[VIEW CATALOG](#)

AJNR

Uncommon Morphologic Characteristics in Leigh's Disease

Monika Warmuth-Metz, E. Hofmann, M. Büsse and L. Solymosi

AJNR Am J Neuroradiol 1999, 20 (6) 1158-1160

<http://www.ajnr.org/content/20/6/1158>

This information is current as
of May 5, 2025.

Case Report

Uncommon Morphologic Characteristics in Leigh's Disease

Monika Warmuth-Metz, E. Hofmann, M. Büsse, and L. Solymosi

Summary: We describe a 4-month-old male patient with severe developmental delay and elevated lactate in blood and CSF. The MR images showed abnormalities differing from the typical pattern found in association with Leigh's disease. The examination of fibroblast cultures showed diminished activity of mitochondrial complexes I and III. The patient died at the age of 9 months.

In 1951, Leigh (1) described a subacute necrotizing encephalomyelopathy, a hereditary neurodegenerative disorder usually affecting young children and inevitably leading to death. The disturbances of the mitochondrial energy metabolism are varying, and they affect different complexes of the mitochondrial energy production. In autopsy series, usually symmetrical lesions are found mainly in the brain stem, medulla oblongata, midbrain, and basal ganglia. Because the histologic appearance is similar to that of Wernicke's encephalopathy, association with vitamin B deficiency was suspected but never confirmed (2, 3). In discrimination from Wernicke's disease, involvement of the mamillary bodies was described as very unusual (3–6). Additionally, contrast enhancement was only scarcely reported, although the histologic appearance combined necrosis with capillary proliferation (5, 7). We report the unusual MR features of an infant with Leigh's disease.

Case Report

During an uneventful pregnancy, hydrocephalus was discovered in a male fetus by using ultrasonography. After birth, the infant was treated by shunting and CT showed an abnormal slightly hyperdense lesion in the midbrain, with swelling of the periaqueductal region. The basal ganglia and the white matter were slightly hypodense, and the ventricles were very narrow, probably representing slit ventricles after shunting. At the age of 4 months, the patient showed a developmental delay, abnormal eye movements, nystagmus, and reduced visual acuity. To elucidate the underlying pathologic abnormality, MR imaging was performed.

Received June 14, 1998; accepted after revision, November 23.

From the Department of Neuroradiology (M.W.-M., E.H., L.S.) and Pediatrics (M.B.), University of Würzburg, Würzburg, Germany.

Address reprint requests to Monika Warmuth-Metz, MD, Department of Neuroradiology, University of Würzburg, Josef-Schneider-Str.11, D-97080 Würzburg, Germany.

© American Society of Neuroradiology

MR Imaging

On T2-weighted (1969/100/1 [TR/TE/excitations]) images, the caudate nuclei, the periventricular white matter of both hemispheres, most pronounced in the frontal lobes (Fig 1A), the periaqueductal region, and the dentate nuclei of the cerebellum showed a symmetrical increase in intensity, whereas, based on the patient's age, most of the white matter was unmyelinated and hyperintense. The third and lateral ventricles were very narrow and seemed to be compressed by the basal ganglia. A shunt was seen in the right lateral ventricle. Although the caudate nuclei were hypointense on T1-weighted images (460/20/1), the periventricular white matter of the hemispheres showed a homogeneous increase in signal compared with normal-appearing white matter (Fig 1B). This hyperintensity was most pronounced in the frontal lobes. After the application of IV administered contrast medium, we saw a striking enhancement not only in both striate bodies, the periaqueductal gray matter, and the dentate nuclei of the cerebellum but also in the periventricular white matter of the hemispheres, in the hypothalamus, and in both mamillary bodies (Fig 1C and D).

Laboratory and Biochemical Tests

Lactate and pyruvate in the blood were increased. The CSF showed definite pleocytosis of 21 predominantly lymphocytic cells. Protein and lactate were increased. A biochemical analysis of a muscle biopsy was normal except for a marginal diminution of carnitine. Analysis of a fibroblast culture of a skin biopsy showed evidence of a reduction in activity of complexes I and III in mitochondria.

Further Course of the Disease

The patient experienced two epileptic seizures during hospitalization. After a short period of clinical improvement, he deteriorated rapidly, with feeding problems and weight loss. At the last presentation, he showed reduced spontaneous movements, rigidity, myoclonic jerks of the extremities, and abrupt regularly repeated upward movements of both arms. He died at the age of 9 months, and autopsy was not performed.

Discussion

Histopathologic lesions in subacute necrotizing encephalomyelopathy consist of spongiform degeneration, capillary proliferation, and gliosis in various parts of the medulla, brain stem, pontine and midbrain tegmentum, basal ganglia, cerebellar white matter, and cortex of the brain (8). Reports on the findings of CT and MR imaging have been inconsistent. Although Kissel et al (9) stated that the red nuclei were characteristically spared in Leigh's disease, Heckman et al (10) reported the contrary observation. Putamenal lesions were de-

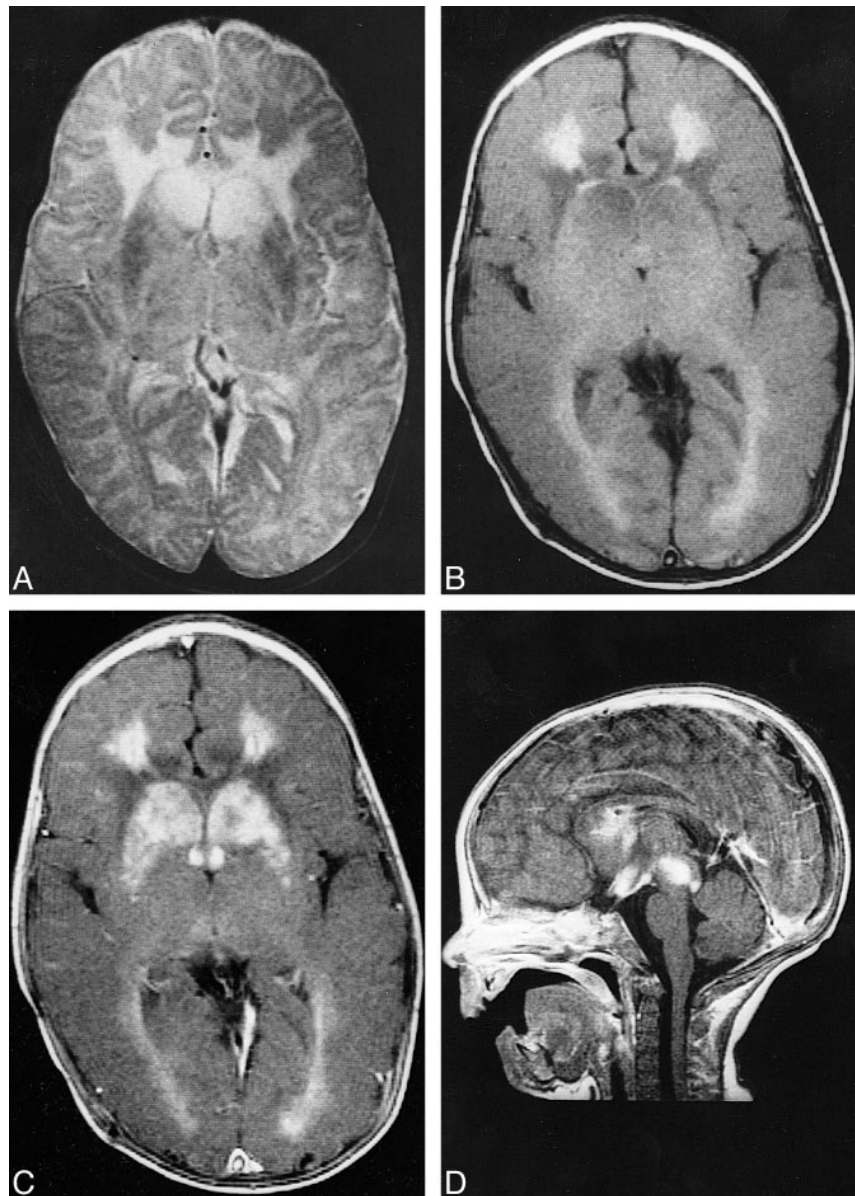
FIG 1. 4-month-old male patient with severe developmental delay and elevated lactate in blood and CSF.

A, T2-weighted image showing striking hyperintensity in the periventricular frontal white matter and the caput of the dentate nuclei on both sides. Because of the swollen dentate nuclei, the frontal horns of the lateral ventricles are compressed.

B, Unenhanced, axial T1-weighted MR image obtained at the level of the third ventricle (same level as that shown in A). The third and lateral ventricles are compressed by the basal ganglia and thalami. Note the marked symmetrical hyperintensity of the frontal and less pronounced occipitoparietal white matter.

C, The same plane as that shown in B obtained after the injection of contrast medium. Although the striate bodies show dense symmetrical enhancement, the thalami take up contrast material only around the dorsal part of the third ventricle. There is also intensive enhancement of the white matter and the swollen mamillary bodies.

D, Midsagittal T1-weighted contrast-enhanced MR image. No abnormality is seen caudal to the plane of the inferior colliculi. Periaqueductal enhancement, as well as hypothalamic and mamillary body enhancement, is very dense.



scribed as characteristic (3–5, 9, 11), and Medina et al (5) stated that missing involvement of the putamen argues against Leigh's disease in patients with lactic acidosis. Large autopsy series (8), however, and a few radiologic reports (10, 12) present cases without putamenal lesions.

Because of the pathohistologic similarity, discrimination from Wernicke's encephalopathy is necessary, either on clinical grounds or based on normal levels of thiamine. A proposed discriminating feature seemed to be the noninvolvement of the mamillary bodies, which are regularly affected in Wernicke's disease. Although the histopathologic description of a vascular proliferation in the lesion would suggest the possibility of contrast enhancement, reports of contrast accumulation on CT scans or MR images are scarce (7), describing only marginal lesional enhancement.

Our patient suffered from symptoms that were highly suggestive of Leigh's disease, such as oculomotor problems, feeding difficulties, epileptic seizures, myoclonias, clonic jerks of the arms, rigidity, and diminished spontaneous activity of the extremities. Biochemical testing of a skin biopsy was positive for disturbances in mitochondrial complexes I and III, and lactate was elevated in blood and CSF. No vitamin B deficiency or other reasons for Wernicke's encephalopathy could be found. The imaging results differed from those of current reports in the literature because we found unambiguous involvement of both mamillary bodies and a striking contrast enhancement in the affected parts of the brain.

Additionally, involvement of cerebral white matter is very unusual (11) but was definitely present in our patient. The relatively high signal

in the cerebral white matter on T1-weighted images, particularly in the frontal lobes, might either represent degradation products of blood or myelin. The pathohistologic reports of gliosis in lesions of Leigh's disease argue in favor of myelin degradation, whereas in acute necrosis, bleeding also could be possible (11). The CT scans of the patient that were obtained soon after his birth did not show evidence of hemorrhage but instead showed hypodensity of the affected areas.

The intrauterine diagnosis of hydrocephalus reflects the first symptoms of periaqueductal mass lesion and is obviously related to the swollen lesions seen on later MR images. Perhaps the very early development of lesions and symptoms in our patient is the clue to the uncommon morphologic characteristics. In accordance with the rapidly fatal course of disease, the swelling and the very intense contrast enhancement of the affected brain structures that, to the best of our knowledge, have not been described previously might represent a very fulminant form of subacute necrotizing encephalomyelopathy.

References

1. Leigh D. **Subacute necrotizing encephalomyelopathy in an infant.** *J Neurol Neurosurg Psychiatry* 1951;14:216-221
2. Geyer CA, Sartor KJ, Prensky AJ, Abramson CL, Hodges FJ, Gado MH. **Leigh disease (subacute necrotizing encephalomyelopathy): CT and MR in five cases.** *J Comput Assist Tomogr* 1988;12:40-44
3. Feigin I, Wolf A. **A disease in infants resembling chronic Wernicke's encephalopathy.** *J Pediatr* 1954;45:-243
4. Koch TK, Yee MHC, Hutchinson HAT, Berg BO. **Magnetic resonance imaging in subacute necrotizing encephalomyelopathy (Leigh disease).** *Ann Neurol* 1986;19:605-607
5. Medina L, Chi TL, DeVivo DC, Hilal SK. **MR findings in patients with subacute necrotizing encephalomyelopathy (Leigh syndrome): correlation with biochemical defect.** *AJNR Am J Neuroradiol* 1990;11:379-384
6. Masó E, Ferrer I, Herraiz J, Roquer J, Serrano S. **Leigh's syndrome in an adult.** *J Neurol* 1984;231:253-257
7. Taccone A, Di Rocco M, Fondelli P, Cottafava F. **Leigh disease: value of CT in presymptomatic patients and variability of the lesions with time.** *J Comput Assist Tomogr* 1989;13: 207-210
8. Montpetit VJA, Andermann F, Carpenter S, Fawcett JS, Zborowska-Sluis D, Giberson HR. **Subacute necrotizing encephalomyelopathy.** *Brain* 1971;94:1-30
9. Kissel JT, Kolkin S, Chakares D, Boesel C, Weiss K. **Magnetic resonance imaging in a case of autopsy-proven adult subacute necrotizing encephalomyelopathy (Leigh's disease).** *Arch Neurol* 1987;44:563-566
10. Heckman JM, Eastman R, Handler L, Wright M, Owen P. **Leigh disease (subacute necrotizing encephalomyelopathy): MR documentation of the evolution of an acute attack.** *AJNR Am J Neuroradiol* 1993;14:1157-1159
11. Valanne L, Ketonen L, Majander A, Suomalainen A, Pikho H. **Neuroradiological findings in children with mitochondrial disorders.** *AJNR Am J Neuroradiol* 1998;19:369-377
12. DiMauro S, Servidei S, Zevani M et al. **Cytochrome C oxidase deficiency in Leigh syndrome.** *Ann Neurol* 1987;22:498-506