

Are your **MRI contrast agents** cost-effective?

Learn more about generic **Gadolinium-Based Contrast Agents**.



**FRESENIUS
KABI**

caring for life

AJNR

Surgically Induced Intracranial Contrast Enhancement: Potential Source of Diagnostic Error in Intraoperative MR Imaging

Michael Knauth, Nurdagül Aras, Christian Rainer Wirtz, Arnd Dörfler, Tobias Engelhorn and Klaus Sartor

This information is current as of April 18, 2024.

AJNR Am J Neuroradiol 1999, 20 (8) 1547-1553
<http://www.ajnr.org/content/20/8/1547>

Surgically Induced Intracranial Contrast Enhancement: Potential Source of Diagnostic Error in Intraoperative MR Imaging

Michael Knauth, Nurdagül Aras, Christian Rainer Wirtz, Arnd Dörfler, Tobias Engelhorn, and Klaus Sartor

BACKGROUND AND PURPOSE: Intraoperative MR imaging is being used increasingly during neurosurgical interventions. The aim of this study was to describe and classify different forms of surgically induced intracranial contrast enhancement observed during intraoperative MR examinations.

METHODS: A total of 51 intraoperative MR examinations were performed to assess the extent of brain tumor removal. The intraoperative MR results (T1-weighted images, unenhanced and obtained serially after the IV administration of paramagnetic contrast material) were compared with preoperative and early postoperative MR findings. Animal experiments were conducted to obtain further evidence of the mechanism of surgically induced contrast enhancement.

RESULTS: Four different types of surgically induced contrast enhancement were found: meningeal enhancement, increased enhancement of the choroid plexus, delayed enhancement at the resection margins, and immediate intraparenchymal contrast enhancement. The types of surgically induced contrast enhancement differ regarding their location, configuration, and time course. Their potential to be confused with contrast-enhancing, residual tumor also varies. Three of the four types of surgically induced contrast enhancement were reproducible in an animal model.

CONCLUSION: Surgically induced contrast enhancement is a potential source of error in intraoperative MR imaging. Careful analysis of the location, configuration, and time course of intraoperatively observed intracranial enhancement is critical to avoid confusing surgically induced contrast enhancement with contrast-enhancing, residual tumor.

CT and sonography have been used during neurosurgical operations (1–3). With the advent of the so-called open scanners, MR imaging, the imaging method with the highest soft-tissue resolution, now can be used intraoperatively to guide the neurosurgeon and to control the extent of tumor resection (4–8). Nonetheless, because there have been reports of postsurgical contrast enhancement on postoperative MR examinations (9–15), surgically induced contrast enhancement (ie, enhancement that is caused by the surgical manipulation itself) might also exist on intraoperative MR examinations. The

danger this represents is that surgically induced contrast enhancement potentially can be confused with residual tumor enhancement, thus leading to unnecessary further resection. The aim of this study was to describe and characterize the different forms of surgically induced contrast enhancement in intraoperative MR imaging to minimize the danger of confusion with residual tumor enhancement.

Methods

Patient Study

A total of 51 intraoperative MR examinations were performed in 48 patients to assess the extent of brain tumor resection. The setup of the intraoperative MR unit was identical to that previously described (4, 6). The field strength was 0.2 T.

Twelve patients underwent surgery for nonenhancing, low-grade gliomas, two patients had solitary intracranial metastases, and the remaining patients underwent surgery for high-grade gliomas and glioblastomas multiforme. Imaging consisted of T1-weighted spin-echo sequences that were obtained before and serially (5, 10, and 20 minutes) after the IV administration of a double dose (0.2 mmol of gadolinium diethylenetriamine penta-acetic acid/kg of body weight) of a

Received October 12, 1998; accepted April 17, 1999.

From the Departments of Neuroradiology (M.K., N.A., A.D., T.E., K.S.) and Neurosurgery (C.R.W.), University of Heidelberg Medical School, Im Neuenheimer Feld 400, D 69120 Heidelberg, Germany.

Part of this work was presented at the 1997 ASNR meeting in Toronto.

Address reprint requests to Michael Knauth, MD, University of Heidelberg Medical School, Department of Neuroradiology, Im Neuenheimer Feld 400, D 69120 Heidelberg, Germany.

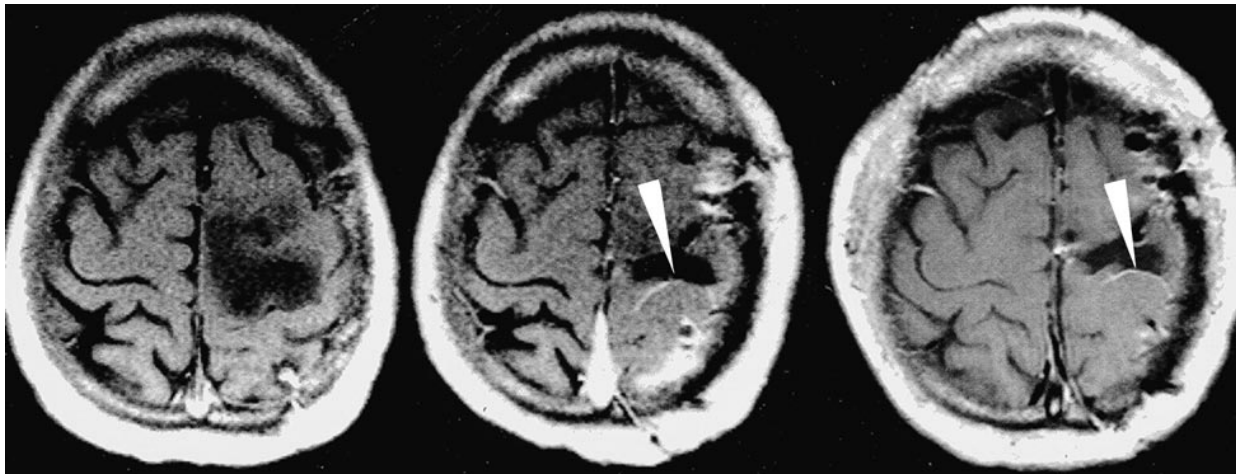


Fig 1. Surgically induced meningeal enhancement. The preoperative MR image (*left*) (674/20/2) does not show contrast enhancement of the pial surface in the central sulcus, which clearly enhances on the intraoperative MR examination (*middle, arrow*) (532/15/3). This enhancement persists on the early postoperative MR examination (*right, arrow*) (674/20/2).

paramagnetic contrast agent. Because we were examining anesthetized patients, the timing of the imaging was identical in all patients. A double dose of contrast agent was used, because at low-field imaging, it yielded the same lesion-to-white matter contrast as in high-field MR examinations after the administration of a standard dose (0.1 mmol/kg) (unpublished results), ie, an enhancing tumor showed the same lesion-to-white matter contrast in the intraoperative (low-field) MR examinations as in the pre- and postoperative (high-field) MR examinations. The imaging parameters of the intraoperative MR imaging were 15/532/3 (TE/TR/excitations); section thickness, 6 mm; field of view, 230 × 230 mm; matrix, 192 × 256; and acquisition time, 5 minutes 10 seconds. In the cases of low-grade gliomas, an additional T2-weighted sequence was obtained before the IV administration of the contrast agent. The intraoperative unenhanced and postcontrast T1-weighted images were compared with preoperative and early postoperative T1-weighted images obtained with a high-field scanner (1.5 T) after the IV administration of a single dose (0.1 mmol/kg) of a paramagnetic contrast agent. Early postoperative MR examinations were performed on days 1 to 3 after surgery. The imaging parameters of the T1-weighted images of the high-field examinations were 20/674/2; section thickness, 6 mm; field of view, 230 mm; matrix, 192 × 256; and acquisition time, 3 minutes 14 seconds.

Surgically induced contrast enhancement was said to be present if the intraoperative postcontrast T1-weighted images showed contrast enhancement that had not been observed on MR images before the operation (maximum of 3 days). Surgically induced contrast enhancement was classified regarding its location, configuration, time course, and appearance on the early postoperative MR images.

The study was approved by our institution's review board, and informed consent was obtained from all patients before the intraoperative examinations were performed.

Animal Experiments

Animal experiments were conducted in accordance with national animal protection laws. The aim of the animal experiments was to reproduce different types of surgically induced contrast enhancement to obtain information about their etiology. For this, 24 male Wistar rats were divided into three groups: in the control group, only a small craniotomy without dural opening was performed; in the second group, the cortex and underlying white matter were ablated by means of a sharp spoon; and in the third group, superficial electrocoagulation of the cortex

was performed. The aim was to produce brain lesion types *with* and *without* vessel opening. Thirty minutes after inducing the different types of brain lesions (or after simple craniotomy), the animals were examined with a high-field MR scanner (1.5 T). A high-field scanner was used to obtain better signal-to-noise ratios in the small animal brains. The use of different field strengths (low-field in patients and high-field in rats) did not seem problematic because, in the animals, we focussed on the configuration and time course of surgically induced contrast enhancement rather than the absolute amount of enhancement. The imaging protocol consisted of T1-weighted sequences obtained before and serially (5, 10, and 15 minutes) after the IV administration of a single dose (0.1 mmol/kg) of a paramagnetic contrast agent. The imaging parameters were 20/500/4; section thickness, 2 mm; field of view, 65 mm; matrix, 256 × 256; and acquisition time, 4 minutes 16 seconds.

Results

Patient Study

Surgically induced enhancement was observed in all patients. Four different types could be distinguished: meningeal enhancement, increased enhancement of the choroid plexus, linear enhancement at the resection margins, and immediate intraparenchymal contrast enhancement.

Meningeal enhancement was seen in all patients as linear enhancement of the leptomeninges or the dura or both. On the intraoperative MR image, enhancement was already visible on the first postcontrast study and remained stable during the observation period (20 minutes). On the early postoperative MR study, it was either the same as observed intraoperatively or had even increased (Fig 1).

Because the normal choroid plexus already shows contrast enhancement, enhancement of the choroid plexus is not surgically *induced* but surgically *increased*. It was observed in seven patients (13.7%) and simply consisted of increased enhancement of the choroid plexus on one side compared with the other (Fig 2). In each patient in

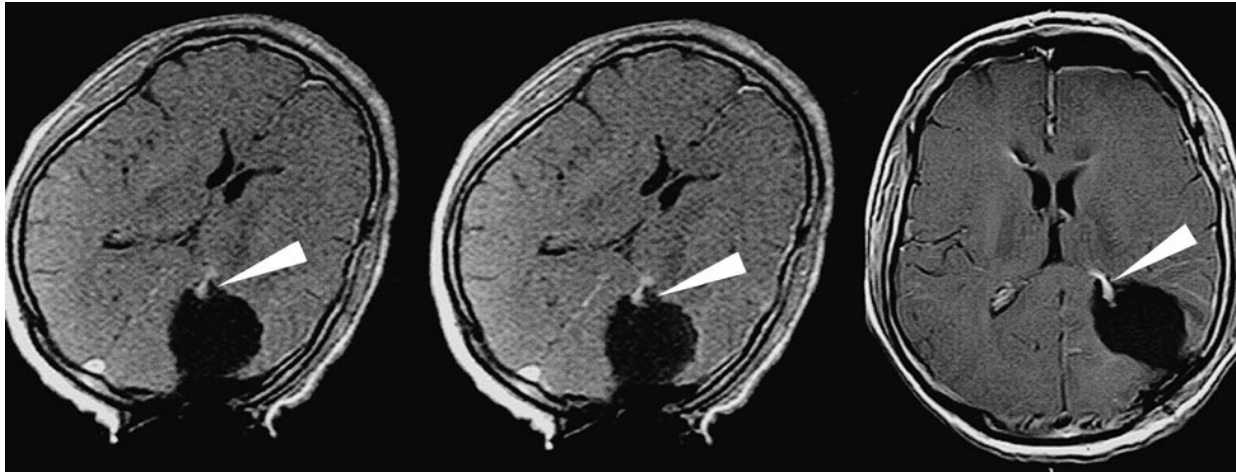


FIG 2. Surgically induced, increased enhancement of the choroid plexus. Note that the ventricle has been opened. Intraoperative T1-weighted images (*left*, 5 minutes postcontrast; *middle*, 20 minutes postcontrast) (532/15/3) show increased enhancement of the left choroid plexus (*arrows*) that remains constant during the observed time interval. Early postoperative MR image (*right*) (674/20/2) shows the persistence of this enhancement (*arrow*).

whom increased enhancement of the choroid plexus was observed, the ventricle had been opened surgically. In each of four other patients, however, a ventricle also had been opened but no increased enhancement of the choroid plexus was observed. It is likely that additional factors such as manipulation of the choroid plexus or exposure to air are necessary to produce this type of increased enhancement. On the early postoperative MR images, the degree of enhancement was either equal to that observed intraoperatively or had even increased.

In 41 patients (80.4%), a linear enhancement at the resection margins was visible that was more pronounced the more time elapsed from the injection of the paramagnetic contrast agent (Fig 3). In some cases, contrast agent diffused into the saline-filled resection cavity, leading to increasingly higher signal of the fluid (Fig 3). In early postoperative MR examinations, this kind of enhancement either was reduced markedly or absent (Fig 3). Because of its typical location, configuration, and time dependence, confident diagnostic separation from enhancing, residual tumor was the rule, although we did encounter some more difficult cases.

In five patients (9.8%), intraparenchymal enhancement was observed that was already fully developed in the first postcontrast study and showed practically no time dependence in the observed period thereafter (Fig 4). In contrast to the delayed enhancement at the resection margins, the immediate intraparenchymal enhancement had a "solid," sometimes almost nodular, appearance. Thus, immediate intraparenchymal enhancement has the same appearance and time course as enhancing residual tumor.

In all but one patient, in whom immediate intraparenchymal enhancement was observed, bleeding had necessitated repeated electrocoagulations in the region where the immediate intraparenchymal enhancement was later observed. In the other case,

sonographic aspiration had been performed at the border between enhancing and nonenhancing tissue. In early postoperative MR examinations, the immediate intraparenchymal enhancement either was reduced markedly or absent (Fig 4).

Animal Experiments

Surgically induced enhancement was observed in all animals. Intraparenchymal enhancement was observed even in the control group (ie, in the animals in which only craniotomy had been performed). We take this as an indicator that our craniotomy technique was not as atraumatic to the brain as we intended it to be. In all animals in which electrocoagulation of the cortex had been performed, immediate intraparenchymal enhancement with practically no time dependence was observed (Fig 5), indicating a blood-brain barrier disruption. This type of enhancement, however, was also present in six of the eight animals in which an ablation of the cortex and the underlying white matter had been performed. In two of these animals, delayed, time-dependent enhancement was seen at the resection margin (Fig 6). In contrast, delayed enhancement at the resection margins was not seen in any of the animals of the control group or in any of the animals in which electrocoagulation of the cortex had been performed.

All rats showed some degree of dural enhancement regardless of the type of lesion inflicted on the brain. Thus, three of the four types of surgically induced contrast enhancement described above were reproduced in the animal model.

Discussion

The danger that surgically induced contrast enhancement represents for the interpretation of intraoperative MR findings is that it mistakenly can

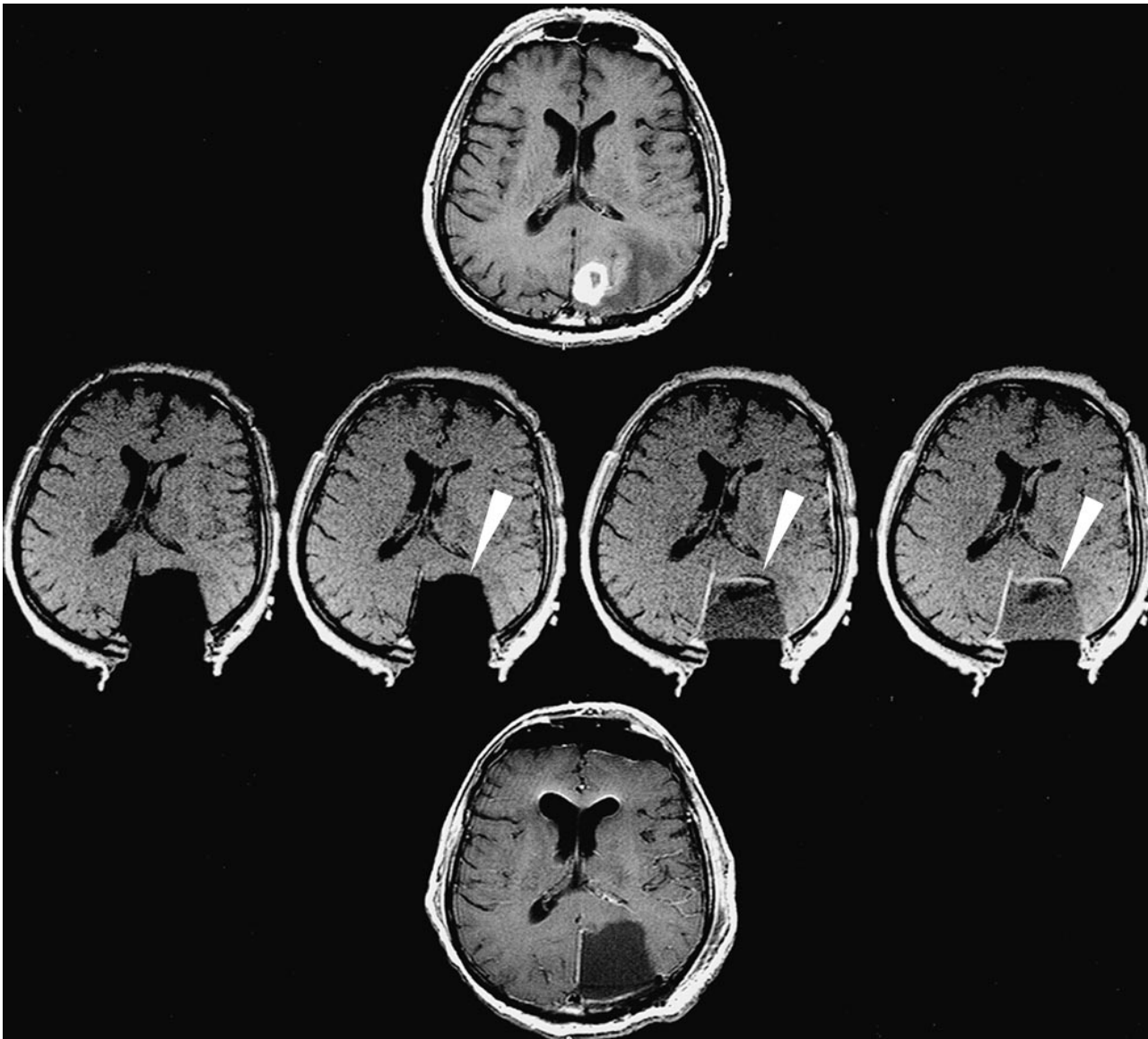


FIG 3. Surgically induced, delayed (time-dependent) enhancement at the resection margins. Preoperative MR image (*top*) (674/20/2) shows a left occipital, contrast-enhancing tumor. Intraoperative T1-weighted images (*middle* [from *left to right*], unenhanced and 5, 10, and 20 minutes postcontrast) (532/15/3) show linear enhancement at the resection margin, which is more pronounced the more time has elapsed since the administration of the contrast agent (*arrows*). Also note the diffusion of the contrast agent into the fluid-filled resection cavity, leading to increased signal intensity of the fluid on the delayed images. The probable cause of this type of surgically induced contrast enhancement is leakage of contrast agent out of surgically opened blood vessels. The enhancement is not present on the preoperative (*top*) or postoperative (*bottom*) MR images (674/20/2).

be diagnosed as enhancing, residual tumor. The first two types of surgically induced contrast enhancement, meningeal enhancement and increased enhancement of the choroid plexus, do not present a problem because there is practically no potential of confusion with residual, enhancing tumor. Meningeal enhancement can be identified in early postoperative MR examinations (10), and our study found that meningeal enhancement is already visible very early (ie, during the course of surgery). The delayed enhancement at the resection margins is somewhat more difficult. Its time dependence, location, configuration, the observed diffusion of contrast agent into the fluid-filled resection cavity,

and the fact that this type of enhancement is either reduced or absent on the early postoperative MR examination suggest that leakage of contrast media out of surgically opened vessels at the resection margin is the cause. This assumption also is supported by the results of animal experiments in which this type of enhancement was exclusively produced in animals in which a vessel-opening brain lesion had been created by ablation. Time dependence, location, and configuration are the key features for distinguishing this type of surgically induced contrast enhancement from residual enhancing tumor. Nonetheless, overlap exists and confident diagnostic separation is possible in most

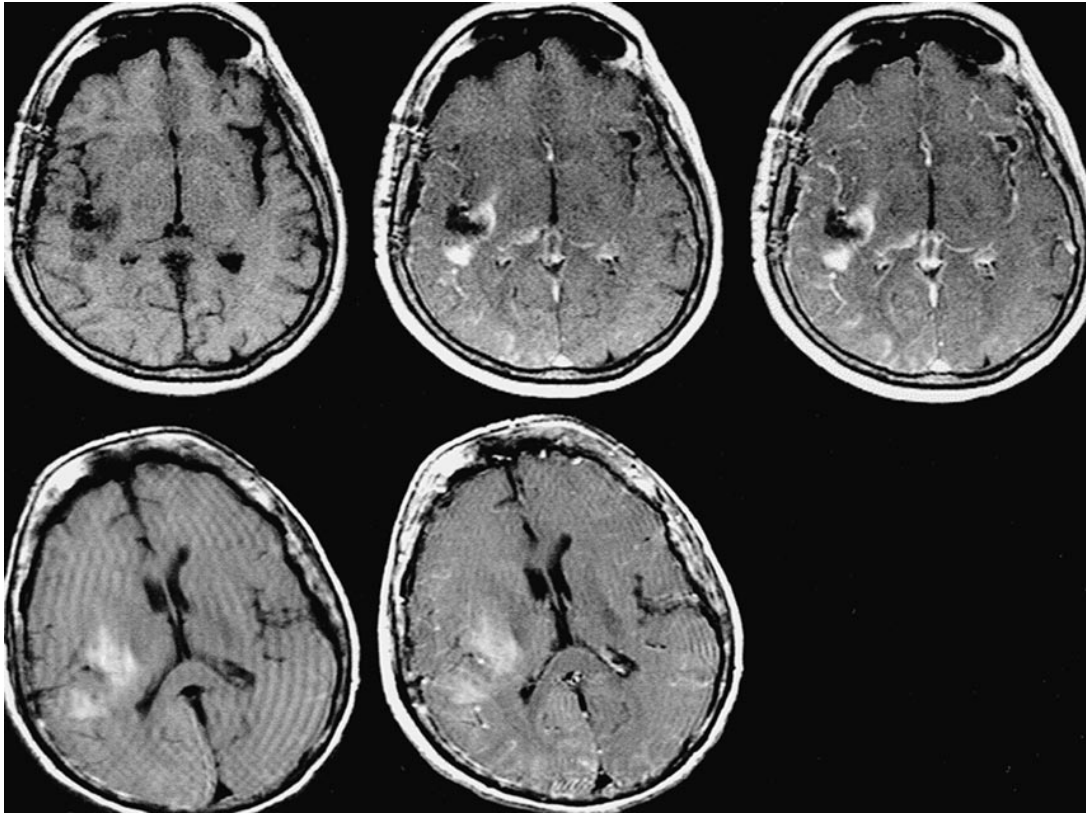


FIG 4. Surgically induced immediate intraparenchymal enhancement. Intraoperative T1-weighted images (*upper row* [from *left to right*], unenhanced and 5 and 20 minutes postcontrast) (532/15/3) show a solid-appearing, intraparenchymal contrast enhancement that shows almost no time dependence. Early (day 1 after surgery) postoperative T1-weighted images (*lower row: left*, unenhanced; *right*, post-contrast) show a intraparenchymal hyperintensity but no contrast enhancement (674/20/2). This type of enhancement probably represents (transient) blood-brain barrier disruption. The hyperintensity on the unenhanced T1-weighted images of the postoperative examination is possibly caused by contrast agent administered intraoperatively, which is "captured" in the tissue after the blood-brain barrier disruption resolves. It is, however, too early to represent methemoglobin.

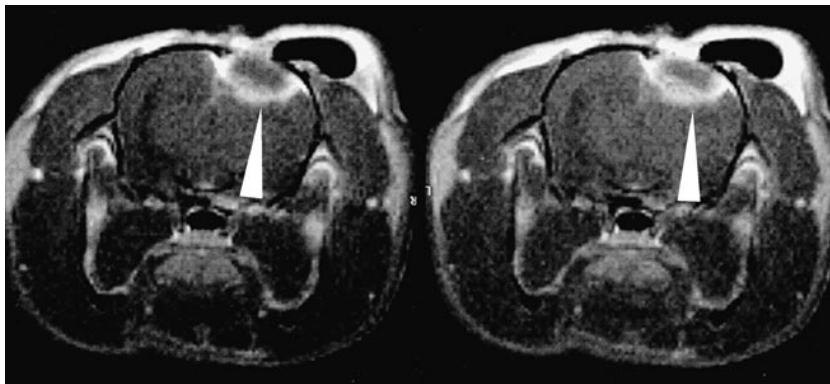


FIG 5. Animal model of surgically induced immediate intraparenchymal enhancement. In all animals in which a cortical electrocoagulation (non-vessel-opening brain lesion) had been performed, an intraparenchymal and non-time-dependent contrast enhancement (*arrows*) surrounding a zone of necrosis was observed. Post-contrast T1-weighted images (from *left to right*, 5 and 15 minutes after administration of the contrast agent) (500/20/4).

but not all cases. Figure 7 shows a case that is problematic in this respect.

The most confounding surgically induced contrast enhancement is the immediate intraparenchymal enhancement, because residual, enhancing tumor has the same appearance and time course. In such cases, a comparison with the preoperative MR examination is essential. Whenever we observed immediate intraparenchymal enhancement intraoperatively, some additional surgical damage (mostly repeated electrocoagulation) had been done

to the brain tissue. It likely represents surgically induced blood-brain barrier disruption, similar to that described after therapeutic brain lesions (16, 17). In these studies, however, the perilesional enhancement persisted during longer periods of time, whereas in our study, the enhancement already was reduced markedly or even absent on the early postoperative MR studies (ie, the blood-brain barrier disruption was transient). This difference may simply reflect the lesser amount of deposited energy and subsequent tissue damage in our patients as

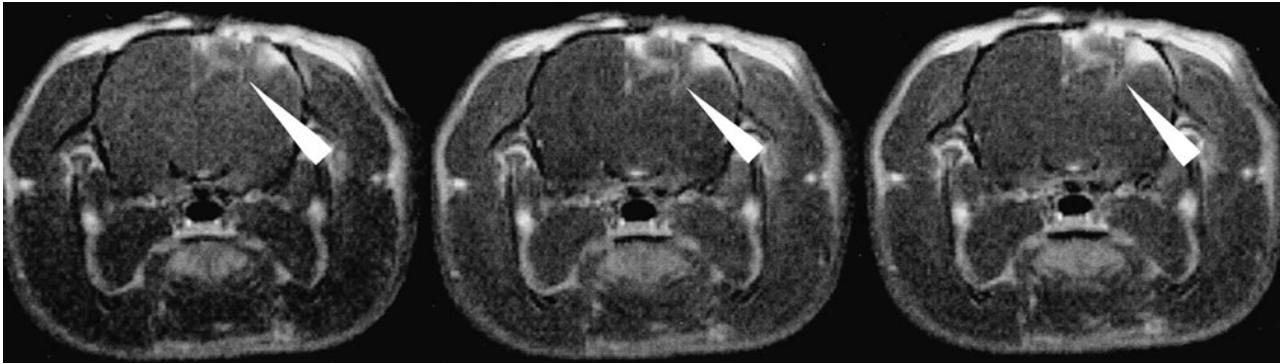

FIG 6. Animal model of surgically induced delayed (time-dependent) enhancement at the resection margins. Only in animals in which a vessel-opening brain lesion had been performed (cortical ablation) was this type of surgically induced enhancement seen (arrows). Postcontrast T1-weighted images (from left to right: 5, 10, and 15 minutes after administration of the contrast agent) (500/20/4).

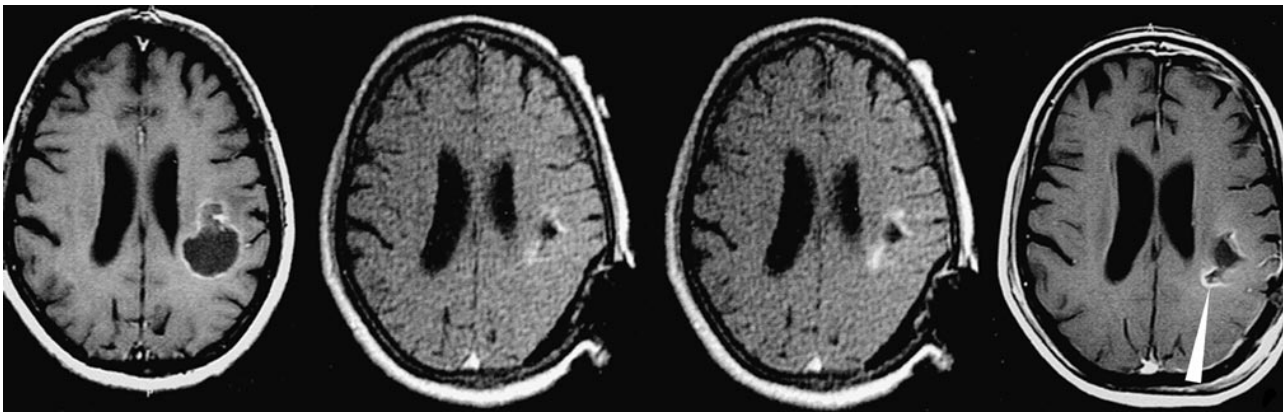


FIG 7. Surgically induced enhancement: problematic case. Preoperative MR (left) (674/20/2) shows a ring-enhancing lesion. Intraoperative T1-weighted images (middle images, 5 and 20 minutes postcontrast) (532/15/3) show enhancement at the resection margin with some time dependence. A confident differential diagnosis of this enhancement (tumor or not?) could not be made, and the surgery was terminated. Early postoperative MR image (right) (674/20/2) shows possible residual tumor (arrowhead).

compared with the patients of Kahn et al (16) and Anzai et al (17) who aimed at tissue necroses of considerable volume.

As noted above, immediate intraparenchymal enhancement necessitates careful comparison

with preoperative MR examinations to avoid confusion with residual, enhancing tumor. Figure 8 shows one of the first cases in our study in which we did not adhere to that (then not yet established) rule.

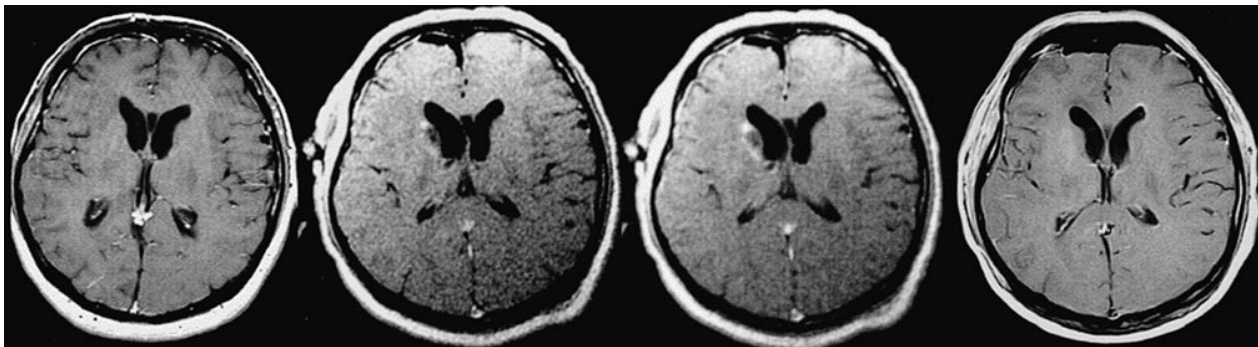


FIG 8. Surgically induced enhancement: problematic case. This was one of the first patients in whom an intraoperative MR examination was performed. The tumor is above the level of these T1-weighted images. Preoperative MR image (left) (674/20/2) does not show enhancement in the head of the right caudate nucleus. Problems with hemostasis necessitated repeated electrocoagulations in this region. Intraoperative MR images (middle images, 5 and 20 minutes postcontrast) (532/15/3) partially show solid-appearing contrast enhancement of the head of the caudate nucleus with almost no time dependence during the observed time interval. A small biopsy was taken from this region, which did not show residual tumor histologically. Surgery was terminated. Early postoperative MR imaging (674/20/2) did not show persistent enhancement of the head of the caudate nucleus. The intraoperative enhancement probably represented transient blood-brain barrier disruption.

Overview over the different types of surgically induced contrast enhancement

Type of Surgically Induced Enhancement	Frequency (%)	Localization/ Configuration	Time Dependence in Intraoperative MR	Early Postoperative MR	Hypothesized Pathomechanism	Potential for Misdiagnosis of Residual Tumor
Meningeal	100	Leptomeningeal/dural	None	Equal or increased	Meningeal reaction/ irritation	Practically none
Increased enhancement of choroid plexus	13.7	Choroid plexus	None	Equal or increased	Choroid plexus reaction/ irritation	Practically none
Delayed enhancement at resection margin	81	Resection margin/linear	Marked	Reduced or absent	Leakage of contrast media out of surgically opened vessels	Moderate
Immediate intraparenchymal enhancement	9.8	Intraparenchymal "Solid"/Nodular	Little–none	Reduced or absent	Transient BBB disruption	High

Table 1 summarizes the frequency, characteristic features, hypothesized pathomechanisms, and the confounding potential of the different forms of surgically induced contrast enhancement to be mistaken for residual, contrast-enhancing tumor. Using these findings, we were able to distinguish confidently surgically induced enhancement from residual, contrast-enhancing tumor in 90.2% of the cases.

Surgically induced contrast enhancement was the main source of trouble in the interpretation of intraoperative contrast-enhanced MR examinations. It is possible that new developments in MR contrast agents, such as iron oxide microparticles that are phagocytosed by high-grade gliomas (18, 19), will render the intraoperative administration of a paramagnetic contrast agent unnecessary and thus abolish the whole problem of surgically induced contrast enhancement.

MR imaging is being used increasingly as an interventional imaging technique, and it is foreseeable that many groups will use MR imaging to assess the radicality of brain tumor surgery. Nevertheless, one has to be aware of the different forms of surgically induced contrast enhancement that exist and that there is danger of confusing at least some of them with residual, enhancing tumor.

Acknowledgment

We thank the radiology technologists, Bettina Bittmann, Tina Kerby, Andreas Krupp, Cora Sauer, and Sabine Unterwaldt, for collaboration.

References

- Hammoud MA, Ligon BL, el Souki R, et al. Use of intraoperative ultrasound for localizing tumors and determining the extent of resection. A comparative study with magnetic resonance imaging. *J Neurosurg* 1996;84:737–741
- Lunsford LD, Parrish R, Albright L. Intraoperative imaging with a therapeutic computed tomographic scanner. *Neurosurgery* 1984;15:559–561
- Lunsford LD, Kondziolka D, Bissonette DJ. Intraoperative imaging of the brain. *Stereotact Funct Neurosurg* 1996;66:58–64
- Knauth M, Wirtz CR, Tronnier VM, et al. Intraoperative magnetic resonance tomography for control of extent of neurosurgical operations. *Radiologe* 1998;38:218–224
- Black PMcL, Moriarty T, Alexander E, et al. Development and implementation of intraoperative magnetic resonance imaging and its neurosurgical applications. *Neurosurgery* 1997;41:831–842
- Tronnier VM, Wirtz CR, Knauth M, et al. Intraoperative diagnostic and interventional magnetic resonance imaging in neurosurgery. *Neurosurgery* 1997;40:891–900
- Wirtz CR, Bonsanto MM, Knauth M, et al. Intraoperative magnetic resonance imaging to update interactive navigation in neurosurgery. Method and preliminary experience. *Comput Aided Surg* 1997;2:172–179
- Steiner P, Schoenenberger AW, Penner EA, et al. Interactive stereotaxic interventions in superconducting, open 0.5-Tesla MRI tomography. *Rofo Fortschr Geb Rontgenstr Neuen Bildgeb Verf* 1996;165:276–280
- Forsting M, Albert FK, Kunze S, et al. Extirpation of glioblastomas. MR and CT follow-up of residual tumor and regrowth patterns. *AJNR Am J Neuroradiol* 1993;14:77–87
- Burke JW, Podrasky AE, Bradley WG. Meninges. Benign postoperative enhancement on MR images. *Radiology* 1990;174:99–102
- Cairncross JG, Pexman JH, Rathbone MP, DelMaestro RF. Postoperative contrast enhancement in patients with brain tumor. *Ann Neurol* 1985;17:570–572
- Dickman CA, Rekeate HL, Bird CR, Drayer BP, Medina M. Unenhanced and gadolinium-DTPA-enhanced MR imaging in postoperative evaluation in pediatric brain tumors. *J Neurosurg* 1989;71:49–53
- Elster AD, DiPersio DA. Cranial postoperative site. Assessment with contrast-enhanced MR imaging. *Radiology* 1990;174:93–98
- Henegar MM, Moran CJ, Silbergeld DL. Early postoperative magnetic resonance imaging following nonneoplastic cortical resection. *J Neurosurg* 1996;84:174–179
- Jeffries BF, Kishore PR, Singh KS, Ghatak NR, Krempa J. Contrast enhancement in the postoperative brain. *Radiology* 1981; 139:409–413
- Kahn T, Bettag M, Harth T, et al. Laserinduzierte interstitielle Thermotherapie von zerebralen Tumoren unter kernspintomographischer Kontrolle. *Radiologe* 1996;36:713–721
- Anzai Y, Lufkin R, DeSalles A, et al. Preliminary experience with MR-guided thermal ablation of brain tumors. *AJNR Am J Neuroradiol* 1995;16:39–48
- Zimmer C, Wright SC Jr, Engelhardt RT, et al. Tumor cell endocytosis imaging facilitates delineation of the glioma-brain interface. *Exp Neurol* 1997;143:61–69
- Zimmer C, Weissleder R, Poss K, et al. MR imaging of phagocytosis in experimental gliomas. *Radiology* 1995;197:533–538