

Generic Contrast Agents

Our portfolio is growing to serve you better. Now you have a *choice*.



FRESENIUS
KABI

[VIEW CATALOG](#)

AJNR

The Substantia Nigra is also Involved in Japanese Encephalitis

J Kalita and U K Misra

AJNR Am J Neuroradiol 2000, 21 (10) 1978-1979

<http://www.ajnr.org/content/21/10/1978>

This information is current as
of May 6, 2025.

Moyamoya Syndrome in Cocaine-dependent Patients

I enjoyed Storen et al's article regarding two cocaine-dependent patients who manifested angiographic changes that suggested moyamoya syndrome (1). We published a similar case in the on-line journal, *Neurosurgical Focus*, the internet journal of the *Journal of Neurosurgery* (2). Our patient was a 30-year-old, right-handed, Caucasian woman who had heavy dependency on intranasal cocaine from the ages of 16–27. She presented with a long history of headache, which was worsening in frequency and intensity, and with dysphasia and right-sided weakness. CT and MR studies showed multiple, small cerebral infarctions of different ages, and cerebral arteriography revealed evidence of advanced-stage moyamoya changes, with virtual occlusion of supraclinoid carotid arteries bilaterally. Despite aspirin treatment, the patient continued to have symptoms, and she underwent eventual bilateral pial synangiomas to enhance collateralization to each hemisphere. The postoperative arteriograms indicated excellent collateralization bilaterally, and the patient has remained neurologically stable without further events for the past 9 years. Pre- and postoperative arteriograms are available on the on-line publication (www.neurosurgery.org/focus/november98/5-5-7.html). We also thought that the network of collateral vessels beyond the bilateral carotid occlusive process implied an insidious progressive process rather than an acute event, and felt that chronic vasoconstriction was the most likely explanation for the development of the angiographic and clinical phenomena.

R. Michael Scott
The Children's Hospital
Boston, MA

References

1. Storen EC, Wijdicks EFM, Crumb A, Schultz G. **Moyamoya-like vasculopathy from cocaine dependency.** *AJNR Am J Neuroradiol* 2000;21:1008–1010
2. Schwartz MD, Scott RM. **Moyamoya syndrome associated with cocaine abuse.** *Neurosurg Focus* 1998;5: Article 7

Anaphylaxis after Steroid and Local Anesthetic Injections

Injections of steroids and local anesthetics into paraspinal locations such as facet joints, neural foramina, and the epidural space are becoming widely used among neuroradiologists as a means of pain management. These procedures are considered to have extremely low complication rates, with bleeding and infection commonly mentioned, but rarely

seen in practice. Many practitioners may be unaware that allergic reactions, including anaphylaxis, can occur when injecting even small amounts of local anesthetics and steroids.

I have had two patients who experienced atopic reactions following paraspinal injections, including one who went into anaphylactic shock. The first patient was a 62-year-old obese woman with a history of diabetes and a small, prior myocardial infarction who presented for bilateral, 3-level, facet-joint injections (an epidural injection of Kenalog 8 days earlier had no effect). During the fourth injection of Kenalog and bupivacaine, the patient complained of mild difficulty breathing; she believed it was due to her prone position. She elected to continue the treatment regimen, and the injections were completed. At that time she stated she was having more difficulty breathing, and rapidly became cyanotic and unresponsive over the next 10 seconds. When the patient was moved into a supine position, it was noted that her tongue was protruding, her skin was pale, and her pulse was weak. Auscultation of her thorax revealed very little air movement during inspiration, with marked wheezing. Three doses of intravenous epinephrine were administered, and the patient made a dramatic improvement. She suffered no long-term sequelae and was released the next day. The second patient had diffuse urticaria and pruritis that began approximately 5 minutes after a selective nerve root block with Kenalog and bupivacaine. She was successfully treated with intravenous Benadryl.

There have been reports of anaphylaxis caused by many types of local anesthetics and steroids (1, 2); however, some readers may be unaware of this potential complication to spinal injections. Although an allergic reaction to steroids, which are used to treat such reactions, may seem counterintuitive, some patients have a reaction to the carboxymethylcellulose suspension found in Kenalog (it is also a major component of lidocaine jelly) (3).

My patients all have heparin locks placed prior to the examination, which allowed rapid intravenous epinephrine injection in the first case. Although this may not be feasible or desirable in some centers, it improves safety and is also useful in vasovagal situations. It is important that anyone performing these injections is aware of the possibility of anaphylaxis, and has the equipment and medication ready for such an occurrence.

Andrew L. Wagner, M.D.
Rockingham Memorial Hospital
Harrisonburg, VA

References

1. Murrieta-Aguttes M, Michelin V, Leynadier F, et al. **Systemic allergic reactions to corticosteroids.** *J Asthma* 1991;28:329–339

2. Hopper JM, Carter SR. Anaphylaxis after intra-articular injection of bupivacaine and methylprednisolone. *J Bone Joint Surg Br* 1993;75:505-506
3. Patterson DL, Yunginger JW, Dunn WF, Jones RT, Hunt LW. Anaphylaxis induced by the carboxymethylcellulose component of injectable triamcinolone acetonide suspension. *Ann Allergy Asthma Immunol* 1995;74:163-166

The Substantia Nigra is also Involved in Japanese Encephalitis

We read with interest the article by Cerna et al published in the *AJNR* (1), in which they reported that isolated lesions of the substantia nigra suggest the possibility of St Louis encephalitis (SLE). It was also noted that there had been no previous reports of focal signal changes in the substantia nigra for any infectious, metabolic, or degenerative diseases of the brain.

We would like to bring to your attention that the substantia nigra is also involved in Japanese encephalitis (JE). In our study on MR changes in JE, the midbrain was reported to be involved in three of seven patients, and Figure 3 in that report showed involvement of the substantia nigra (2). In a more recent report on 42 patients with JE, the midbrain was involved in 18 of 31 patients in whom MR imaging was performed (3). It is interesting to note that two of these patients had isolated midbrain involvement (Fig 1). It should be realized that many published reports may include substantia nigra involvement under the heading of midbrain or brain stem lesion. The substantia nigra was reported to be involved in JE as early as 1989 (4). It should be understood, however, that JE is also commonly associated with thalamic, basal ganglia, cerebral cortex, and cerebellar involvement.

Cerna et al (1) referred to several autopsy studies of patients with SLE that suggested "selectively severe involvement of the substantia nigra". In another autopsy study employing quantitative histologic and immunofluorescent techniques on patients who died in the 1975 SLE epidemic in Illinois, it was found that not only was there involvement of the substantia nigra and spinal gray matter, but other areas, including the thalamus, inferior olivary nucleus, brain stem, and to a lesser extent the cerebellar cortex and pons, were also affected (5). A number of authors have reported widespread involvement of the nervous system in SLE, with involvement of both the thalamus and substantia nigra to a similar degree (6). The thalamus, basal ganglia, substantia nigra, red nucleus, pons, cerebral gray matter, and cerebellum have also been reported to be involved in JE (7). The involvement of these areas has been observed in various MR imaging studies as well (2-4).

The patients reported by Cerna et al had a mild clinical picture, and it is not surprising that MR changes manifested in only two of seven patients. The diagnosis of SLE in cases with isolated in-

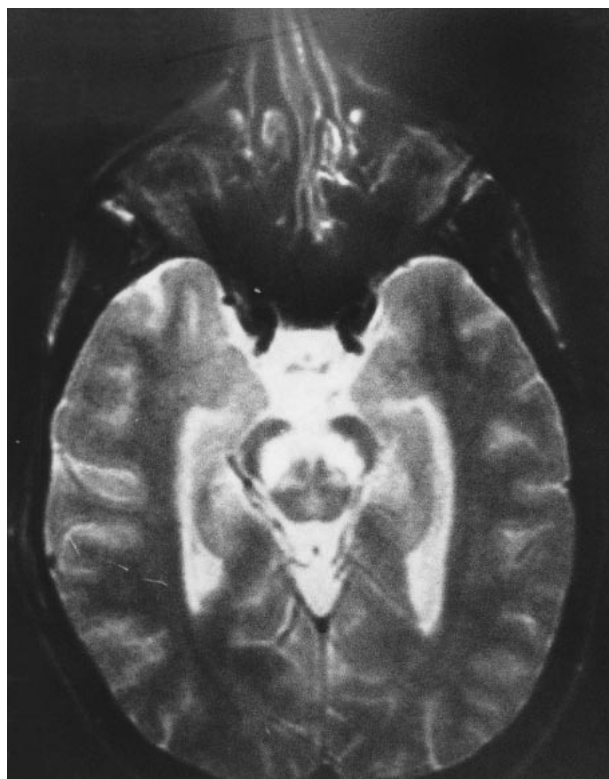


FIG. Cranial, axial, T₂-weighted MR image shows hyperintense signal changes in the substantia nigra in a patient with JE.

volvement of the substantia nigra in a severely ill, tremulous patient seems rather premature, because the clinical and pathologic findings of SLE are indistinguishable from other arbovirus infections of the CNS (8). Further studies are needed on larger and more severely affected patients with SLE before drawing definite conclusions regarding the diagnostic specificity of substantia nigra involvement. The radiologic findings should be interpreted in light of the endemic nature of the disease, clinical context, and virologic studies.

J Kalita
U K Misra

Sanjay Gandhi Post Graduate Institute of Medical
Sciences
Lucknow, India

References

1. Cerna F, Mehrad B, Luby JP, Burns D, Fleckenstein JL. St Louis encephalitis and the substantia nigra: MR imaging evaluation. *AJNR Am J Neuroradiol* 1999;20:1281-1283
2. Kumar S, Misra UK, Kalita J, Salwani V, Gupta RK, Gujral R. MRI in Japanese encephalitis. *Neuroradiol* 1997;39:150-154
3. Kalita J, Misra UK. Comparison of CT scan and MRI findings in the diagnosis of Japanese encephalitis. *J Neurol Sci* 1999; (in press)
4. Shoji H, Hiraki Y, Kuwasaki N, Toyomasu T, Kaji M, Okudera T. Japanese encephalitis in the Kurume region of Japan: CT and MRI findings. *J Neurol* 1989;236:255-259
5. Reyes MG, Gardner JJ, Poland JD, Monath TP. St Louis encephalitis-quantitative histologic and immunofluorescent studies. *Arch Neurol* 1981;38:329-334

6. Haymaker W. **Mosquitoborne encephalitides.**In: van Bogaert L ed. *Encephalitides*. New York: Elsevier;196138-56
7. Zimmermann HM. **Pathology of Japanese encephalitis.** *Am J Pathol* 1946;22:965-999
8. Whitley RJ. **Arthropod borne encephalitides.**In: Scheld WM, Whitley RJ, Durack DT, eds. *Infections of nervous system*. Philadelphia: Lippincott Raven.1997155

Reply to LTE 1691-99

In our August 1999 article in the *AJNR*, we reported that in two of seven patients with St. Louis encephalitis (SLE), T2-weighted images showed hyperintensity in the substantia nigra (1). In one of the patients, the hyperintensity was asymmetrical. In both patients, the infusion of contrast material did not cause abnormal enhancement. There were no other MR alterations in these patients. We searched the literature to find instances of such selective involvement of the substantia nigra and could find none. Our bibliography included four papers on Japanese encephalitis (JE), three by Shoji et al and one by Misra et al. Although there was evidence of involvement of the substantia nigra in an occasional patient in these series, it always occurred in the setting of diffuse, widespread, radiologic evidence of injury. A 1997 article presenting seven cases of JE by Misra et al described "non-specific signal change" in two cases of midbrain involvement, and an image of a third case exemplified the midbrain abnormality. One midbrain lesion was hemorrhagic, as were thalamic lesions in five of the seven cases (2).

That JE can cause selective predominant involvement of the substantia nigra, however, is evidenced in an article that appeared in *Neurology* in November, 1999 (3). Investigators in Lucknow, India studied 52 patients with JE over a 6-year period, and found five patients with predominant involvement of the substantia nigra. They wrote that "predominant involvement of the substantia nigra in JE has not been previously reported." Because Kalita and Misra are from the same institute in Lucknow, we do not know whether the image in their letter-to-the-editor comes from one of these cases, from their similar article in press (4), or if it represents a different patient. The clinical manifestations of illness in these five patients closely resemble those of the two patients reported in our article, although overall it is generally difficult to compare patients with these diseases because of their variable features.

An underlying assumption in the letter by Kalita and Misra is that because SLE is caused by an arbovirus, and particularly a flavivirus, it should cause disease closely resembling JE. Their implication is that if more severely ill patients with SLE had been studied, the same radiologic findings should have been seen as have been reported in JE. In view of this implication, it may be worth reviewing the differences between SLE and JE. The patients studied in Dallas in 1995 were similar to those seen in two other Dallas SLE epidemics

in 1966 and 1976. The overall fatality rate in these three epidemics was 10%; in JE, it is approximately 25%. In 1966, of 49 patients followed prospectively, 67% had tremors; in JE, the percent is less (5). Neurologic sequelae in survivors of SLE are infrequent, whereas in JE they are common. Thalamic hemorrhages are never seen in SLE; they are common in JE. In SLE there is diffuse encephalitis, but a paucity of findings radiologically. The radiologic manifestations in the two patients we reported were seen only in the substantia nigra. We reported another case in which the CT scan showed two large areas of decreased attenuation in the brain stem, which was cited in our *AJNR* article (1). The critical study is that of Reyes et al, in which they measured quantitatively the pathologic changes in the brains of patients with SLE, and which duplicated earlier qualitative studies (6-8). They found that, excluding midbrain measurements, the substantia nigra had at least eight times the quantity of brain involved than did the next most severely affected segment of the CNS (spinal gray matter).

We have also become aware of a case report of a 33-year-old woman from Singapore with encephalitis lethargica, who had bilateral substantia nigra changes on MR images. The authors made the diagnosis on clinical grounds, reported the case in *Neurology* in November 1999, and stated that this is "the first case of a patient showing bilateral substantia nigra changes on MRI" (9).

Since tremors can be seen in adults with Western equine encephalitis, we cannot exclude involvement of the substantia nigra in that disease. In view of the recent report in *Neurology* concerning JE, the letter by Kalita and Misra, and the rarity of encephalitis lethargica, our concluding statement should be changed to: Severely ill and tremulous patients presenting with encephalitis in North American cities, who show isolated T2-weighted hyperintensity of the substantia nigra, should be examined for SLE.

It is important to note that there are missing references in the reference list of our original article (1), and that some of the references are not numbered correctly. Revisions were made in order to bring the total number of references down to eight, but were not incorporated into the final article. Reference 5 (of this reply) was included in the text citations of our original article, but was not included in the reference list. References 3-6 in the reference list of our article were cited as 5-8 in the text. References cited as 10-12 in the text were numbered 7 and 8 in the reference list (one reference was deleted), and correspond to references 6, 7, and 8 of this reply.

James L. Fleckenstein
The University of Texas
Southwestern Medical Center at Dallas
Dallas, Texas

References

1. Cerna F, Mehrad B, Luby IP, Bums D, Fleckenstein JL. **St. Louis encephalitis and the substantia nigra: MR imaging evaluation.** *AJNR Am J Neuroradiol* 1999;20:1281–1283
2. Kumar S, Msra UK, Kalita J, Salwani V, Gupta RK, Gujral R. **MRI in Japanese encephalitis.** *Neuroradiology* 1997;39:180–184
3. Pradhan S, Pandey N, Shashank S, Gupta RK, Mathur A. **Parkinsonism due to predominant involvement of substantia nigra in Japanese encephalitis.** *Neurology* 1999;53:1781–1786
4. Kalita J, Misra UK. **Comparison of CT scan and MRI findings in the diagnosis of Japanese encephalitis.** *J Neurol Sci* 1999; (in press).
5. Southern P Jr., Smith JW, Luby JP, Barnett JA, Sanford JP. **Clinical and laboratory features of epidemic St. Louis encephalitis.** *Ann Int Med* 1969;71:681–689
6. Reyes MG, Gardner JJ, Poland JD, Monath TP. **St. Louis encephalitis. Quantitative histologic and immunofluorescent studies.** *Arch Neurol* 1981;38:329–334.
7. Weil A. **Histopathology of the central nervous system in epidemic encephalitis (St. Louis epidemic).** *Arch Neurol Psychiatry* 1934;31:1139–1152
8. Suzuki M, Phillips CA. **St. Louis encephalitis: a histopathologic study of fatal cases from the Houston epidemic in 1964.** *Arch Path* 1966;81:47–54
9. Kun LN, Yian SY, Haur LS, Tjia H. **Bilateral substantia nigra changes on NM in a patient with encephalitis lethargica.** *Neurology* 1999;53:1860–1862