Are your MRI contrast agents cost-effective?
Learn more about generic Gadolinium-Based Contrast Agents.
FRESENIUS KABI
caring for life

AJNR

Cortical/Subcortical Disease Burden and Cognitive Impairment in Patients with Multiple Sclerosis

Marco Rovaris, Massimo Filippi, Luca Minicucci, Giuseppe Iannucci, Giuseppe Santuccio, Francesca Possa and and Giancarlo Comi

This information is current as of May 16, 2024.

AJNR Am J Neuroradiol 2000, 21 (2) 402-408
http://www.ajnr.org/content/21/2/402

AJNR Am J Neuroradiol 21:402–408, February 2000

Cortical/Subcortical Disease Burden and Cognitive Impairment in Patients with Multiple Sclerosis

Marco Rovaris, Massimo Filippi, Luca Minicucci, Giuseppe Iannucci, Giuseppe Santuccio, Francesca Possa, and Giancarlo Comi

BACKGROUND AND PURPOSE: **We assessed whether the extent of macro- and microscopic disease in the cortical and subcortical brain tissue, as revealed by MR and magnetization transfer (MT) imaging, correlates with cognitive dysfunction in patients with multiple sclerosis (MS).**

METHODS: **Dual-echo rapid acquisition with relaxation enhancement (RARE), fast fluid-attenuated inversion recovery (fast-FLAIR), T1-weighted, and MT MR images of the brain were obtained from 16 MS patients with cognitive impairment and from six without. Impaired and unimpaired patients were similar across demographic and other disease-related variables. Total and cortical/subcortical lesion loads were assessed using RARE, fast-FLAIR, and T1-weighted sequences. In each patient, cortical/subcortical disease was also assessed by means of MT ratio (MTR) histographic analysis.**

RESULTS: **All the impaired patients had multiple hyperintense lesions in the cortical/subcortical regions on both RARE and fast-FLAIR images; two unimpaired patients had such lesions on the RARE images and four had them on the fast-FLAIR images. Total and cortical/subcortical RARE/fast-FLAIR hyperintense and T1 hypointense lesion loads were significantly greater in the group of cognitively impaired patients. Patients with cognitive deficits also had significantly lower MTR histographic values for all the variables. A multivariate regression model showed that average cortical/subcortical brain MTR was the only factor that was significantly associated with cognitive impairment.**

CONCLUSION: **The extent and severity of MS disease in the cortical and subcortical regions significantly influence the cognitive functions of MS patients. MTR histographic findings suggest that subtle changes undetectable by conventional imaging are also important in determining MS cognitive decline.**

Cognitive deficits are frequently detected in patients with multiple sclerosis (MS) (1). Recent memory, sustained attention, verbal fluency, visuospatial perception, problem solving, and abstract reasoning are typically involved, whereas long-term memory and symbolic functions are usually spared (1). This pattern of subcortical dementia might be explained by the disruption of neural connections among cortical associative areas and between cortical and subcortical structures, as a consequence of a progressive accumulation of MS lesions in the cerebral white matter (1, 2).

Soon after brain MR imaging was first applied in the assessment of patients with MS (3), it became evident that the severity of cognitive impairment correlated well with the load of lesions on conventional T2-weighted images (4–6). In addition, patterns of frontal lobe cognitive decline were found to be related to the corresponding lobar lesion loads (5, 6), although this has not been confirmed by more recent studies (7, 8). Several studies (2, 9–11) also reported a close relationship between neuropsychological deficits and load of MS lesions in the cortical/subcortical regions. A study by Miki et al (9) found that the presence and extent of lesions in the U fibers may be the most relevant contributor to the impairment of memory and executive functions in patients with MS.

Pathologic studies (12, 13) have shown that small cortical and subcortical lesions are common in MS, although they may be under-represented on T2-

Received June 23, 1999; accepted after revision August 23.

From the Neuroimaging Research Unit (M.R., M.F., L.M., G.I.) and the Unit for Clinical Trials (G.S., F.P., G.C.), Department of Neuroscience, Scientific Institute Ospedale San Raffaele, Milan, Italy.

Supported by the Istituto Superiore di Sanità (grant no. 96/J/T44).

Address reprint requests to Dr. Massimo Filippi, Neuroimaging Research Unit, Department of Neuroscience, Scientific Institute Ospedale San Raffaele, Via Olgettina 60, 20132 Milan, Italy.

© American Society of Neuroradiology

weighted MR images (14). On the one hand, this might be due to the longer relaxation times of gray matter lesions, which result in poor contrast resolution between these lesions and the surrounding normal-appearing brain tissue. On the other hand, partial volume effects from CSF also reduce the ability of conventional T2-weighted imaging to resolve cortical MS lesions. The use of a fast fluid-attenuated inversion-recovery (fast-FLAIR) sequence, which is characterized by CSF signal suppression and similar signal intensities for gray and white matter, may, therefore, improve MS lesion detection in the cortex and in the white matter abutting it (15, 16).

Conventional T2-weighted MR imaging has other major limitations, including a lack of sensitivity for assessing microscopic MS damage in the normal-appearing brain tissue (17, 18) and a lack of specificity for the various pathologic substrates underlying macroscopic lesions, which range from edema and inflammation to severe demyelination and axonal loss (19). Magnetization transfer (MT) imaging promises to overcome these limitations. First, MT imaging provides a quantitative measure (ie, magnetization transfer ratio, [MTR]) that correlates well with the degree of tissue disruption within individual MS lesions (20). Second, MTR histographic analysis (21) provides a complete assessment of macro- and microscopic lesion load in MS, and it has been found that histographically derived measures of brain MTR differ among the various clinical forms of MS (22) and are correlated with clinical disability (22, 23).

In this study, we assessed whether the extent of macro- and microscopic disease in the cortical and subcortical regions is important for determining cognitive dysfunction in patients with MS. To this purpose, we assessed the load of cortical/subcortical MS lesions on both T2-weighted and fast-FLAIR MR images from two groups of MS patients with and without cognitive impairment. In addition, we obtained and compared MTR histograms from brain slabs, including only the cortical/subcortical tissue.

Methods

Patients

Twenty-two patients (11 men and 11 women) with clinically definite MS (24), referred consecutively to our MS clinic for routine follow-up, underwent neuropsychological and MR evaluation for the present study. At the time MR imaging was performed, patients were not in clinical relapse, nor had they been treated with steroids or psychoactive drugs in the 3 months preceding the study. None of the patients were affected by visual deficits or upper limb impairment that could interfere with their performance on the neuropsychological tests, and none had a history of drug or alcohol abuse or depression, as ascertained from clinical interviews prior to study entry. All patients gave informed consent, and the study was approved by the local ethical committee.

Neuropsychological Tests

Neuropsychological tests exploring the executive functions (Weigl Test, Dual Task Test, Wisconsin Card Sorting Test [WCST], Stroop Color/Word Interference Test [Stroop Test], Hanoi Towers Test, and Verbal Fluency Test) and verbal and spatial memory (Digit Span Test, Short Tale Test, Corsi Span, and Supra-Span Test) were always obtained within 48 hours of the acquisition of MR images. These tests are routinely used in the assessment of cognitive impairment in MS patients (25) and have been extensively described elsewhere (8, 26–32). Patients who had normal results on all tests exploring the two cognitive domains (ie, executive and memory functions) were classified as cognitively unimpaired, whereas patients with abnormal results on two or more tests were classified as cognitively impaired. For each patient, the results from all neuropsychological tests were then scored by using a standardized method based on a comparison with the percentile distribution of values from healthy control subjects (33). These scores ranged from 0 to 4, where grade 0 means a very poor performance and grade 4 means a normal performance. Individual test scores were then summed to provide a composite cognitive score for each patient.

Image Acquisition

On a 1.5-T scanner, and in the same session, each patient underwent dual-echo rapid acquisition with relaxation enhancement (RARE) MR imaging of the brain with parameters of 3300/16,98 (TR/TE) and an echo train length (ETL) of 5, and fast-FLAIR imaging with parameters of 9500/119, an inversion time of 2200, and an ETL of 7. Twenty-four axial 5-mm-thick contiguous slices were obtained, with a rectangular 188 $\times$ 250-mm field of view and a 194 $\times$ 256 image matrix, thus obtaining approximately a 1 $\times$ 1-mm in-plane resolution. MT imaging and T1-weighted magnetization-prepared rapid acquisition gradient echo (MP-RAGE) images were also obtained in the same session. For MT imaging, 2D gradient-echo images with parameters of 600/12 and a flip angle of 20° were obtained with and without a saturation pulse. The saturation pulse was an off-resonance gaussian radio frequency pulse centered 1.5 kHz below the water frequency, with a duration of 16.4 milliseconds, a bandwidth of 250 Hz, and a power intensity of 3.4×10^{-6} T. The same acquisition parameters as for the RARE and fast-FLAIR images were used for MT images, except for the number of slices, which was 20. The set of slices for MT imaging was positioned so as to obtain the same central 20 slices as obtained in the other acquisition schemes. From the two sets of images, without (Mo) and with (Ms) saturation pulse, and after their coregistration (see next paragraph), quantitative MTR images were derived pixel-by-pixel according to the following equation: $MTR = (Mo - Ms)/Mo \times 100$, where Mo is the mean signal intensity for a given pixel without the saturation pulse and Ms is the mean signal intensity for the same pixel when the saturation pulse is applied. Signal intensities on the calculated images represented the MTR value. For MP-RAGE imaging with parameters of 10/4, an inversion time of 700, a flip angle of 10°, and one acquisition, a 3D sagittal slab (194 $\times$ 256 $\times$ 160 image matrix, 250-mm field of view) covering the entire brain was acquired. The original data were then reformatted to obtain 24 axial contiguous 5-mm-thick slices with the same orientation and offsets as the corresponding RARE slices. Patients were positioned in the scanner in accordance with published guidelines for MS studies (34).

Image Analysis

MS lesions were first outlined on the RARE proton density–weighted, fast-FLAIR, and MP-RAGE T1-weighted hard copies by two experienced observers, unaware of the patients' clinical status or cognitive test results. T2-weighted images were always used to increase confidence in lesion detection. For T1-weighted MP-RAGE images, a conservative approach was used. Only areas with a signal intensity between that of CSF and gray matter and with corresponding abnormalities on the dual-echo RARE or fast-FLAIR images were considered to be hypointense lesions. On fast-FLAIR, proton density–,

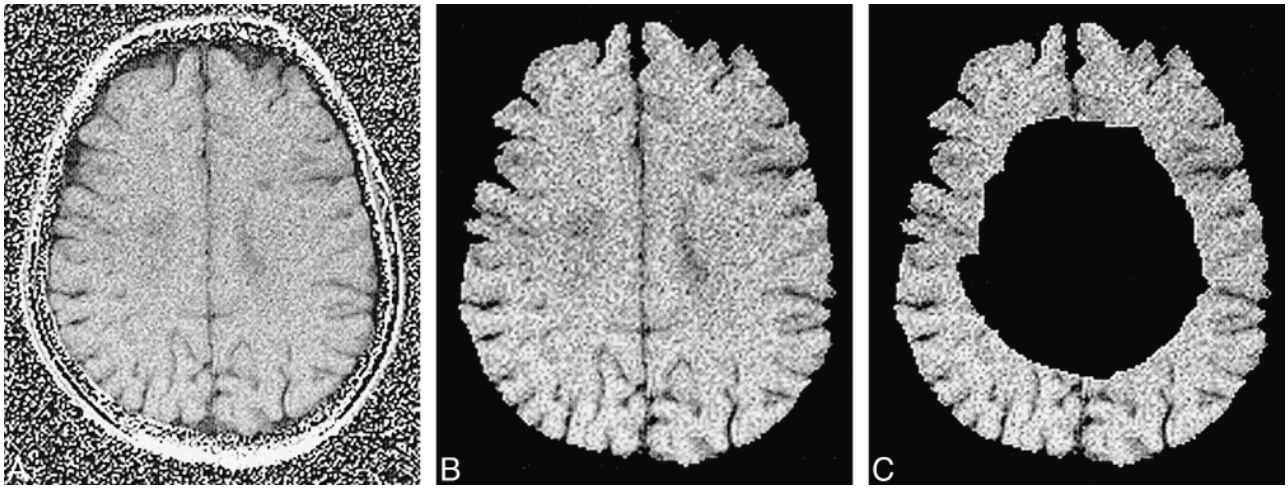

FIG 1. Axial quantitative MTR image of the brain in a patient with MS, obtained at level of the roof of the lateral ventricles. *A* and *B,* The slice is shown before (*A*) and after (*B*) manual image segmentation, which precedes any MTR histographic analysis to exclude all extracranial tissues.

C, The same slice is shown after postprocessing (see Methods); only the cortical/subcortical brain tissue is left to enter the MTR histographic analysis.

and T1-weighted images, we carefully assessed the presence of cortical/subcortical MS lesions, which were identified as a separate group. This group included both U fiber lesions and any other lesion located in the cortex or in the white matter abutting it. Consistently, the image review always began at the top of the brain, and those lesions adjacent to the cortical undersurface and extending to the periventricular regions were considered part of the cortical/subcortical lesion subgroup.

The lesion loads in the whole brain (total lesion load) and in the cortical/subcortical regions were measured by a trained technician who was unaware of the patients' clinical status or cognitive test results. A highly reproducible local thresholding technique (35) was used to segment the lesions on computer-displayed images, keeping the marked hard copies as references. Lesions were delineated as regions of interest (ROIs), and lesion volume was calculated for each sequence by multiplying the total ROI by the slice thickness.

From quantitative MTR images, we derived MTR histograms for the cortical/subcortical regions. To obtain these histograms, we followed the image postprocessing method extensively described by van Buchem et al (21) and Rovaris et al (8). After a preliminary manual image segmentation to exclude all extracranial tissue (eg, skull, orbit, etc), we selected 10 contiguous slices with the most caudal at the level of the velum interpositum cerebri. Histographic analysis of cortical/subcortical brain tissue was limited to this slab of 10 slices for the following reasons: a) it included most of the subcortical white matter, b) it was likely to prove consistent in longitudinal studies, as it was based on reproducible neuroanatomic landmarks, and c) postprocessing of more caudal slices would require significantly greater operator intervention, thus potentially creating measurement variability at test-retest. To extract the cortical/subcortical brain tissue from these images, we used a semiautomated, in-house program, which operates in the Matlab 5 (The Math Works Inc; Natrick, MA) environment and is based on the morphological operators of erosion and dilatation (36). The key mechanism under the erosion and dilatation paradigm is the local comparison of a shape, called a structural element, with the examined object (ie, the brain in the present case) that will be transformed. The erosion operator works as follows: if, when positioned at a given point, the structural element is included in the object, then this point will appear in the result of the transformation; otherwise it will not. The dilatation operator works as follows: when the structural element is positioned at a given point and it touches the object, then this point will appear in the result of the transformation; otherwise it will not. The input to the program was represented by the slab of segmented slices and by two numerical parameters (ie, the dimensions of the structural elements for erosion and dilatation). Employing the morphological functions, we then used a binary representation of the images to create a mask containing the brain parenchyma other than the cortical/subcortical regions. This mask was then subtracted from the corresponding slices to obtain a quantitative MTR image. The values for the two input numerical parameters were determined by a single observer, who was unaware of the patients' clinical status or cognitive test results; these values were the same for all patients (Fig 1). To reduce partial volume averaging from CSF, we excluded from the analysis all the pixels with intensities lower than 10%. Admittedly, this might result in the exclusion of pixels corresponding to MS lesions with severe white matter disruption; however, as lesion MTR values obtained in our laboratory were always higher than 15%, we believe that the use of this cut-off value excluded very few, if any, such pixels from the analysis. To correct for intrasubject differences in brain volume, each histogram was normalized by dividing it by the total number of pixels included. For each histogram, we analyzed the height and location of the histographic peak with respect to the *x*-axis (ie, the MTR value most represented), the average MTR value, and the MTR values corresponding to the 25th, 50th, and 75th percentiles of the histogram (ie, MTR_{25}, MTR_{50}, and MTR_{75}), which indicate the MTR value at which the integral of the histogram is 25%, 50%, and 75% of the total, respectively. Because these values are representative of the brain tissue as a whole, they include both MS lesions and normal-appearing white and gray matter.

Statistical Analysis

Differences between cognitively impaired and unimpaired patients were evaluated using Student's *t*-test for nonpaired data when the data were distributed normally, and the Mann-Whitney test when the data were not normally distributed. Univariate correlations between the composite cognitive scores and cortical/subcortical MTR histographic metrics were assessed using Spearman's rank correlation coefficient (SRCC) test. To assess the factors independently associated with cognitive impairment, we ran a multivariate logistic regression model, entering the total and cortical/subcortical lesion loads

TABLE 1: Main demographic and clinical data from MS patients without and with cognitive impairment

	Unimpaired Patients	Impaired Patients	*P* Value
Mean (SD) age (yr)	37.7 (8.6)	37.6 (7.2)	N.S.
Mean (SD) level of education (yr)	11.6 (3.8)	10.9 (3.8)	N.S.
Median (range) duration of disease (yr)	14 (8–20)	11 (2–28)	N.S.
Median (range) Expanded Disability Status Scale Score	4.0 (3.0–6.5)	4.5 (2.0–6.5)	N.S.

TABLE 2: Total and cortical/subcortical brain MR lesion loads on RARE, fast-FLAIR, and T1-weighted images in MS patients without and with cognitive impairment

	Unimpaired Patients	Impaired Patients	*P* Value
RARE hyperintense TLL (cm^3)	7.8 (2.4–18.4)	45.7 (4.7–73.7)	.004
RARE hyperintense CSLL (cm^3)	0.1 (0.0–2.3)	6.0 (0.4–28.2)	.001
Fast-FLAIR hyperintense TLL (cm^3)	9.1 (2.7–24.4)	47.0 (4.2–75.3)	.004
Fast-FLAIR hyperintense CSLL (cm^3)	0.2 (0.0–2.7)	7.7 (0.5–27.3)	.001
T1-weighted hypointense TLL (cm^3)	0.8 (0.1–6.2)	15.2 (1.0–47.2)	.003
T1-weighted hypointense CSLL (cm^3)	0.0 (0.0–1.1)	2.6 (0.1–12.9)	.003

Data are reported as median values (range). TLL indicates total lesion load; CSLL, cortical/subcortical lesion load; RARE, rapid acquisition with relaxation enhancement; FLAIR, fluid-attenuated inversion recovery.

TABLE 3: MT histogram-derived measures of the cortical/subcortical regions in MS patients without and with cognitive impairment

	Unimpaired Patients	Impaired Patients	*P* Value
Average MTR (%)	38.6 (1.3)	35.7 (1.4)	.002
MTR_{25} (%)	27.3 (1.9)	22.6 (2.8)	.004
MTR_{50} (%)	33.7 (1.5)	30.6 (1.6)	.003
MTR_{75} (%)	38.0 (1.3)	35.6 (1.0)	.003
Peak height	63.3 (5.8)	54.1 (8.6)	.002
Peak location (%)	36.5 (1.4)	34.3 (1.3)	.006

Data are reported as mean values (SD). MTR indicates magnetization transfer ratio.

on fast-FLAIR, proton density, and T1-weighted images and the average cortical/subcortical MTR as independent covariates.

Results

Sixteen patients had cognitive impairment and six did not. Unimpaired and impaired patients were similar for age, level of education, disease duration, and neurologic disability as assessed by the Expanded Disability Status Scale (37) (Table 1). According to the Lublin and Reingold classification (38), 14 patients (three without and 11 with cognitive impairment) had secondary-progressive MS and eight (three without and five with cognitive impairment) had relapsing-remitting MS. Eleven patients had abnormal results on at least three of the executive function tests; in particular, seven patients scored abnormally on the Weigl Test, three on the Dual Task Test, six on the WCST, seven on the Stroop Test, four on the Hanoi Towers Test, nine on the Verbal Semantic Fluency Test, and all 11 on the Verbal Phonological Fluency Test. Memory impairment was detected in 16 patients; in particular, verbal and visuospatial memory were impaired in six patients, and only visuospatial memory was impaired in 10 patients. In five of the latter patients, visuospatial memory impairment was the only neuropsychological abnormality detected. Composite cognitive scores of individual patients ranged from 8 to 45 (median value, 24).

Multiple cortical/subcortical hyperintense lesions were visible on RARE and fast-FLAIR images in all impaired patients. Two of the six unimpaired patients had multiple cortical/subcortical lesions on RARE images, and four had multiple cortical/subcortical lesions on fast-FLAIR images. On T1-weighted images, multiple hypointense cortical/subcortical lesions were detected in 13 of 16 impaired patients, while only one such lesions was seen in the remaining three patients. Among the unimpaired patients, one had multiple T1 hypointense cortical/subcortical lesions and another had a single T1 hypointense lesion. Table 2 shows the total and cortical/subcortical lesion volume on RARE, fast-FLAIR, and T1-weighted images. Average lesion loads were all significantly higher in the group of cognitively impaired patients.

Table 3 reports the mean values for MTR histographically derived measures for cortical/subcortical brain tissue (Fig 2). These values were all significantly lower in impaired patients than in those with no cognitive dysfunction.

Composite cognitive scores correlated significantly with cortical/subcortical average MTR (SRCC: .65, $P = .002$); MTR_{25} (SRCC: .65, $P = .002$); MTR_{50} (SRCC: .63, $P = .003$); MTR_{75} (SRCC: .62, $P = .003$); histographic peak height (SRCC: .60, $P = .005$); and histographic peak location (SRCC: .65, $P = .002$). The multivariate regression model showed that the average MTR of cortical/subcortical brain tissue alone was significantly associated with the presence of cognitive im-

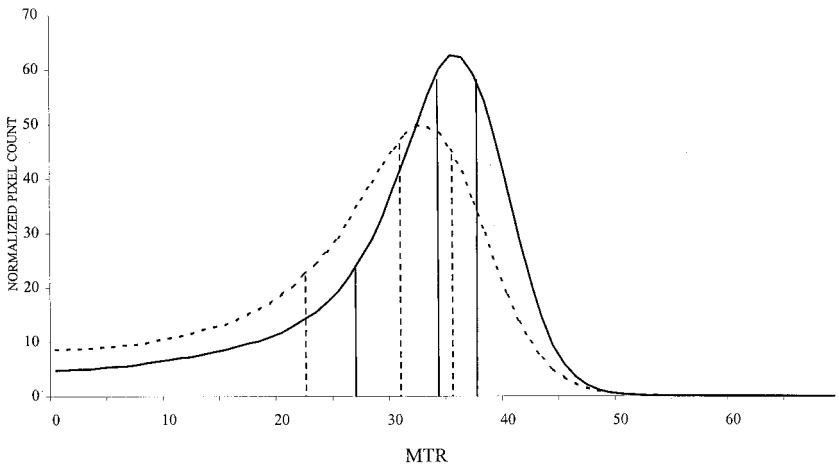

FIG 2. MTR histograms of cortical/subcortical brain regions from MS patients without (*continuous line*) and with (*dotted line*) cognitive impairment. *Vertical lines* represent the MTR values at which the integral of the histogram is 25%, 50%, and 75% of the total (ie, MTR_{25}, MTR_{50} and MTR_{75}). The histogram of MTR values from the cortical/subcortical brain tissue of impaired patients has a lower peak height and location than that obtained from unimpaired patients. For further details and statistical analysis, see text.

pairment in our patients (odds ratio = .87, P = .0005).

Discussion

A recent study (14) correlating MR and pathologic findings from MS patients has confirmed that the amount of lesions located in the subcortical white matter and within the cortex is not negligible. Since these lesions often involve the U fibers and other intra- and interhemispheric associative pathways, their load might significantly contribute to the presence and severity of cognitive impairment in patients with MS (9–11). Miki et al (9), using conventional T2-weighted MR imaging, studied 53 MS patients and found one or more U fiber lesions in 53% of the cases. About two thirds of these lesions were located in the frontal lobe white matter. In the same study, memory and executive functions were significantly more compromised in the eight patients with multiple U fiber lesions. Moriarty et al (10) found that impaired ability on delayed memory retrieval tests correlated well with juxtacortical lesion load in 20 patients with MS. Since fast-FLAIR imaging detects more MS lesions in the subcortical areas (10, 15, 16) and MT imaging encompasses both macro- and microscopic MS disease (39), we used these two techniques to define the role of cortical and subcortical disease indetermining cognitive dysfunction in patients with MS.

Our study confirms that cortical/subcortical lesions can be detected in the majority of MS patients (about 80% in our series) using conventional MR imaging techniques. In addition, the load of MS lesions located in the cortical/subcortical areas was more than 10 times higher in the impaired patients, indicating that the presence and extent of cortical/subcortical lesions are major contributing factors tocognitive impairment in MS. These data agree with those obtained by Miki et al (9) and Moriarty et al (10). Moreover, since impaired and unimpaired patients did not differ significantly in clinical disability, disease course, or disease duration, the influence of these MS-related variables on the different patterns of MR lesion load in the two groups should have been almost completely ruled out.

The use of fast-FLAIR imaging allowed us to detect the presence of cortical/subcortical lesions in two unimpaired patients with no abnormalities in these regions on RARE images. Moreover, the average total volume of lesions was higher on fast-FLAIR than on RARE images. These findings confirm that fast-FLAIR is the most sensitive technique for assessing MS disease burden in the brain (15, 16) and that its use mainly improves the detection of small cortical/subcortical lesions.

In our sample, cognitive impairment occurred primarily in the areas of abstract reasoning and executive skills, which is traditionally associated with frontal lobe dysfunction (25). The strong correlation between cortical/subcortical lesion load in the whole brain and deficit of specific cognitive domains confirms that even lesions located far from the frontal regions might significantly contribute to the impairment of these functions. MS lesions interrupting intra- or interhemispheric associative pathways (9), as well as damage to axons traversing focal lesions and resulting in wallerian degeneration in areas away from such abnormalities (40), may contribute to cognitive dysfunction. Earlier evidence (5, 6) of a strong relationship between lobar lesion burden and impairment in specific cognitive domains has not been confirmed by recent studies (7, 8), which have suggested that the total brain lesion load is more important than regional lesion load in generating cognitive dysfunction in MS. These studies (5–8), however, did not assess the load of subcortical lesions separately. The correlation between total brain MR lesion load and cognitive dysfunction might have been stronger if the extent of MS lesions located in the cortical/subcortical areas had been assessed. This assumption is also indirectly confirmed by the presence of a pattern of cognitive impairment similar to that seen in MS in other diseases with an elective involvement

of subcortical regions, such as myotonic dystrophy (11).

Despite earlier evidence of robust correlations between severity of physical and cognitive impairment and load of MS lesions on T1-weighted MR images (8, 41), our assessment of cortical/subcortical hypointense lesions on T1-weighted images did not add significant information to that available from T2-weighted images. This might in part have derived from the difficulty in identifying ''black holes'' in the white matter close to the cerebral sulci, caused by partial volume effects from CSF. However, results from other investigations (42, 43) also failed to demonstrate the expected strong relationship between worsening disability and accumulation of T1 hypointense lesions, thus suggesting that the robustness of this measure as a marker to monitor destructive disease in MS (44) may be suboptimal.

The MTR histographic analysis of cortical and subcortical brain tissue showed that all the histographically derived measures were significantly different between cognitively impaired and unimpaired patients. In our sample, average cortical/subcortical MTR was the only parameter that was strongly associated with the presence of cognitive impairment. Histographically derived measures are influenced by both the extent and severity of tissue damage within visible MS lesions and the extent of microscopic disease within the normal-appearing brain tissue (22, 23, 39). Therefore, it is likely that both these aspects of MS disease in the cortical/subcortical regions were major contributors to the cognitive impairment in our patients. The relative contributions of macro- and microscopic disease might be disentangled only by additional image postprocessing to exclude macroscopic MS lesions from the histographic analysis, at the cost of increased labor intensiveness. However, owing to the nature of cognitive deficits in MS, whole-tissue analysis might prove to be a more accurate method for understanding the clinical manifestations of this disease than is the separate assessment of macro- and microscopic lesion load. Admittedly, the results of the MTR histographic analysis from brain cortical/subcortical tissue might also be influenced by the presence and extent of brain atrophy, which also correlates with cognitive impairment in MS patients (4). Nonetheless, we believe that our analysis has, at least somewhat, ruled out partial volume averaging from enlarged CSF spaces by excluding pixels with low MTR values and by normalizing MTR histographic parameters for the number of pixels included. In addition, a selective study of cortical and subcortical regions does not include, by definition, the ventricular system, whose enlargement is the most striking evidence of brain atrophy in patients with MS.

Conclusions

Our study shows that the presence and extent of MS disease in the cortical and subcortical regions significantly influence the cognitive functions of these patients. MT imaging findings suggest that both the macro- and microscopic disease burden play an important role, and indicate that MTR histographic analysis might be useful for monitoring the evolution of cognitive impairment in MS.

References

1. Rao SM, Leo GJ, Bernardin L, Unverzagt F. **Cognitive dysfunction in multiple sclerosis: frequency, patterns and prediction.** *Neurology* 1991;41:685–691
2. Comi G, Filippi M, Martinelli V, et al. **Brain MR correlates of cognitive impairment in primary and secondary progressive multiple sclerosis.** *J Neurol Sci* 1995;132:222–227
3. Ormerod IEC, Miller DH, McDonald WI, et al. **The role of NMR imaging in the assessment of multiple sclerosis and isolated neurological lesions: a quantitative study.** *Brain* 1987;110:1579–1616
4. Rao SM, Leo GJ, Haughton VM, St Aubin-Faubert P, Bernardin L. **Correlation of magnetic resonance imaging with neuropsychological testing in multiple sclerosis.** *Neurology* 1989;39:161–166
5. Swirsky-Sacchetti T, Mitchell DR, Seward J, et al. **Neuropsychological and structural brain lesions in multiple sclerosis: a regional analysis.** *Neurology* 1992;42:1291–1295
6. Arnett PA, Rao SM, Bernardin L, Grafman J, Yetkin FZ, Lobeck L. **Relationship between frontal lobe lesions and Wisconsin Card Sorting Test performance in patients with multiple sclerosis.** *Neurology* 1994;44:420–425
7. Foong J, Rozewicz L, Quaghebeur G, et al. **Executive functions in multiple sclerosis: the role of frontal lobe pathology.** *Brain* 1997;120:15–26
8. Rovaris M, Filippi M, Falautano M, et al. **Relation between MR abnormalities and patterns of cognitive impairment in multiple sclerosis.** *Neurology* 1998;50:1601–1608
9. Miki Y, Grossman RI, Udupa JK, et al. **Isolated U-fiber involvement in MS: preliminary observations.** *Neurology* 1998;50:1301–1306
10. Moriarty DM, Blackshaw A, Talbot PR, et al. **Memory dysfunction in multiple sclerosis correlates with juxtacortical lesion load demonstrated by fast FLAIR magnetic resonance imaging.** In: *Proceedings of Seventh Scientific Meeting of the International Society for Magnetic Resonance in Medicine.* Philadelphia: 1999;940
11. Damian MS, Schilling G, Bachmann G, Simon C, Stoppler S, Dorndorf W. **White matter lesions and cognitive deficits: relevance of lesion pattern?** *Acta Neurol Scand* 1994;90:430–436
12. Brownell B, Hughes JT. **The distribution of plaques in the cerebrum in multiple sclerosis.** *J Neurol Neurosurg Psychiatry* 1962;25:315–320
13. Lumdsen CE. **The neuropathology of multiple sclerosis.** In: Vinken PJ, Bruyn GW, eds. *Handbook of Clinical Neurology.* Amsterdam: North-Holland;1970;9:217–309
14. Kidd D, Barkhof F, McConnell R, Algra PR, Allen IV, Revesz T. **Cortical lesions in multiple sclerosis.** *Brain* 1999;122:17–26
15. Filippi M, Yousry TA, Baratti C, et al. **Quantitative assessment of MR lesion load in multiple sclerosis: a comparison of conventional spin-echo with fast fluid-attenuated inversion recovery.** *Brain* 1996;119:1349–1355
16. Gawne-Cain ML, O'Riordan JI, Thompson AJ, Moseley IF, Miller DH. **Multiple sclerosis lesion detection in the brain: a comparison of fast fluid-attenuated inversion recovery and conventional T2-weighted dual spin-echo.** *Neurology* 1997;49:364–370
17. Loevner LA, Grossman RI, Cohen JA, Lexa FJ, Kessler D, Kolson DL. **Microscopic disease in normal-appearing white matter on conventional images in patients with multiple sclerosis: assessment with magnetization-transfer measurements.** *Radiology* 1995;196:511–515
18. Allen IV, McKeown SR. **A histological, histochemical and biochemical study of the macroscopically normal white matter in multiple sclerosis.** *J Neurol Sci* 1979;41:81–91
19. Adams CMW. **Pathology of multiple sclerosis: progression of the lesion.** *Br Med Bull* 1977;33:15–20
20. Dousset V, Grossman RI, Ramer KN, et al. **Experimental allergic encephalomyelitis and multiple sclerosis: lesion characterization with magnetization transfer imaging.** *Radiology* 1992;182:483–491

21. van Buchem MA, McGowan JC, Kolson DL, Polansky M, Grossman RI. **Quantitative volumetric magnetization transfer analysis in multiple sclerosis: estimation of macroscopic and microscopic disease burden.** *Magn Reson Med* 1996;36:632–636
22. Filippi M, Iannucci G, Tortorella C, et al. **Comparison of MS clinical phenotypes using conventional and magnetization transfer MR.** *Neurology* 1999;52:588–594
23. van Buchem MA, Grossman RI, Armstrong C, et al. **Correlation of volumetric magnetization transfer imaging with clinical data in MS.** *Neurology* 1998;50:1609–1617
24. Poser CM, Paty DW, Scheinberg L, et al. **New diagnostic criteria for multiple sclerosis: guidelines for research protocols.** *Ann Neurol* 1983;13:227–231
25. Peyser JM, Edwards KR, Poser CM, Filskov SB. **Cognitive function in patients with multiple sclerosis.** *Arch Neurol* 1980;37: 577–579
26. Badeley A, Della Sala S, Papagno C, Spinnler H. **Dual task performance in dysexecutive and non dysexecutive patients with a frontal lesion.** *Neuropsychology* 1997;11:187–194
27. Weigl E. **On the psychology of the so called processes of abstraction.** *J Abnorm Soc Psychol* 1927;36:3–33
28. Heaton RH. ***Wisconsin Card Sorting Test (Manual).*** Odessa, FL: Psychological Assessment Resources; 1981
29. Stroop JR. **Studies of interference in serial verbal reactions.** *J Exp Psychol* 1935;18:643–662
30. Pozzilli C, Bastianello S, Padovani A, et al. **Anterior corpus callosum atrophy and verbal fluency in multiple sclerosis.** *Cortex* 1991;27:441–445
31. Shallice T. **Specific impairments of planning.** *Philos Trans R Soc Lond B Biol Sci* 1982;298:199–209
32. Pagano G, Valla RG. **Verbal and special immediate memory span: normative data from 1355 adults and 1112 children.** *Ital J Neurol Sci* 1987;8:539–548
33. Spinnler H, Tognoni G. ***Standardizzazione e Taratura Italiana di Test Neuropsicologici.*** Milan, Masson; 1987
34. Miller DH, Barkhof F, Berry I, Kappos L, Scotti G, Thompson AJ. **Magnetic resonance imaging in monitoring the treatment of multiple sclerosis: concerted action guidelines.** *J Neurol Neurosurg Psychiatry* 1991;54:683–688
35. Rovaris M, Filippi M, Calori G, et al. **Intra-observer reproducibility in measuring new MR putative markers of demyelination and axonal loss in multiple sclerosis: a comparison with conventional T2-weighted images.** *J Neurol* 1997;244:266–270
36. Gonzales RC, Woods RE. ***Digital Image Processing.*** Reading, MA: Addison-Wesley;1992;518–559
37. Kurtzke JF. **Rating neurological impairment in multiple sclerosis: an expanded disability status scale (EDSS).** *Neurology* 1983;33:1444–1452
38. Lublin FD, Reingold SC, the National Multiple Sclerosis Society (USA) Advisory Committee on Clinical Trials of New Agents in Multiple Sclerosis. **Defining the clinical course of multiple sclerosis: results of an international survey.** *Neurology* 1996;46: 907–911
39. Filippi M, Campi A, Dousset V, et al. **A magnetization transfer imaging study of normal-appearing white matter in multiple sclerosis.** *Neurology* 1995;45:478–482
40. De Stefano N, Matthews PM, Narayanan S, Francis GS, Antel JP, Arnold DL. **Axonal dysfunction and disability in a relapse of multiple sclerosis: longitudinal study of a patient.** *Neurology* 1997;49:1138–1141
41. Truyen L, van Waesberghe JHTM, van Walderveen MAA, et al. **Accumulation of hypointense lesions (“black holes”) on T1 spin-echo MR correlates with disease progression in multiple sclerosis.** *Neurology* 1997;47:1469–1476
42. Gasperini C, Paolillo A, Giugni E, et al. **Effect of interferon beta 1a on MR brain volume in relapsing remitting multiple sclerosis.** *Neurology* 1999;52(Suppl 2):A379
43. Simon JH, Miller DE, Lull J, Sheeder J, Simonian N, Jacobs L. **Natural history and effect of IFN β-1a (Avonex) on T1-hypointense lesions (T1 “black holes”).** *Neurology* 1999;52(Suppl 2):378
44. van Walderveen MAA, Kamphorst W, Scheltens P, et al. **Histopathologic correlate of hypointense lesions on T1-weighted spin-echo MR in multiple sclerosis.** *Neurology* 1998;50:1282–1288