AJNR

Is an Early Angiogram Needed?

Wan-Yuo Guo

AJNR Am J Neuroradiol 2000, 21 (3) 608-609
http://www.ajnr.org/content/21/3/608.1

This information is current as
of October 11, 2024.

In Re: Radiologic and Histopathologic Evaluation of Canine Artery Occlusion After Collagen-Coated Platinum Microcoil Delivery

I read with interest, in the April 1999 issue of *AJNR*, the article of Tamatani and colleagues (1) on the evaluation of endovascular collagen-coated coils in the experimental setting, and the relative editorial of Berenstein on future developments of coils for aneurysms (2). In our field of endovascular neurosurgery, we all have seen in recent years many experimental articles dealing with surface modifications of coils, collagen added to coils, coatings added to coils, etc. The appropriate references are all in the thorough and articulate article of Tamatani and colleagues (1).

I would like to comment on the sentence of Dr. Berenstein: ''The delivery of coated or biologically altered coils into the aneurysmal lumen seems to be a promising method for producing intravascular scars, and may represent a revolution in the management of presently unmanageable lesions.'' I sincerely hope that Dr. Berenstein is right. We have to consider, however, that regular GDCs, because of their malleability and elasticity, may partially absorb the pulsatile energy of the blood circulation by damping the acute spike of the systole and gradually redistributing the systolic energy to the entire wall of the aneurysm. In other words, coils may act as the shoreline that transforms the waves of the sea into a continuous motion of the water. I cannot imagine any other explanation for why, as Dr. Berenstein suggests, even subtotally coiled aneurysms have a low (re)bleeding rate. If this is true, then the fact that GDCs do not induce a ''scar'' would be a ''good thing.'' I do not know if an intra-aneurysmal scar would improve aneurysm healing or would act as a hammer toward any residual portion of the aneurysm. A scar could induce retraction of the walls of the parent vessel with consequent stenosis. Unlike coiling or clipping, a scar could offer a wide, stiff surface to the systole with unknown effects on the parent artery and on any residuum of the aneurysm. One thing is certain—with an intra-aneurysmal scar, we would lose forever the shock-absorbing effect of the coils. In any event, experimental aneurysms are so different from their human counterpart that any extrapolation of medium long-term results would be inaccurate. As often happens in science, there was some casualty and luck in 1989–1990 when our experimental work (that led to the GDCs) was also successful in patients. I do not intend to dampen the enthusiasm of clinicians who aim to change GDCs with bioactive materials in order to obtain a more stable aneurysm occlusion. Nevertheless we will have to be very cautious in expanding experimental findings beyond their boundaries.

Guido Guglielmi, M.D.
University of Rome Medical School
Department of Neurosciences
Rome, Italy

References

1. Tamatani S, Ozawa T, Minakawa T, Takeuchi S, Koike T, Tanaka R. **Radiologic and histopathologic evaluation of canine artery occlusion after collagen-coated platinum microcoil delivery.** *AJNR Am J Neuroradiol* 1999;20:541–545
2. Berenstein A. **Tissue response to Guglielmi detachable coils: present implications and future developments. Editorial.** *AJNR Am J Neuroradiol* 1999;20:533–534

Intraventricular Melanoma

Arbelaez et al (1) reported the imaging features of an intraventricular melanoma. They ascribed some regions of T1 hyperintensity to the presence of stable free radicals within melanin. According to Enochs et al (2), melanin bound $Fe3^{+}$ is the major contributor to melanin 1/T1 in clinical conditions. The authors fail to mention that melanin-associated T1 hyperintensity is seen only in melanotic melanomas (3, 4). Neither their operative description of a ''. . . dark greenish and brown mass. . . '' nor their pathologic section and description ''. . . scattered neoplastic cells displayed dusky brown intracytoplasmic pigment (Fig H). . . '' support the diagnosis of a melanotic melanoma. The authors did not observe any hemorrhage and failed to mention the frequency of hemorrhage in melanoma (4) and its possible contribution to the T1 hyperintensity of their case. This is especially significant in their case because of the clear evidence of a layer of red blood cells in the associated left occipital horn (Ref 1, Figure 1) with combined CT and MR properties of intracellular deoxyhemoglobin. In addition, there are CT and MR imaging suggestions of a similar hematoma in the posterior part the intraventricular tumor. The intraventricular hemorrhage and probable intratumoral hemorrhage may have also contributed to the patient's headache.

John M. Gomori, M.D.
Hadassah University Medical Center
Jerusalem, Israel

References

1. Arbelaez A, Castillo M, Armao DM. **Imaging features of intraventricular melanoma.** *AJNR Am J Neuroradiol* 1999;20:691–693
2. Enochs WS, Hyslop WB, Bennett HF, Brown RD. III, Koenig SH, Swartz HM. **Sources of the increased longitudinal relaxation rates observed in melanotic melanoma. An in vitro study of synthetic melanins.** *Invest Radiol* 1989;24:794–804
3. Gomori JM, Grossman RI, Shields JA, Augsburger JJ, Joseph PM, DeSimeone D. **Choroidal melanomas: correlation NMR spectroscopy and MR imaging.** *Radiology* 1986;158:443–445
4. Atlas SW, Grossman RI, Gomori JM, Guerry D, Hackney DB, Goldberg HI, Zimmerman RA, Bilaniuk LT. **MR imaging of intracranial metastatic melanoma.** *J Comput Assist Tomogr* 1987; 11:577–582

Reply

We thank Dr. Gomori for his comments regarding our case report of a patient with an intraventricular melanoma. We agree that imaging of intracranial melanomas is complex. Melanotic melanomas have a typical appearance (bright on T1- and dark on T2-weighted images), whereas amelanotic melanomas have fewer typical features (mildly hypointense on T1- and mildly hyperintense on T2-weighted images). These features may be complicated by the presence of hemorrhage that happens in both melanotic and amelanotic melanomas. Once a hemorrhage has occurred, its MR imaging features are less specific, and the differential diagnosis expands. At 1.5 T, intracellular methemoglobin may have similar characteristics to melanotic melanoma. In the article by Atlas et al, the incidence of hemorrhage in metastatic brain melanomas was not given (1). To the best of our knowledge, the incidence of hemorrhage in these tumors is not well established. According to Enochs et al, the T1 shortening in melanotic melanomas is owing to binding of metallic ions such as $Fe3^+$, $Mn2^+$, and $Cu2^+$ to melanin (2). In addition, aggregation of melanin in macromolecular particles contributes to this feature.

Although no intratumoral hemorrhage was found in our case (except that presumed to be due to surgical manipulation), we agree with Dr. Gomori that there is a suspicion for hemorrhage in the left occipital horn. The presence of microhemorrhages, not visible as discrete lesions on CT or MR imaging, may contribute to the appearance of some melanomas on imaging studies. In our patient, we believe that the imaging features were from hypercellularity, compactness, and the presence of melanin rather than hemorrhage. We disagree with his comment regarding the lack of support, from a histologic standpoint, in the diagnosis of melanoma. We clearly showed that, using HMB-45, the tumor strongly showed immunoreactivity. This marker is very specific for melanomas and nevus precursor cells (3). Occasionally, this marker may show cross-reactivity with angiomyolipomas and carcinomas. In our patient, we also used immunohistochemical markers for cytokeratin, leukocyte common antigens (marker for lymphoma), and glial fibrillary acidic protein, and all were negative.

Mauricio Castillo, M.D.
Diane M. Armao, M.D.
University of North Carolina School of Medicine
Chapel Hill, NC

References

1. Atlas SW, Grossman RI, Gomori JM, et al. **MR imaging of intracranial metastatic melanoma.** *JCAT* 1987;11:577–582
2. Enochs WS, Hyslop WB, Bennett HF, Brown RD, Koenig SH, Swartz HM. **Sources of the increased longitudinal relaxaton in melanotic melanoma. An in vitro study of synthetic melanins.** *Invest Radiol* 1989;24:794–804
3. Brat DJ, Giannini C, Scheithauer BW, Burger PC. **Primary melanocytic neoplasms of the central nervous system.** *Am J Surg Pathol* 1999;23:745–754

Is an Early Angiogram Needed?

The value of arteriovenous malformation (AVM) radiosurgery is its noninvasive nature, and efforts should be made to minimize the invasiveness that is relevant to associated diagnostic imaging procedures. MR imaging, for diagnosis, treatment guidance, and follow-up is the most helpful tool to meet this purpose. For many AVMs that have a classic MR appearance, we may reconsider the use of diagnostic X-ray angiography to determine the feasibility of radiosurgery. For radiosurgical guidance, stereotaxic X-ray angiography remains the standard of reference imaging technique (1), and for those AVMs with repeated episodes of hemorrhage or previous partial surgical extirpation, X-ray angiography is mandatory. Stereotaxic MR imaging, however, is of great value in providing three-dimensional delineation of the AVM nidus, which is the only target in AVM radiosurgery (2). In AVM radiosurgery, stereotaxic X-ray angiography and stereotaxic MR imaging are performed on the same stereotaxic system, and the location and coordinates of the target lesion in the stereotaxic space is transferable. We are, therefore, able to integrate the information derived from MR imaging and X-ray angiography for a better delineation of the AVM nidus. This imaging strategy improves the delivery of effective dose levels and provides a better irradiation volume in AVM radiosurgery. It, consequently, safely expands the indication of radiosurgery for larger AVMs and explores new indications, such as dural arteriovenous fistulas of the cavernous sinus with radiosurgery (3–5).

After radiosurgery, the involuting AVM seems to be equally ‘‘visible’’ on both MR images and X-ray angiograms. MR imaging can show a decreasing size as early as 3 months after radiosurgery (6). Concerning the bleeding rate of AVMs treated radiosurgically in the time lag prior to complete obliteration, the data available in the literature is controversial. Our data, based on follow-up of our protocol of AVM patients, have shown that the clinical bleeding rate in this time period is lower than the natural history of bleeding. Subclinical hemorrhage, however, (eg, petechia in AVM regions), as depicted on MR images, is much more frequent than expected (7). In documenting complete obliteration in AVM radiosurgery, MR imaging plays a vital role (8). The challenge to neuroradiologists should be to use MR imaging exclusively to verify complete AVM obliteration.

Wan-Yuo Guo, MD, PhD
Veterans General Hospital
Taipei, Taiwan

References

1. Guo WY, Lindqvist M, Linquist C, et al. **Stereotaxic angiography in gamma knife radiosurgery of intracranial arteriovenous malformations.** *AJNR Am J Neuroradiol* 1992;13:1107–1113
2. Guo WY, Nordell B, Karlsson B, et al. **Target delineation in radiosurgery for cerebral arteriovenous malformations. Assessment of the value of stereotaxic MR imaging and MR angiography.** *Acta Radiol* 1993;34:457–463
3. Guo WY, Pan HC, Shiau CY, et al. **AVM radiosurgery,where is the volume limit?** *Rivista di Neuroradiol* 1999;12 (Suppl 2):35–40
4. Guo WY, Pan HC, Wu HM, et al. **Radiosurgery as a treatment alternative for dural arteriovenous fistulas of cavernous sinus.** *AJNR Am J Neuroradiol* 1998;19:1081–1087
5. Guo WY. **Application of MR in radiosurgery.** *JMRI* 1998;8:415–420
6. Guo WY, Pan HC, Liu RS, et al. **Early irradiation effects observed on MRI and MRA, and PET for arteriovenous malformations treated by gamma knife radiosurgery.** *Stereot and Funct Neurosurg* 1995;64 (suppl 1):258–269
7. Guo WY, Chung WY, Shiau, CY, Wu, HM, Wang LW, Pan HC. **Is subclinical hemorrhage common? Neuroimaging and clinical evaluation after AVM radiosurgery.**In: Kondziolka D, ed. *Radiosurgery* Vol 2. Basel, Krager, 1997;157–172
8. Guo WY, Pan HC, Chung WY, Wang LW, Teng MMH. **Do you need conventional angiography? The role of MR in verifying totally obliterated AVMs.** *Stereot and Funct Neurosurg* 1996;66 (suppl 1):71–84

A Case of Cleidocranial Dysplasia Confirmed by 3D CT of the Cranium

Cleidocranial dysplasia (CCD) is an autosomal dominant disorder characterized by absence or hypoplasia of the clavicles, an open fontanelle (1–4), and malaligment of the teeth (2). In previous reports, CCD was diagnosed by plain X-ray films of the cranium and chest. These may show widened fontanelles, wormian bones in the cranium, and a bell-shaped thorax with absence or hypoplasia of the clavicles (1–4). We found 3D CT more clearly showed the open fontanelle than did a radiograph of the skull, and we believe 3D CT is helpful in the diagnosis of CCD in older children.

Our patient was a 4-year-old boy of short stature. Hyperterolism and a broad and flat nasal bridge was noted. On physical examination, a four-finger-width open anterior fontanelle was noted. Chest film showed a bell-shaped thorax with a narrowed upper portion and complete absence of both clavicles. The skull films showed multiple wormian bones in the cranium (Fig 1A); however, the open fontanelle was not seen in the anteroposterior view, but was suspicious on the lateral view (Fig 1B). A spiral CT scan with 4-mm slice thickness and 3D reconstruction of the cranium was performed (Fig 1C).

Although many children with CCD have an open fontanelle (2, 4), this finding is not always clear in older children (1, 4) because, with increasing age, there is more mineralization in the cranium, and the calvarial bone thickness increases. In the anteroposterior view, the opened fontanelle is superimposed by the occipital bone (Fig 1A), so it is difficult to see. With 3D CT, however, the open fontanelle can be clearly delineated (Fig 1C) and will correspond to the presence of a widened fontanelle. We recommend 3D CT of the cranium be performed in patients with CCD.

Wu-Chung Shen
China Medical College Hospital
Taichung, Taiwan

References

1. Edeiken J, Hodes Philip J. **Cleidocranial dysostosis.** In: *Golden's Diagnostic Radiology.* Vol 1. Baltimore, Md: Williams & Wilkins Co; 1973;235–236
2. Kargul B, Salih IM, Yilmaz L, Dumlu A. **Cleidocranial dysostosis: report of a case.** *J Clin Pediatr Dent* 1997;22:83–86
3. Richardson A, Deussen FF. **Facial and dental anomalies in cleidocranial dysplasia: a study of 17 cases.** *Int J Paediatr Dent* 1994;4:225–231
4. Jensen BL, Kreiborg S. **Craniofacial growth in cleidocranial dysplasia–a roentgencephalometric study.** *J Craniofac Genet Dev Biol* 1995;15:35–43

Spinal Cord Herniation—Which One Is Really Traumatic?

I read the articles by Watters et al (1) and Dix et al (2) with great interest. Having had experience with a similar case very recently, I felt obliged to emphasize a few points.

First, Watters et al seem to have overlooked at least 10 cases of spontaneous spinal cord herniation (SSCH) in their review, four of which were fortunately included by Dix et al. I know of six more well-described SSCH cases that I would like to

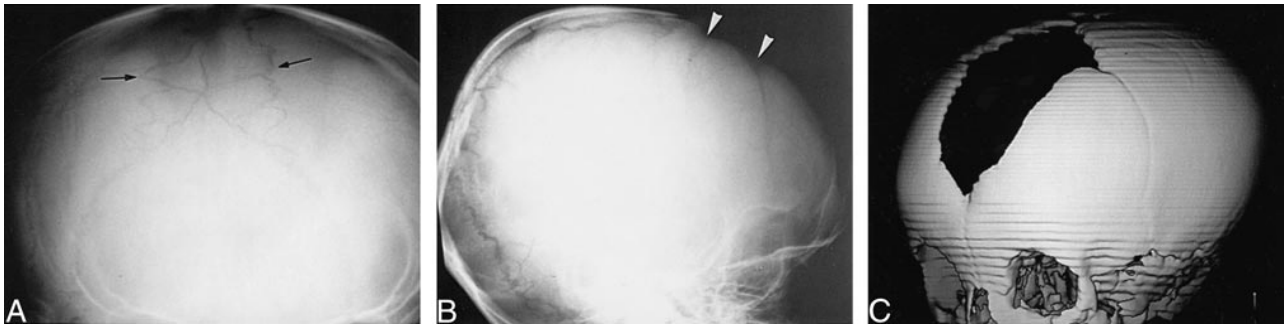

FIG 1. *A, B,* Skull films. In the anteroposterior view (*A*), wormian bones are noted (*arrows*); however, the open fontanelle is not clearly visible. In the lateral view (*B*), defect of the cranium in the fontanelle region is noted (*arrowhead*).
C, 3D CT of cranium. The open anterior fontanelle is clearly visible.

draw to the attention of *AJNR* readers (3–6). The main issue I raise is Watters et al lack of criteria for differentiating spontaneous cord herniation with history of irrelevant or trivial trauma from true post-traumatic spinal cord herniation. Reviewing the literature on spinal cord herniation of all types, I was able to see that when there was a history of slightest trauma, everything focused on this hard-to-get information.

Three cases included in Table 2 of Watters et al's article labeled as post-traumatic cord herniation (7–9) had their injury more than 3 decades prior to their presentation or the onset of symptoms and I think all three of these cases in fact are SSCH cases. Wortzman et al noted that their patient ''. . . had fractured his pelvis. . . and suffered several minor injuries to his back'' 36 years prior to presentation (7). We do not know the level of these minor injuries, but the herniation at T7 is obviously quite distant to the pelvis. Findings in Borges et al's second patient suggest a similar contradiction. This 68-year-old man was hit by shrapnel from a grenade explosion 40+ years prior to symptom onset or his presentation (8). Again, there are no specific data about the level of injury that one can correlate with the herniation at T3 level. The third patient was reported by Urbach et al. It is somewhat more natural for Watters et al to include this case as post-traumatic, because the very author of the article defines a childhood trauma as the cause both in the title and the abstract (9). This 44-year-old patient sustained ''a blunt spinal injury without fracture, but with temporary paraparesis,'' yet there was no mention of level of injury or mention of type of paraparesis (spastic versus flaccid). The case was labeled as post-traumatic because Urbach et al thought they discarded all other causes.

The second case reported by Watters et al is similar to these, and I do not believe that case is post-traumatic. Their patient experienced a whiplash injury with initial torso hyperextension followed by torso flexion and immediate onset of lumbar pain. I do not think such a trivial event focused in the lumbar area can be the objective cause of a cord herniation at the T6 level, which is a level heavily protected by the support of the rib cage.

I would like to emphasize that if there is not closed or penetrating injury at the relevant level, one cannot scientifically attribute trauma as the cause of the dural defect and hence, the herniation. Likewise, when there is a fractured vertebra (eg, compression fracture) with the herniation at the same level, like the one reported by Baur et al (5), or a penetrating (ie, stab) injury (10) exactly at the level of herniation, only then can one convincingly call this post-traumatic cord herniation.

I suggest that Watters et al may have confused the readership by discussing all types of cord herniation together and by defining new neuroradiologic signs that have no relevance to the diagnosis or differential diagnosis of transdural spinal cord herniation. They say ''nuclear trail sign'' suggested a previously herniated disk fragment. Such a relationship was previously suggested but has not been confirmed. Both Borges et al (8) and Hausmann and Moseley (11) thought the cause of myelopathy (hence the cause of the dural defect) was the disk herniation, but no surgeon has so far been able to detect any extruded disk remnant while reducing the herniated portion of the spinal cord. The same holds true for a ''syrinx associated with post-traumatic cord herniation.'' Trauma is a well known cause of syringomyelia, and when trauma is significant, it can cause both.

I agree, however, that SSCH is an underdiagnosed entity and that, with increasing awareness, more and more cases will be revealed because sagittal MR imaging is almost pathognomonic.

Ismail H. Tekkök, M.D.
Bayindir Medical Center
Ankara, Turkey

References

1. Watters MR, Stears JC, Osborn AG, et al. **Transdural spinal cord herniation: imaging and clinical spectra.** *AJNR Am J Neuroradiol* 1998;19:1337–1344
2. Dix JE, Griffitt W, Yates C, Johnson B. **Spontaneous thoracic spinal cord herniation through an anterior dural defect.** *AJNR Am J Neuroradiol* 1998;19:1345–1348
3. White BD, Firth JL. **Anterior spinal hernia: an increasingly recognized cause of thoracic cord dysfunction.** *J Neurol Neurosurg Psychiatry* 1994;57:1433–1435
4. Batzdorf U. **Comment.** *Neurosurgery* 1995;36:1032–1033
5. Baur A, Stabler A, Psenner K, Hamburger C, Reiser M. **Imaging findings in patients with ventral dural defects and herniation of neural tissue.** *Eur Radiol* 1997;7:1259–1263
6. Miyake S, Tamaki N, Nagashima T, Kurata H, Eguchi T, Kimura H. **Idiopathic spinal cord herniation. Report of two cases and review of the literature.** *J Neurosurg* 1998;88:331–335
7. Wortzman G, Tasker RR, Rewcastle NB, Richardson JC, Pearson FG. **Spontaneous incarcerated herniation of the spinal cord into a vertebral body.** *J Neurosurg* 1974;41:631–635
8. Borges LF, Zervas NT, Lehrich JR. **Idiopathic spinal cord herniation: a treatable cause of the Brown-Séquard syndrome case report.** *Neurosurgery* 1995;36:1028–1033
9. Urbach H, Kaden B, Pechstein U, Solymosi L. **Herniation of the spinal cord 38 years after childhood trauma.** *Neuroradiology* 1996;38:157–158
10. Lee ST, Lui TN, Jeng CM. **Spinal cord herniation after stabbing injury.** *Br J Neurosurg* 1997;11:84–86
11. Hausmann ON, Moseley IF. **Idiopathic dural herniation of the thoracic spinal cord.** *Neuroradiology* 1996;38:503–510

Reply

We would like to thank Dr. Tekkök for his letter regarding our report (1) describing five cases of transdural spinal cord herniation and a review of 25 additional cases from the medical literature. A companion article (2) published in the same issue of *AJNR* described a case, as well as provided references for two cases (3, 4) from literature not included in our review. Dr. Tekkök provides literature references for three other cases (5–7) published prior to the submission of our article, as well as three cases reported subsequently (8). Collectively, this adds 10 additional cases, and we concur that such

information would be of interest to readers of the *AJNR*.

Dr. Tekkök is correct to note that a history of remote trauma may be obtained from some patients, occurring decades prior to clinical presentation. Whether such is ''irrelevant or trivial,'' as suggested by Dr. Tekkök, is impossible to determine with present information. We chose to classify cases in which a history of accidental trauma was described by the patient (or author) as *posttraumatic,* and considered the possibility that such trauma precipitated the initial dural tears.

Most reported cases of transdural spinal cord herniation do not occur acutely after an identifiable event, although such has been reported (7). The majority occur without apparent provocation (which we and some others had termed as *spontaneous,* others as *idiopathic,* herniations). It has been proposed (2, 5, 9–13) that such patients have dural openings on a congenital basis, initially asymptomatic, although subclinical trauma unrecognized by the patient is also possible. The role minor or major trauma play in facilitating the development of spinal cord herniation through established dural defects remains to be determined and may not be as important for patient management as clinical and imaging features. Clinical presentations with myelopathic signs characteristically do not appear until after age 30 years. Clinical deterioration once symptoms begin is gradually progressive for another 1 to 6 years, until surgical correction of the transdural cord herniation has been made. A similar delay of several decades or more seems equally plausible for patients with a remote history of trauma, initially asymptomatic (clinically too ''trivial'' to cause symptomatic spinal cord injury), but perhaps sufficient to tear the dura. Such proposed mechanisms would permit the initial dural opening to have existed for many years prior to the onset of symptoms, regardless of what subsequent processes result in cord herniation through an established dural defect. Whether or not all patients who have dural openings (whether congenital or acquired) who survive past age 30 will develop symptomatic transdural herniation is unknown. An isolated dural defect is probably less obvious on imaging studies than when associated with spinal cord displacement, and imaging studies are less likely to be obtained during asymptomatic periods. Perhaps such cases will be identified in the future to define the natural history of the condition better.

Whether a dural tear occurs spontaneously, posttraumatically, or congenitally eventually may be shown to affect the natural history and course of the transdural cord herniation. We have thus far found only limited clinical differences. Our review of 30 cases, and the additional 10 cases in references provided by Dix et al (2) and Dr. Tekkök, indicate that the absence of a history of remote trauma is more often associated with female gender, and more likely to manifest clinically as a Brown-Séquard syndrome. When a history of remote trauma (not acutely associated with myelopathic symptoms and signs) is uncovered, the patient is more likely to be male, and more likely to manifest diffuse myelopathic signs. Our intent was not to resolve the mechanisms of the dural opening or transdural herniation of the cord, but to provide imaging data to facilitate clinical diagnosis and possible surgical intervention. To our knowledge our report of five cases is the largest series to date, as is our review of 25 previously reported cases, and is a broad review of cases of possibly differing etiologies. We appreciate the additional case references and comments provided by Dr. Tekkök, and acknowledge the limitations that case studies afford regarding pathologic and etiologic mechanisms. We suggest as a goal the earlier identification of transdural herniation. The increasing and disseminated knowledge of the process may lead to earlier evaluations. We suggest prospectively improved MR studies, better understanding of the MR details (as we have attempted), and additional operative and histologic detail.

Michael R. Watters, M.D.
University of Hawaii

John C. Stears, M.D.
University of Colorado

William T.C. Yuh, M.D.
University of Iowa

Bradford S. Burton, M.D.
University of Hawaii

Anne G. Osborn, M.D.
University of Utah

References

1. Watters MR, Stears JC, Osborn AG, et al. **Transdural spinal cord herniation: imaging and clinical spectra.** *AJNR AM J Neuroradiol* 1998;19:1337–1334
2. Dix JE, Griffitt W, Yates C, Johnson B. **Spontaneous thoracic spinal cord herniation through an anterior dural defect.** *AJNR Am J Neuroradiol* 1998;19:1345–1348
3. Sioutos P, Arbit E, Tsairis P, Gargan R. **Spontaneous thoracic spinal cord herniation through an anterior dural defect.** *Spine* 1996;21:1710–1713
4. Oe T, Hoshino Y, Kurokawa T. **A case of idiopathic herniation of the spinal cord associated with duplicated dura mater and with an arachnoid cyst.** *Nippon Seikeigeka Gakkai Zassh* 1990; 64:43–49
5. Miyake S, Tamaki N, Nagashima T, Kurata H, Eguchi T, Kimura H. **Idiopathic spinal cord herniation, report of two cases and review of the literature.** *J Neurosurg* 1998;88:331–335
6. White BD, Firth JL. **Anterior spinal hernia: an increasingly recogised cause of thoracic cord dysfunction.** *J Neurol Neurosurg Psychiatry* 1994;57:1433–1435
7. Lee ST, Lui TN, Jeng CM. **Spinal cord herniation after stabbing injury.** *Br J Neurosurg* 1997;11:84–86
8. Baur A, Stabler A, Psenner K, Hamburger C, Reiser M. **Imaging findings in patients with ventral dural defects and herniation of neural tissue.** *Eu Radiol* 1997;7:1259–1263
9. Borges LF, Zervas NT, Lehrich JR. **Idiopathic spinal cord herniation: a treatable cause of the Brown-Séquard syndrome–case report.** *Neurosurgery* 1995;36:1028–1033

10. Masuzawa H, Nakayama H, Shitara N, Suzuki T. **Spinal cord herniation into a congenital extradural arachnoid cyst causing Brown-Séquard syndrome.** *J Neurosurg* 1981;55:983–986
11. Isu T, Iizuka T, Iwasaki Y, Nagashima M, Akino M, Abe H. **Spinal cord herniation associated with an intradural spinal arachnoid cyst diagnosed by magnetic resonance image.** *Neurosurgery* 1991;29:137–139
12. Tronnier Vm, Steinmetz A, Albert FK, Scharf J, Kunze S. **Hernia of the spinal cord: case report and review of the literature.** *Neurosurgery* 1991;29:916–919
13. Nakazawa H, Toyama Y, Satomi K, Fujimura Y, Hirabayashi K. **Idiopathic spinal cord herniation, report of two cases and review of the literature.** *Spine* 1993;18:2138–2141

Spinal Cord Decompression Sickness

We read with interest the case report by Manabe et al (1) *Presumed Venous Infarction in Spinal Decompression Sickness*, in the *AJNR*. The authors stated that, to their knowledge, no previous reports have described MR signal abnormalities in the spinal cord associated with this syndrome; however, a valuable article by Warren et al was published in the November 1988 issue of the *AJR* and in the September/October 1988 issue of the *AJNR* (2) describing the same MR signal abnormalities in the spinal cord in decompression sickness (DCS) type II. In 1997, Reuter et al again described this MR finding in *Acta Radiologica* (3), and we described reversible MR signal abnormalities in the spinal cord associated with DCS type II after successful hyperbaric oxygen therapy (4).

We do, in conclusion, believe that Manabe and colleagues' report provides further evidence of the venous infarction theory as the pathophysiologic mechanism of involvement of the spinal cord in DCS type II and points to the usefulness of hyperbaric oxygen therapy in the treatment of the syndrome.

Gianvincenzo Sparacia, M.D.
Giuseppe Brancatelli, M.D.
Institute of Radiology University of Palermo
Palermo, Italy

References

1. Manabe Y, Sakai K, Kashihara K, Shohmori T. **Presumed venous infarction in spinal decompression sickness.** *AJNR Am J Neuroradiol* 1998;19:1578–1580
2. Warren LP, Djang WT, Moon RE, et al. **Neuroimaging of scuba diving injuries to the CNS.** *AJR Am J Roentgenol* 1988;151:1003–1008 *AJNR Am J Neuroradiol* 1988;9:939–942
3. Reuter M, Tetzlaff K, Hutzelmann A. **MR imaging of the central nervous system in diving-related decompression illness.** *Acta Radiologica* 1997;38:940–944
4. Sparacia G, Banco A, Sparacia B. **Magnetic resonance findings in scuba diving-related spinal cord decompression sickness.** *MAGMA* 1997;5:111–115

Reply

We appreciate the opportunity to reply to Dr. Sparacia's and Brancatelli's letter about MR images of spinal cord decompression sickness. We did not find the three case reports as Dr. Sparacia described when we wrote our report. We are grateful to Dr. Sparacia for his suggestion regarding our case report. The areas of increased T2 signal intensity in the dorsal columns of the spinal cord is shown to be useful in the diagnosis of the spinal cord decompression sickness. The arterial, venous, and autochthonous theories have been proposed in an attempt to describe the pathophysiologic events that lead to decompression sickness (1, 2). The arterial theory claims that arterial embolization of the microcirculation in the spinal cord and expansion of the bubbles by the assimilation of inert gas from the surrounding tissues finally lead to ischemia and tissue death. The venous theory proposes that bubbles in the spinal epidural venous system activate the clotting factors and platelet aggregation, leading to stagnation and venous obstruction. The autochthonous theory suggests that bubbles within the spinal cord tissue create sufficient local pressure to occlude blood flow, causing anoxic damage and myelin sheath disruption, and the high solubility of nitrogen in myelin with its high fat content leads to further injury of the spinal cord. Our case report, as well as the three cases described by Dr. Sparacia, lend support to the venous theory (3). We emphasized the utility of serial MR imaging for 2 months. Our case contributes to the understanding of the pathophysiologic processes of decompression sickness.

Yasuhiro Manabe, M.D.
Okayama University Medical School
Okayama, Japan

References

1. Kykes JJW. **Spinal cord decompression sickness: a review of the pathology and some new findings.** *J R Nav Serv* 1985;71:139–143
2. Aharon-Peretz J, Adir Y, Gordon, CR, Kol S, Gal N, Melamed Y. **Spinal cord decompression sickness in sport diving.** *Arch Neurol* 1993;50:753–756
3. Manabe Y, Sasaki K, Kashihara K, Shohmori T. **Presumed venous infarction in spinal decompression sickness.** *AJNR Am J Neuroradiol* 1998;19:1578–1580

The Evolutionary and Embryologic Basis for the Development and Anatomy of the Cavum Veli Interpositi

I read with interest the recent article by Chen et al entitled, ''Sonographic Characteristic of the Cavum Velum Interpositum'' (1). The regional anatomy of the cavum veli interpositi is complex and difficult to understand. I would like to point out the following anatomic information that is in variance with some of the statements made in the abovementioned publication.

The ependymal roof of the third ventricle is covered by a double layer of pia mater, the tela choroidea

Reprinted from Volume 20 Number 7 of the AJNR

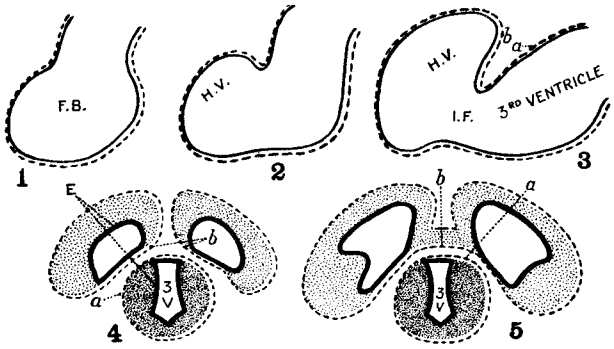

FIG. Diagram demonstrating the formation of the double-layered tela choroidea (velum interpositum) of the third ventricle in the human.

1) The developing neural tube includes the forebrain (FB) which is surrounded by the pia matter (broken line).

2) and 3) the expanding vesicle of the cerebral hemisphere (HV) carries its own pia mater (b) which overlaps the pia mater (a) of the third ventricle. IF signifies intraventricular foramen.

4) A double layer of pia mater (b, a) is interposed between the two cerebral vesicles and the third ventricle (3V). E signifies ependyma.

5) The two layers of pia mater (b, a) over the third ventricle persist after connection of the hemispheres by the commissures.

Permission for use of the figure was granted by T.H. Newton and Mosby-Year Book.

(2). The embryologic basis for this double-layered tela choroidea was outlined diagrammatically in 1932 by Frazer (3), modified by Brash (4), and reproduced in the neuroradiologic literature (5). It results from the overlapping of the third ventricle by the enlarging forebrain (Fig). During an early fetal stage, the prosencephalon and diencephalon are covered by a continuous layer of pia matter. With further brain development, the expanding cerebral vesicles of the forebrain, covered by its own pia mater, overlap the pia mater of the third ventricle, resulting in the double-layered tela choroidea (velum interpositum) of the roof of the third ventricle. The anterior aspect of the tela choiroidea, which is closed, is at the interventricular foramen where the pia mater folds on itself. When the posterior end remains open, the potential space between the double layers of the tela choroidea forms the cavum veli interpositi that communicates with the quadrigeminal cistern. The internal cerebral veins are located between the two layers of the cavum veli interpositi (2). Certain human embryologic changes are a ''recapitulation'' of evolutionary modifications. Therefore, examining the changing anatomy of various adult vertebrate brains facilitates understanding the overlapping of the third ventricle by the expanding human fetal cerebrum (5). In the shark's linear brain, the cerebrum is anterior to the diencephalon.

The entire roof of the diencephalon (third ventricle) is visible, and consists of a single layer of pia mater covered by a prominent venous plexus. In reptiles and primates, the expanding cerebrum overlaps the diencephalon, resulting in the double-layered tela choroidea of the third ventricle.

In summary:

• The velum interpositum is the double-layered tela choroidea of the third ventricle.

• The cavum veli interpositi is within the double-layered tela choroidea of the third ventricle, not superior to it.

• The internal cerebral veins are within the cavum veli interpositi, not inferior to it.

• The correct nomenclature is *velum interpositum* and *cavum veli interpositi*.

• Finally, a discussion of fluid-filled structures in the pineal region should include an enlarged suprapineal recess of the third ventricle. This recess may be quite large, and may extend posteriorly below the splenium (5, 6).

Leon E. Kier, M.D.
Yale University School of Medicine
New Haven, CT

References

1. Chen CY, Chen FH, Lee CC, Lee KW, Hsiao HS. **Sonographic characteristics of the cavum Velum Interpositum.** *AJNR Am J Neuroradiol* 1998;19:1631–1635
2. Williams PL, Warwick R, Dyson M, Bannister LH, ed. ***Gray's Anatomy.***37th ed. London: Churchill Livingstone; 1989:1019–1081
3. Frazer JE. ***A Manual of Embryology.***New York: William Wood; 1932
4. Brash JC, ***Cunningham's Textbook of Anatomy.***9th ed. New York: Oxford University Press; 1951
5. Kier EL. **The cerebral ventricles: a phylogentic and ontogentic study.**In Newton TH, Potts DG, eds. *Radiology of the Skull and Brain.* St. Louis: CV Mosby; 1977:2787–2914
6. Rosenbaum AE, Hawkins RL, Newton TH. **The third ventricle.**In: Newton TH, Potts DG, eds. *Radiology of the Skull and Brain.* St. Louis: CV Mosby; 1978:3398–3440

Reply

We would like to thank Dr. Kier for pointing out issues regarding the evolutionary and embryologic basis for the development and anatomy of cavum basis for the development and anatomy of cavum veli interpositi (CVI) in our recent article. First, we want to emphasize that we did use the term ''cavum veli interpositi'' in our original submission. During the peer review process, however, a referee opined that ''cavum veli interpositi'' is not an appropriate term. We agree with Dr. Kier that ''cavum veli interpositi'' is probably more appropriate than ''cavum velum interpositum'' (1, 2), which is rarely used in the literature. Relative to the issues of embryogenesis and formation of CVI and its related radiologic anatomy there are, to my knowledge, only a few published papers in the English-language literature (3, 4). The main point is whether the tela choroidea, by embryologic or anatomic definitions, includes the cisternal space of CVI at or near the term age of human brain development. According to Zellweger and van Epps (4), the tela choroidea of the third ventricle originates from the roof plate of the diencephalic region by a protrusion of a fold of pia mater into the primitive neural tube at about the third fetal month. With further development, the pia mater fold is pushed back-

ward, forming the final tela choroidea of the third ventricle. It encloses a horizontal sac or fissure under the fornix, which opens behind and under the splenium of the corpus callosum where its pia mater is connected to the pia mater covering the median fissure of the cerebrum. The sac-like pia fold carries the name ''transverse or choroidal fissure.'' In the majority of cases, the choroidal fissure closes. When it persists, the choroidal fissure is called ''CVI or cisterna interventricularis.'' CVI is a true cisternal structure communicating with the quadrigeminal cistern, as has been shown by comparing pneumoencephalography and autopsy specimens (3). Some investigators suggest that it is a part of the anterior extension of the quadrigeminal cistern. There is no doubt that the tela choroidea forms the roof of the third ventricle; the tela choroidea itself is, by definition, the structure where the pia and ependyma approximate. It contains, however, a pair of internal cerebral veins, so it is debatable whether the CVI and its roof (the hippocampal commissure) still can be included as parts of tela choroidea or part of the third ventricle as it relates to radiologic anatomy. In the published literature, the anatomic location of this cavum has been described frequently as above or superior to the third ventricle. The internal cerebral veins course within the tela choroidea on the roof of the third ventricle. Thus, anatomically, they are inferior or lateral to the CVI CSF space. Although our study did not aim to provide the embryologic evidence of the origin of the CVI, we reported that the color-coded internal cerebral veins on sonographic studies are anatomic landmarks to CVI. They are inferior or inferolateral to the CVI, but do not enter it. This raises a similar question as to whether the mega cisterna magna is a part of the fourth ventricle because it is now widely accepted that the mega cisterna magna is formed by the evagination of the tela choroidea of the fourth ventricle.

In summary, we believe:

• The velum interpositum originates from a fold of pia mater protrusion, which forms the final tela choroidea of the third ventricle.

• The cavum veli interpositi is a true cistern situated above (but not communicating with) the third ventricle.

• The internal cerebral veins form parts of the inferolateral or lateral boundaries of the CVI but are not anatomically within it.

• Both terms ''cavum veli interpositi'' and ''cavum velum interpositum'' have been used interchangeably in the English-language literature, and the former is more appropriate.

• An enlarged suprapineal recess of the third ventricle is a frequent finding in patients with obstructive hydrocephalus, but is extremely rare if ever seen as a normal variant in neonates and infants.

Cheng-Yu Chen, M.D.
Department of Radiology
National Defense Medical Center and
Tri-Service General Hospital
Taipei, Taiwan, Republic of China

References

1. Meller W, Tsai LY, Chiu LC. **Cavum velum interpositum in a boy with infantile autism.** *J Autism Dev Disord* 1985;15:109–111
2. Larroche JC, Baudey J. **Cavum septi lucidi, cavum vergae, cavum veli interpositi: cavites de la ligne mediane.** *Biol Neonat* 1961;3:193–236
3. Picard L, Leymarie F, et al. **Cavum veli interpositi. Roentgen anatomy: pathology and physiology.** *Neuroradiology* 1976;10:215–220
4. Zellweger H, Van Epps EF. **The cavum veli interpositi and its differentiation from cavum vergae.** *AJR Am J Roentgenol* 1958;82:22–25