



ASNR Career Center

The Go-To Job Site for Neuroradiology Employers and Job Seekers
Start here: careers.asnr.org

AJNR

Hypertensive Brain Stem Encephalopathy

Gregory Youngnam Chang and James R. Keane

AJNR Am J Neuroradiol 2000, 21 (7) 1366
<http://www.ajnr.org/content/21/7/1366>

This information is current as
of October 1, 2023.

Hypertensive Brain Stem Encephalopathy

We enjoyed reading the article by de Seze et al (1), in which they presented two cases of hypertensive encephalopathy with predominant brain stem involvement and discussed the differential diagnosis from brain stem tumors.

We have been interested in this subject and have published three similar cases (2). In all of our cases, the initial neuroradiologic interpretation was "massive brain stem infarction." Nonspecific symptoms, such as a mild headache and gait unsteadiness of several days, characterize hypertensive brain stem encephalopathy in contrast to in-

faction or tumor. We recently encountered a fourth case that again illustrates this entity.

A 55-year-old man had 1 week of mild headache and walking difficulty. His blood pressure (BP) was 250/145 mm Hg and his neurologic examination was normal. His CT scan was read as most consistent with an acute brain stem infarction. (Fig 1 [left]). Two weeks later, he felt well. His BP was 130/75 mm Hg and his MR results (Fig 1 [right]) showed resolution of brain stem swelling, without any signal changes in the brain stem.

Mild symptoms, a very high BP, and a normal neurologic examination conflict with scans in patients that dramatically confirm hypertensive brain stem encephalopathy. Marked clinicoradiologic dissociation rules out major brain stem infarction, and makes tumor unlikely.

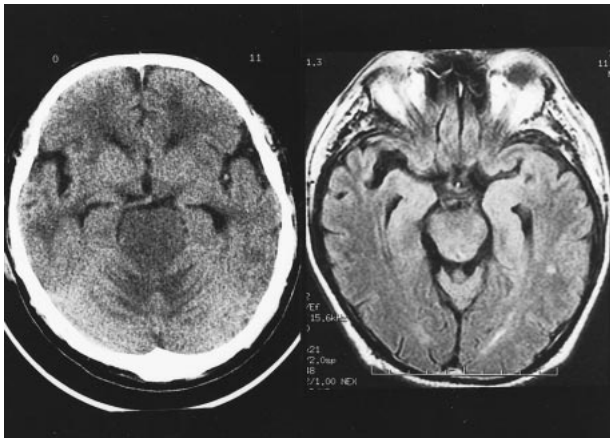


FIG 1. *Left*, Axial CT cuts show hypodense, swollen pons. Obliteration of upper fourth ventricle has resulted in enlarged temporal horns.

Right, Fluid-attenuated inversion recovery sequence at follow-up is normal. Imaging parameters 9000/128/2200 (TR/TE/T1). T2-weighted and diffusion-weighted images normal (not shown).

Gregory Youngnam Chang, M.D.
*Department of Neurology
University of Southern California
Los Angeles, CA*

James R. Keane, M.D.
*Department of Neurology
University of Southern California
Los Angeles, CA*

References

1. de Seze J, Mastain B, Stojkovic T et al. **Unusual MR Findings in the Brain Stem in Arterial Hypertension.** *AJNR Am J Neuroradiol* 2000;21:391-394
2. Chang GY, Keane JR. **Hypertensive brainstem encephalopathy: Three cases presenting with severe brainstem edema.** *Neurology* 1999;53:652-654