

The **next generation** GBCA
from Guerbet is here

Explore new possibilities >

Guerbet | 

© Guerbet 2024 GUOB220151-A

AJNR

Use of a Second Microcatheter in the Management of a Perforation during Endovascular Treatment of a Cerebral Aneurysm

Robert Willinsky and Karel terBrugge

AJNR Am J Neuroradiol 2000, 21 (8) 1537-1539

<http://www.ajnr.org/content/21/8/1537>

This information is current as
of February 27, 2024.

Use of a Second Microcatheter in the Management of a Perforation during Endovascular Treatment of a Cerebral Aneurysm

Robert Willinsky and Karel terBrugge

Summary: We describe the management of a perforation during endovascular treatment of a ruptured paraophthalmic aneurysm in a 53-year-old woman. The microcatheter and guidewire perforated the aneurysm during the initial catheterization. Using a second microcatheter, the aneurysm was packed with Guglielmi detachable coils while the first microcatheter was left in place. There were no adverse effects from the procedure, and the patient was discharged in good clinical condition.

Vascular perforations of the cerebral vessels during endovascular procedures may or may not result in disastrous consequences (1, 2). Recognition of the perforation has been facilitated by using biplane road-mapping techniques. Management of these perforations has included endovascular techniques using coils, liquid adhesives, balloons, and particles (1). This report highlights a simple technique to treat a perforation of a ruptured cerebral aneurysm caused by the initial placement of the microcatheter.

Case Report

A 53-year-old woman with hypertension presented with a subarachnoid hemorrhage. Her condition was categorized as Hunt and Hess grade 2 and Fisher grade 3 based on CT scans. Angiography showed a $7.9 \times 3.6 \times 3.5$ -mm paraophthalmic aneurysm, which was directed inferiorly and medially (Fig 1A-C). The neck of the aneurysm measured 3.5 mm.

On the day after the occurrence of bleeding, endovascular treatment was administered while the patient was under general anesthesia. Bilateral femoral artery sheaths were placed, because we planned to use a balloon-assisted technique. After full systemic heparinization, 7F and 6F guiding catheters were placed into the left internal carotid artery. A nondetachable 0.1-cc balloon catheter (Endeavor; Boston Scientific/Target, Fremont, CA) was navigated into the left internal carotid artery, just beyond the neck of the aneurysm, and was left deflated. With the aid of road mapping, we placed an Excel-14 microcatheter (Boston Scientific/Target) and Transend EX

0.014-in soft-tip guidewire (Boston Scientific/Target) into the paraclinoid internal carotid artery. With the guidewire in the aneurysm, we had some resistance delivering the microcatheter despite good curves on both. Because this resistance was overcome, the microcatheter and guidewire suddenly moved forward and perforated the dome, with the guidewire leading. The microcatheter was left in that position, and the heparin was reversed.

Angiography that was performed immediately thereafter failed to show any extravasation. The patient had a transient systemic hypertension lasting only seconds. The balloon catheter was removed and replaced with a second Excel-14 microcatheter and Transend EX 0.014-in soft-tip guidewire. Through the second microcatheter, we placed a Guglielmi detachable coil-10 2D, measuring $5 \text{ mm} \times 15 \text{ cm}$ (Boston Scientific/Target), into the aneurysm. Control angiography showed less filling of the aneurysm. Through the same microcatheter, we placed a soft stretch resistant (SR) Guglielmi detachable coil-10 measuring $4 \times 10 \text{ mm}$ into the aneurysm. Control angiography showed only minimal filling of the aneurysm. We attempted to place a soft SR Guglielmi detachable coil-10 measuring $2 \text{ mm} \times 8 \text{ cm}$, but this pushed the second microcatheter out of the aneurysm. The second microcatheter was removed, and control angiography showed that the aneurysm no longer filled (Fig 1D). An activated clotting time showed that the heparin had been completely reversed. We gave a bolus of 3000 units of heparin. Through the original microcatheter, we placed a soft SR Guglielmi detachable coil-10 measuring $2 \text{ mm} \times 8 \text{ cm}$ partly into the subarachnoid space before withdrawing the tip into the aneurysm and deploying the rest of the coil. This microcatheter was then also removed, and control angiography showed a small clot at the neck of the aneurysm with no filling of the aneurysm. We administered an additional bolus of 4000 units of heparin and repeated the control angiography in 20 minutes, which showed that the clot was smaller and that there were no distal emboli.

The patient was woken up, and her neurologic status was unchanged. Repeat CT showed no evidence of extravasation and no new subarachnoid blood. A heparin drip was continued for 16 hours, and then anticoagulation was stopped. Control angiography performed 4 days after treatment showed that the aneurysm remained closed (Fig 1E), and the results of a neurologic examination were normal.

Discussion

Aneurysm perforations during endovascular treatment are related to a number of mechanisms. Aneurysms can be perforated by the guidewire, the microcatheter, or a coil (2, 3). Rates of perforation vary from 2.0% to 4.4%, and the majority of perforations occur in small aneurysms, especially those that are smaller than 4 mm (2, 4, 5). Unlike for our patient, extravasation is revealed by angiography for most patients after aneurysm perforation.

Received December 22, 1999; accepted after revision February 25, 2000.

From the Department of Medical Imaging, The Toronto Western Hospital, University Health Network, University of Toronto, Toronto, Ontario, Canada.

Address reprint requests to Robert A. Willinsky, MD, Department of Medical Imaging, The Toronto Western Hospital, 399 Bathurst Street, Toronto, Ontario, M5T 2S8 Canada.

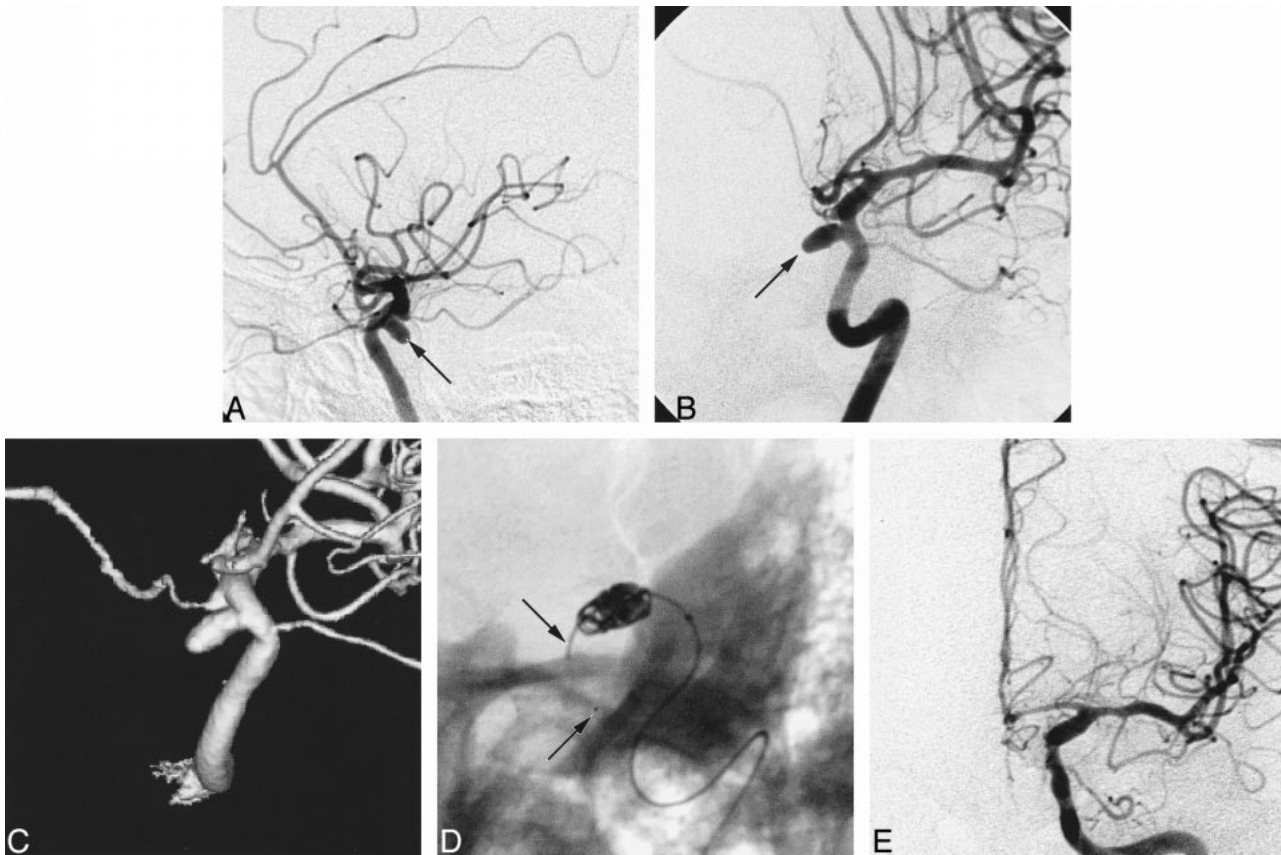


FIG 1. Angiograms obtained from a 53-year-old woman with hypertension, who presented with a subarachnoid hemorrhage.

A, Lateral view of the left internal carotid artery shows a paraophthalmic aneurysm (arrows) projecting medially and inferiorly.

B, Right, anterior, oblique view of the left internal carotid artery shows a paraophthalmic aneurysm (arrows) projecting medially and inferiorly.

C, Right, anterior, oblique view of the 3D reconstruction (LCN-Plus angio suite; General Electric, Milwaukee, WI) shows the neck of the aneurysm.

D, Right, anterior, oblique, scout view shows the Guglielmi detachable coils in the aneurysm and the original microcatheter (arrows) extending beyond the dome of the aneurysm. A guidewire within the microcatheter accounts for the radiopacity.

E, Anteroposterior view of the left internal carotid artery, obtained 4 days after treatment, shows that the aneurysm is occluded and the parent vessel is wide open.

tion, and patients often develop systemic hypertension because of the sudden rise in intracranial pressure (2, 4). These patients need prompt treatment, including reversal of the anticoagulation, medical support, and rapid packing of the aneurysm with Guglielmi detachable coils (2). For our patient, the perforation by the microcatheter was immediately recognized, prompting reversal of heparin and immediate angiography. Because the patient's cardiovascular status was stable and there was no extravasation revealed by angiography, we allowed the catheter to remain through the perforation. Using a second microcatheter, we occluded the aneurysm with Guglielmi detachable coils. With the aneurysm occluded, we could safely withdraw the original microcatheter, deploying a final coil to bridge the perforation site.

Perforation of an aneurysm by the guidewire should be managed differently from perforation by the microcatheter. Halbach et al (1) report a perforation of a vein of Galen malformation by a gui-

dewire. This was treated by advancing the microcatheter through the hole to deploy a bridging coil. We would be reluctant to do this in an aneurysm, because the perforation could become larger, and a bridging coil may not be sufficient to prevent extravasation. With a guidewire perforation, we would attempt to pack the aneurysm after removal of the guidewire quickly.

Perforations occurring during a balloon-assisted procedure can be managed with the help of balloon inflation, which occludes the parent vessel during the subsequent packing of the aneurysm (3). We considered this in our patient's case, but the small-sized balloon we had in place would not likely seal the aneurysm or close the parent vessel. We chose a second microcatheter instead of a larger balloon because we saw no extravasation, and because packing of the aneurysm could be achieved without removing our original microcatheter. We were concerned that balloon occlusion after heparin reversal would carry a signifi-

cant risk of thromboembolism. In addition, the balloon-assisted technique can interfere with the smooth delivery of coils by hindering the to-and-fro motion of the catheter tip (3).

After aneurysm rupture, there is an acute rise in intracranial pressure, resulting in a reduction of cerebral flow and a secondary rise in systemic arterial pressure (4). Ricolfi et al (4) propose emergency ventriculostomy in the angiography suite for cases in which the patient remains hypertensive. They report a good outcome after perforation of an aneurysm that resulted in persistent systemic hypertension, which was treated with ventriculostomy 15 minutes after the event.

In summary, in a stable patient, use of a second microcatheter to occlude a perforated aneurysm allows the endovascular therapist to leave the original microcatheter in place.

References

1. Halbach VV, Higashida RT, Dowd CF, Barnwell SL, Heishima GB. **Management of vascular perforations that occur during neurointerventional procedures.** *AJNR Am J Neuroradiol* 1999; 12:319–327
2. McDougall CG, Halbach VV, Dowd CF, Higashida RT, Larsen DW, Heishima GB. **Causes and management of aneurysmal hemorrhage occurring during embolization with Guglielmi detachable coils.** *J Neurosurg* 1998;89:87–92
3. Phatouros CC, Halbach VV, Malek AM, Dowd CF, Higashida RT. **Simultaneous subarachnoid hemorrhage and carotid cavernous fistula after rupture of a paraclinoid aneurysm during balloon-assisted coil.** *AJNR Am J Neuroradiol* 1999;20:1100–1102
4. Ricolfi F, Le Guerinel C, Blustajin J, et al. **Rupture during treatment of recently ruptured aneurysms with Guglielmi electro-detachable coils.** *AJNR Am J Neuroradiol* 1998;19:1653–1658
5. Viñuela F, Duckwiler G, Mawad M. **Guglielmi detachable coil embolization of acute intracranial aneurysm: perioperative anatomical and clinical outcome in 403 patients.** *J Neurosurg* 1999;86:475–482