

Generic Contrast Agents

Our portfolio is growing to serve you better. Now you have a *choice*.



FRESENIUS
KABI

[VIEW CATALOG](#)

AJNR

Accessory Salivary Tissue in the Mylohyoid Boutonnière: A Clinical and Radiologic Pseudolesion of the Oral Cavity

David K. White, H. Christian Davidson, H. Ric Harnsberger,
Jeffrey Haller and Aya Kamya

This information is current as
of May 10, 2025.

AJNR Am J Neuroradiol 2001, 22 (2) 406-412
<http://www.ajnr.org/content/22/2/406>

Accessory Salivary Tissue in the Mylohyoid Boutonnière: A Clinical and Radiologic Pseudolesion of the Oral Cavity

David K. White, H. Christian Davidson, H. Ric Harnsberger, Jeffrey Haller, and Aya Kamya

BACKGROUND AND PURPOSE: Though classically depicted as a continuous muscular barrier between the sublingual and submandibular spaces, the mylohyoid muscle is often discontinuous. These areas of discontinuity may contain fat, blood vessels, salivary tissue, or combinations thereof that may be mistaken both clinically and radiologically for pathologic abnormalities. We sought to demonstrate the prevalence and radiologic appearance of dehiscence of the mylohyoid muscle.

METHODS: One hundred axial, contrast-enhanced CT studies of the neck, obtained over a 10-month period, were retrospectively reviewed. Inclusion criteria included 3-mm-thick slices and absence of pathologic abnormalities or surgical changes in the oral cavity. Scans were assessed for the presence and contents of mylohyoid defects such as accessory salivary tissue, defined as nonlymphoid tissue within defects in the mylohyoid, having attenuation and enhancement characteristics similar to those of orthotopic sublingual and submandibular salivary tissue.

RESULTS: Mylohyoid defects were identified in 77 of 100 individuals. The deficiencies were bilateral in 67% and unilateral in 33%. Accessory salivary tissue was identified in 37 of 100. Fat and blood vessels were commonly identified within the mylohyoid defects. Sixty-one percent of the defects contained only fat. Thirty-five percent of the defects contained blood vessels.

CONCLUSION: Deficiencies in the mylohyoid muscle were visible in 77% of individuals who underwent scanning. The defects may contain fat, blood vessels, salivary tissue, or all three characteristics. Accessory salivary tissue was identified in 37% of individuals who underwent scanning. Recognition of mylohyoid deficiencies and the typical appearance of accessory salivary tissue will allow accurate diagnosis of this benign, anatomic variant.

The mylohyoid muscle forms the muscular floor of the oral cavity. It is a thin, flat muscle that forms a sling inferior to the tongue. It inserts on the slightly obliquely oriented mylohyoid line on the medial surface of the mandible, with the posterior aspect more cranial than the anterior aspect. The muscle is thickest posteriorly, and thins as it approaches the mental tubercle (1, 2).

The oral cavity consists of two major spaces and the oral cavity mucosa: the sublingual and the submandibular space (3). The mylohyoid muscle forms

the floor of the mouth, supporting the tongue and defining the boundary between the submandibular and sublingual space (Fig 1). The mylohyoid muscle consists of anterior and posterior halves divided into right and left muscle bellies. The posterior portions insert onto the body of the hyoid bone. The middle and anterior fibers insert into the fibrous median raphe that runs from the mandibular symphysis to the hyoid bone. The sublingual space is a horizontally oriented, horseshoe-shaped area that sits in the oral cavity between the mylohyoid muscle inferolaterally and the genioglossus-geniohyoid complex medially. The sublingual space contains the sublingual salivary glands, the submandibular duct, and posteriorly, the deep portion of the submandibular glands (3, 4). The submandibular space is encased by the superficial layer of the deep cervical fascia and is a vertically oriented, horseshoe-shaped area that is inferolateral to the mylohyoid muscle and superior to the hyoid bone. It contains the superficial portion of the submandibular glands (3, 5).

Received October 15, 1999; accepted after revision June 12, 2000.

Abstract presented at the combined ASHNR/ASNR meeting in San Diego, CA, 1999.

From the Department of Radiology, University of Utah, Salt Lake City, UT.

Address reprint requests to David K. White, MD, University of Utah HSC, Department of Radiology (Neuroradiology Section), 50 N Medical Dr, Salt Lake City, UT 84132.

© American Society of Neuroradiology

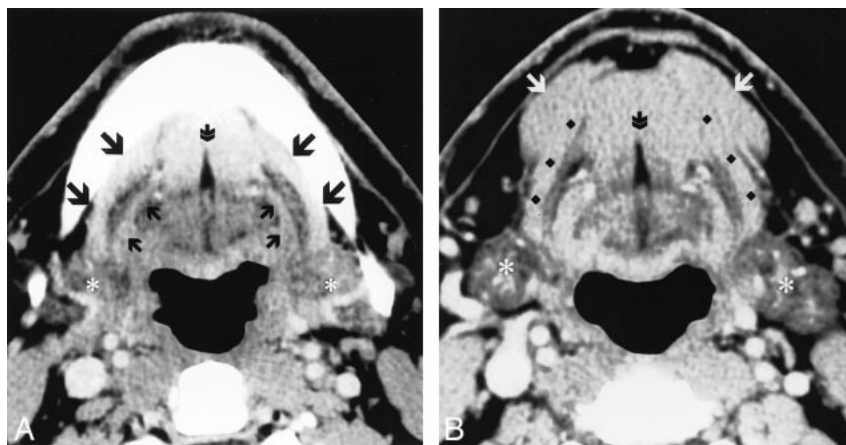


FIG 1. Normal postcontrast axial CT images through the oral cavity. *B* is caudal to image *A*. The classic anatomy of the mylohyoid muscle (*A*, large black arrows; *B*, black diamonds) is seen forming a continuous muscular barrier separating the deep sublingual space from the superficial SMS. Running parallel to the posterior aspect of the mylohyoid muscle is the hyoglossus muscle (small black arrows). On either side of the fibro-fatty lingual septum (double arrow) are the genioglossus muscles cranially, and the geniohyoid muscles caudally. Caudally, the anterior belly of the digastric muscle (white arrows) blends with the superficial margin of the mylohyoid muscle. Asterisks signify the submandibular glands (18).

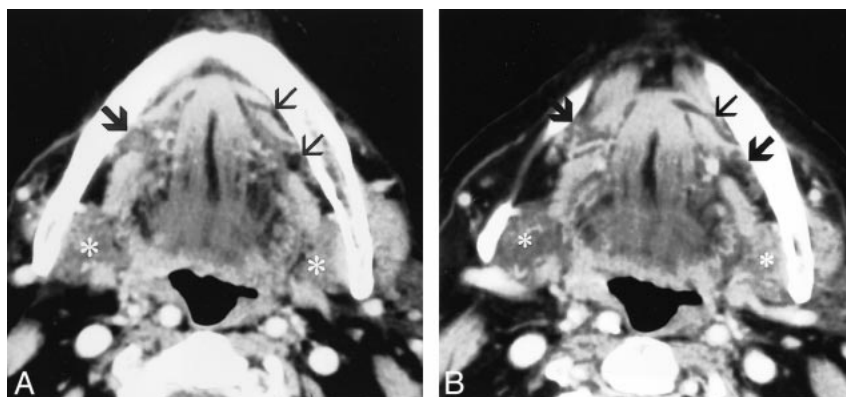


FIG 2. Postcontrast axial CT images through the oral cavity showing multiple mylohyoid muscle defects. Image *A* is cranial to image *B*. On the patients left side, there are two mylohyoid muscle defects. On the right, there is one defect. Accessory salivary tissue is identified bilaterally (large arrows). Note that the accessory salivary tissue has the same attenuation as that of the normal submandibular glands (*). *A*, large arrow, accessory salivary tissue; small arrows, fat-containing defects. *B*, large arrows, accessory salivary tissue; small arrow, fat-containing defect (18).

The mylohyoid muscle is classically thought of and depicted as a continuous muscular barrier between the sublingual and submandibular spaces (1, 2, 5, 6). The muscle, in fact, is often discontinuous. Anatomic and surgical literature have demonstrated that the defects may contain sublingual or submandibular salivary tissue, fat, blood vessels, or all three components (7–10). Gaughran (7) reported observations from dissection of 324 half-heads from 162 cadavers. Based on earlier works, he refers to the mylohyoid deficiencies as *boutonnieres* and the projection of salivary tissue through these defects as sublingual *boutons*. He observed deficiencies containing salivary tissue in 32% and containing only fat in 5%. Nathan and Luchansky's (9) dissection of 150 dissecting room cadavers found mylohyoid deficiencies in 42%. These were bilateral in 11%. Castelli and colleagues (8) found defects in only 10% of the forty specimens they stud-

ied. In a gross and histologic study of 100 adult cadavers, Engel et al (10) found a "mass" containing mylohyoid *boutonnieres* in 45% of patients. The defects ranged in size from "a few millimeters to about 15 mm in maximal diameter." The defects contained salivary tissue in 92%, purely adipose tissue in 6%, and epidermoid tissue in one (2%). Histologically, 52% of the salivary tissue within the defects was of the sublingual type (predominately mucous salivary tissue) and 48% was of the submandibular type (serous-mucous with serous predominance). Inflammatory changes were seen in 73% of the salivary tissue specimens.

It has been well described that pathologic abnormalities in the sublingual space may spread directly through the mylohyoid muscle into the submandibular space (7, 8, 11–14). In addition, "masses" of accessory salivary tissue in the mylohyoid *boutonniere* may present as a palpable ab-

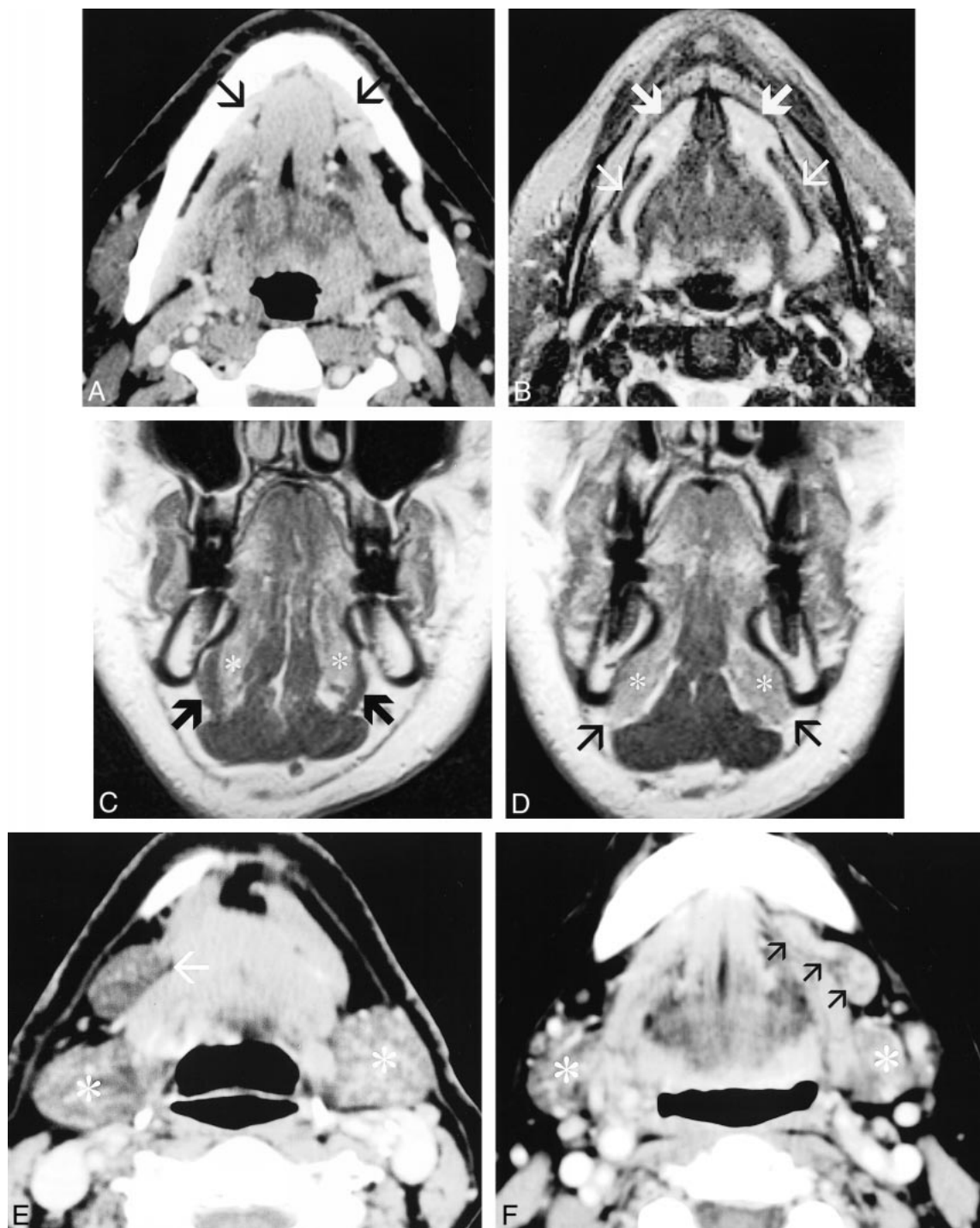


FIG 3. Accessory salivary tissue has a variable appearance and location in the oral cavity. General features include tissue that is associated with mylohyoid defects and is of similar attenuation and appearance as orthotopic salivary tissue.

A–D, CT and MR correlation in the same patient with anterior accessory salivary tissue. A, Postcontrast axial CT scan. B, Axial fast spin-echo fat-saturated T2-weighted image. C and D, Postcontrast coronal T1-weighted image. Image C is posterior to image D. The postcontrast CT scan shows enhancing tissue that extends into the submandibular space through deficiencies in the anterior mylohyoid muscle bilaterally (small black arrows). The deficient mylohyoid muscle is clearly identified on the fat-saturated T2-weighted sequence (small white arrows). The normal hyperintense sublingual salivary tissue is clearly identified, extending into the submandibular space anteriorly (large white arrows). The coronal sequences are very useful for identifying the mylohyoid muscle. C depicts the intact mylohyoid muscle (large black arrows) separating the sublingual space and sublingual salivary tissue (*) from the submandibular space. D is located more anteriorly at the level of the mylohyoid defects. Notice the absence of the mylohyoid muscle at this level allows extension of the sublingual salivary tissue into the submandibular space (small black arrows).

E, Postcontrast CT shows a large deposit of salivary tissue that is located predominately in the submandibular space, with a tapering configuration toward a mid-mylohyoid defect (single arrow). The attenuation and appearance is very similar to the normal submandibular glands (*).

normality clinically, or as an enhancing mass radiologically (7–10, 14–16). The goal of our study was to demonstrate the prevalence and contents of radiologically detectable defects of the mylohyoid muscle.

Methods

CT scans obtained from 100 individuals imaged from May 1998 to March 1999 were retrospectively reviewed by two board-certified radiologists. All scans were performed on third-generation CT scanners in helical mode after IV administration of contrast medium, and consisted of 3-mm-thick axial slices through the oral cavity. Inclusion criteria were absence of surgical changes and tissue-altering pathologic abnormality in the oral cavity. Additionally, scans with treatment-related changes of the oral cavity, including radiation therapy, were excluded.

The oral cavity structures were evaluated in detail. The mylohyoid muscles were identified bilaterally and evaluated for the presence of defects. A defect was defined as a discrete area of discontinuity of the mylohyoid muscle being equal to or greater than 1 mm thick in the anteroposterior dimension and visible on one or more slices. Identified defects were categorized as right, left, or bilateral.

The contents of defects were identified. These included fat, blood vessels, and accessory salivary tissue. Accessory salivary tissue is defined as tissue of similar attenuation and enhancement characteristics on CT scans as those of orthotopic salivary tissue, positioned adjacent to, within, or traversing defects of the mylohyoid muscle. Tissue less than 2 mm thick was deemed nonspecific and was not identified as salivary in origin. Blood vessels were identified as discrete, brightly enhancing curvilinear structures, and lymph nodes were identified by their characteristic shape and attenuation.

Blood vessels traversing the mylohyoid muscle without discrete defects were identified. These were documented as right, left, or bilateral.

Results

Deficiencies in the mylohyoid muscle were identified in 77 of 100 individuals who underwent CT scanning. The other 23 did not manifest radiologically detectable defects (Table). Multiple defects on the same side were occasionally encountered (Fig 2 [page 407]). Large defects may have contained a blood vessel on one slice and only fat on another and were documented as containing both fat and blood vessels. A total of 83 defects were identified in the 77 individuals. These included 56 (67%) bilateral defects, 14 (17%) right-sided defects, and 13 (16%) left-sided defects.

Accessory salivary tissue was identified in 37 of the 100 individuals examined. These were bilateral in 17 (46%), right-sided in 12 (32%) and left-sided in 8 (22%) (Table) (Fig 3).

Fat was identified in 51 (61%) of the 83 defects. These were bilateral in 25 (49%), right-sided in 11 (22%), and left-sided in 15 (29%) (Fig 4). Blood

One hundred individuals scanned

Defects*	77/100		
AST†	37/100	Bilateral	17 (46%)
		Right	12 (32%)
		Left	8 (22%)

* Number of individuals with mylohyoid defects.

† Accessory salivary tissue.

vessels were identified within 35 (42%) of the 83 defects. These were bilateral in 15 (43%), right-sided in 12 (34%), and left-sided in 8 (23%) (Fig 4).

Blood vessels perforating the mylohyoid muscle, without an identifiable defect in 22 of the 100 individuals examined, were identified. These were bilateral in seven (32%), right-sided in 10 (45%), and left-sided in five (22%) (Fig 4).

Figure 5 illustrates the appearance of mylohyoid defects containing accessory salivary tissue and perforating submental branches of the facial artery and vein.

Discussion

Modern imaging of the head and neck has benefited greatly from advances in imaging technology and techniques. Normal anatomic structures are depicted in greater detail than was previously possible. In the oral cavity, normal variations in anatomic structure can be observed that confound the imaging staging of squamous cell carcinoma and the imaging evaluation of other mass lesions. This study was initiated to investigate the prevalence of these normal anatomic variants, with specific focus on the radiologic appearance of mylohyoid defects and associated accessory salivary tissue.

Mylohyoid boutonnières are common; radiologically detectable deficiencies in the muscle were identified in three of four individuals who underwent scanning in this study. This is similar to Gaughrans' (7) dissection of 162 cadavers in which he identified fat or tissue-containing defects in 72% of specimens examined. Most defects are less than 5 mm; however, occasionally they may be larger than 2 cm. The defects in our study were bilateral in two thirds of those examined, and unilateral in one third. The most common content was fat, followed by blood vessels, and then accessory salivary tissue. Defects tended to be identified along the lateral margins of the mylohyoid muscle, closer to the mandible and away from the median raphe. Defects were not visible in the thicker, posterior third of the muscle.

FIG. 3 (Continued)

F, Postcontrast CT shows accessory salivary tissue, which spans a defect in the mid aspect of the mylohyoid muscle. The tissue is well defined, elongated in configuration, and located in both the sublingual and submandibular space. The attenuation and appearance is very similar to that of the normal submandibular gland (*) (18).

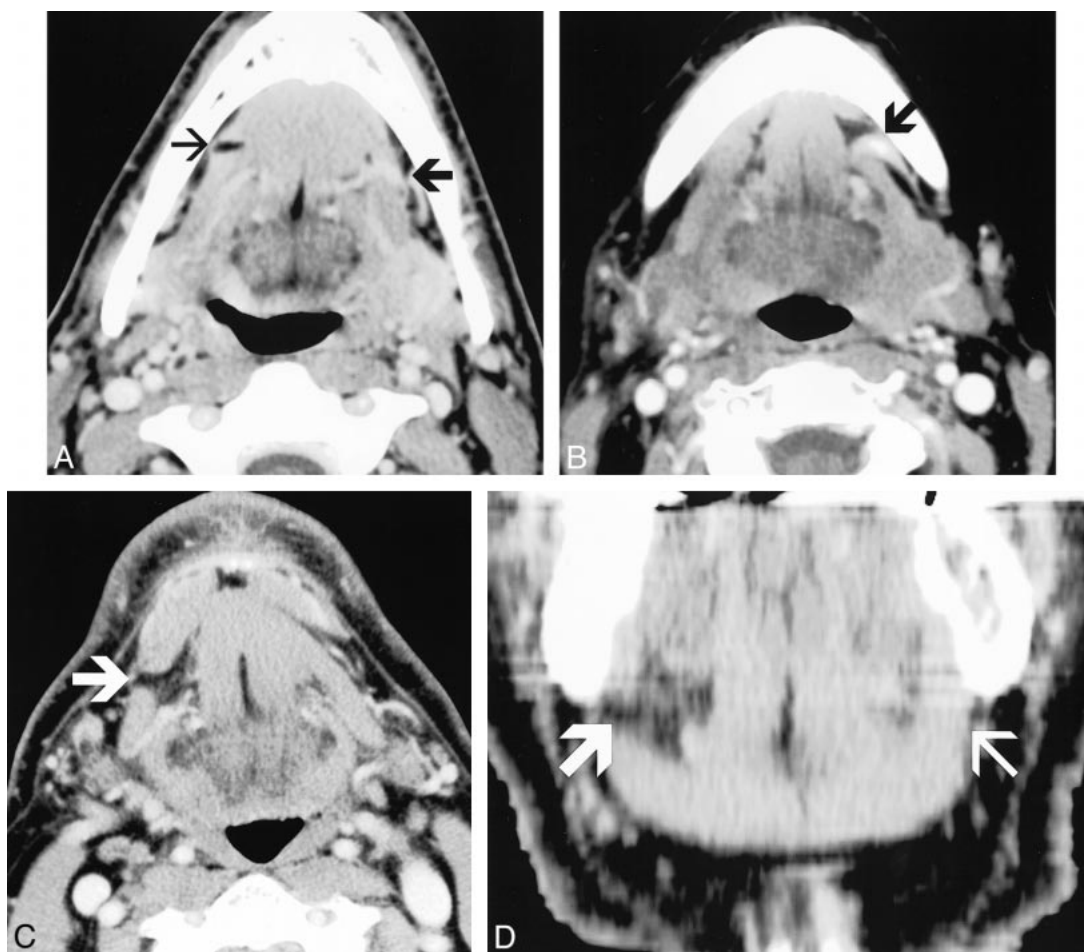


FIG 4. The most common contents of mylohyoid defects are fat, followed by blood vessels. Fat-containing defects are seen as discrete areas of discontinuity in the mylohyoid muscle, containing low-density adipose tissue. Blood vessels may be identified passing through discrete mylohyoid defects or may be seen perforating the mylohyoid muscle, without an identifiable defect.

A and B, Postcontrast CT images in different patients. A, On the patient's right side, there is a discrete, wedge-shaped defect in the mid-to-anterior aspect of the mylohyoid muscle (*small arrow*). On the patient's left side, there is a blood vessel perforating the mylohyoid muscle, without an associated defect (*large arrow*). B, On the patient's left side, there is a large defect in the anterior half of the mylohyoid muscle, containing both fat and a large blood vessel (*arrow*).

C and D, CT and coronal CT reformation correlation in the same patient. C is a postcontrast axial CT scan, and D is a coronal, reformatted CT image. These images show a discrete, fat-containing defect in the mid mylohyoid muscle (*large arrow*). On the coronal image, the *small arrow* on the patient's left side identifies the intact mylohyoid muscle for comparison (18).

Accessory salivary tissue was identified in 37% of the individuals in this study. This is similar to the cadaver dissection results of Nathan and Luchansky (9) and Engel et al (10) in which they identified accessory salivary tissue in 40% and 42%, respectively (9, 10). Accessory salivary tissue in this study was bilateral almost half the time. Additionally, similar to the reports of Gaughran (7) and Engel et al (10), accessory salivary tissue was identified within, or adjacent to, mylohyoid defects within the anterior two thirds of the muscle.

A brief discussion of the embryology of the oral cavity provides insight into the development of mylohyoid boutonnières and accessory salivary tissue. The mylohyoid muscle forms the muscular floor of the mouth, and though classically depicted as a single, continuous, muscular sling, the primate mylohyoid muscle is composed of separate anterior and

posterior halves (16). The usual primate anatomic relationship between the anterior and posterior mylohyoid parts shows the anterior part more superficial to the posterior part, with some degree of overlap usually present. The degree of overlap is variable, with a distinct "defect" seen if overlap does not occur. Submental branches of the facial artery and vein may traverse such a defect, and salivary tissue may herniate through it.

Embryologically, the mesenchyma of the developing mylohyoid muscle differentiates in close proximity to the developing and proliferating sublingual salivary tissue. As a consequence, islets of salivary tissue may occur, and have been described in the fascia of the mylohyoid muscle (14). The variability of occurrence and size of these islets may influence the differentiation of the adjacent skeletal muscle. The common association of sali-

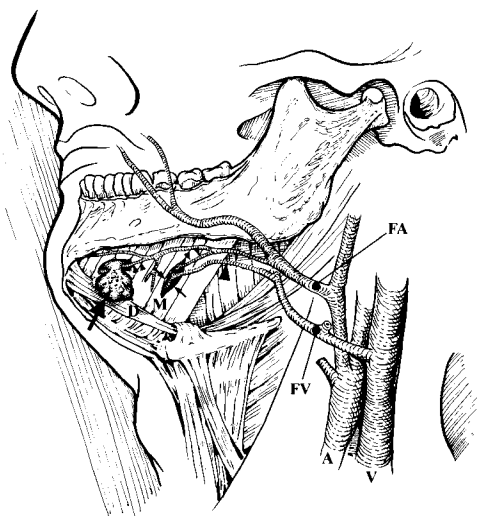


FIG 5. This line drawing illustrates the superficial anatomy of the submandibular space with mylohyoid defects containing accessory salivary tissue and perforating submental branches of the facial artery and vein.

Large arrow, Accessory salivary tissue; *small arrow*, mylohyoid defects; *large arrowhead*, submental branch of facial vein; *small arrowhead*, submental branch of facial artery; *D*, anterior belly of digastric muscle; *M*, mylohyoid muscle; *FA*, facial artery off the external carotid artery; *FV*, facial vein; *A*, common carotid artery; *V*, internal jugular vein (18).

vary tissue with defects in the mylohyoid muscle reflects the variability of the embryologic development of the floor of the mouth.

Accessory salivary tissue ranges in size from a few millimeters to a few centimeters. In our experience, accessory salivary tissue may measure as large as 3 cm in diameter. It is these larger deposits of tissue that may be confused both clinically and radiologically for pathologic abnormality. Larger accessory salivary tissue may be noted on clinical examination and misinterpreted as pathologically abnormal. Although fine-needle aspiration is often useful for the evaluation of head and neck masses, salivary tissue can be difficult to interpret, rendering this diagnostic technique less reliable in this context. Therefore, proper imaging and notation of the accessory salivary tissue are critical to prevent an unnecessary surgical exploration of the region. Recognizing the usual imaging features of accessory salivary tissue allows one to differentiate this benign variant from a pathologic process. Accessory salivary tissue typically manifests attenuation on CT scans that is the same, or slightly higher, than that of orthotopic salivary tissue. The slightly higher attenuation occasionally encountered may reflect increased enhancement related to inflammatory changes, as reported in 73% of specimens by Engel et al (10).

All of the cases of accessory salivary tissue we identified were adjacent to, within, or traversing defects in the mylohyoid muscle. Accessory salivary tissue located adjacent to mylohyoid boutonnières characteristically tapers toward the defect, approximating the outer surface of the deficiency. This

results in the absence of a fatty tissue plane between the accessory salivary tissue and the boutonnière. By contrast, lymph nodes are characteristically round or oval. Benign nodes maintain a central, low-density, fatty hilum. In the pathologic state, the hilar fat may be replaced with abnormally soft tissue, and the node may increase in density. In addition, lymph nodes will lack the tapering configuration and will maintain a fatty plane between the mylohyoid muscle. No lymphoid tissue was identified within or traversing defects. The absence of an adjacent mylohyoid defect virtually excludes the possibility of accessory salivary tissue.

Engel et al (10) have described the histologic characteristics of accessory salivary tissue. They reported a nearly equal incidence between both sublingual (mucous-type salivary gland tissue) and submandibular histologic findings (mucous-serous with serous predominance). We have observed two variants of accessory salivary tissue. The first is well-defined, encapsulated tissue that tends to be more commonly identified within or adjacent to boutonnières in the mid aspect of the muscle. The second variant is tissue that is more loosely organized, generally smaller, and located more anteriorly. Whether the more posteriorly encapsulated tissue corresponds to submandibular histologic findings and the more loosely organized anterior tissue represents the sublingual histologic findings will require future radiologic-pathologic correlation.

With an understanding of its usual location and typical appearance, accessory salivary tissue is generally easily identified. Tissue smaller than 2 mm is sufficiently nonspecific and difficult to characterize as salivary in origin. With CT imaging, detection of anterior defects and accessory tissue may be difficult because of beam hardening through the mandibular symphysis. This concept is illustrated in Figure 3, with CT and MR correlation of an anterior mylohyoid defect. In addition, the anterior belly of the digastric muscle may totally or partially cover anterior mylohyoid defects, limiting detection by CT (10). Because the detection of very anterior boutonnières is limited on CT, the incidence of accessory salivary tissue may in fact be higher than that reported in this study. In the cadaver dissection study by Gaughran (7), Accessory salivary tissue was identified in 63% of cadavers.

Fat was the most common tissue identified within mylohyoid boutonnières, seen as a major component in 61% of the defects. One half of these defects were bilateral, with the rest split roughly evenly between right and left. These results differ from the anatomic surgical-pathologic reports. Gaughran (7) identified defects containing only fat in 4.6% of half-heads (10% of cadavers). Engel et al (10) reported one case (1.6%) of fat-only defects. Nathan and Luchansky (9) identified a "few cases" of fat-only defects, with most defects containing both fat and accessory salivary tissue. CT's sensi-

tivity in detecting fat and small (1-mm) defects with thin-section imaging techniques may account, in part, for this discrepancy, because very small defects may be overlooked at dissection or not considered significant. Additionally, some of the defects in our study contained small amounts of non-specific tissue, which we classified as fat-only defects, but that might have been found to be salivary tissue at dissection.

Blood vessels were commonly identified traversing the mylohyoid muscle, both within and without identifiable defects. Blood vessels were identified in 42% of the defects. Penetrating blood vessels without defects were identified in 22% of individuals. These blood vessels represent branches of submental arteries and veins that arise from the facial artery and vein off the external carotid and venous systems (2, 7–9, 17). Considering that during embryogenesis the developing sublingual salivary tissue may influence mylohyoid development, it is possible that variations in angiogenesis during mesenchymal differentiation may account for development of some mylohyoid boutonnières. As reported by Engel et al (10), these penetrating vessels do not appear to predispose to the development of accessory salivary tissue, but may be seen passing through defects with or without associated salivary tissue, or penetrating the mylohyoid muscle with no detectable defects.

Conclusion

Defects in the mylohyoid muscle are common. Accessory salivary tissue associated with deficiencies of the mylohyoid muscle is commonly identified. Large deposits of accessory salivary tissue are occasionally seen. Recognition of mylohyoid deficiencies and the typical radiologic appearance

of accessory salivary tissue will allow accurate diagnosis of this benign anatomic variant.

References

1. Vidic B, Melloni BJ. **Applied anatomy of the oral cavity and related structures.** *Otolaryngol Clin North Am* 1979;12:3–14
2. Moore KL. **Clinically Oriented Anatomy.** 2nd ed. Baltimore: Williams & Wilkins;1985
3. Harnsberger HR. **Handbook of Head and Neck Imaging.** 2nd ed. St Louis: Mosby;1995
4. Sumi M, Izumi M, Yonetsu K, Nakamura T. **Sublingual gland: MR features of normal and diseased states.** *AJR Am J Roentgenol.* 1999;172:717–722
5. Som PM, Curtin HD. **Head and Neck Imaging.** 3rd ed. St. Louis: Mosby;1996
6. Netter FH. **Atlas of Human Anatomy** Summit, NJ: CIBA-GEIGY Corp.;1989
7. Gaughran GR. **Mylohyoid boutonnière and sublingual bouton.** *J Anat* 1963;97:565–568
8. Castelli WA, Huelke DF, Celis A. **Some basic anatomic features in paralingual space surgery.** *Oral Surg Oral Med Oral Pathol.* 1969;27:613–621
9. Nathan H, Luchansky E. **Sublingual gland herniation through the mylohyoid muscle.** *Oral Surg Oral Med Oral Pathol.* 1985; 59:21–23
10. Engel JD, Harn SD, Cohen DM. **Mylohyoid herniation: gross and histologic evaluation with clinical correlation.** *Oral Surg Oral Med Oral Pathol.* 1987;63:55–59
11. Mair IW, Schewitsch I, Svendsen E, Haugeto OK. **Cervical ranula.** *J Laryngol Otol* 1979;93:623–628
12. Ichimura K, Ohta Y, Tayama N. **Surgical management of the plunging ranula: a review of seven cases.** *J Laryngol Otol* 1996; 110:554–556
13. Takimoto T, Masuda K, Nakai Y. **Cervical ranula arising from a projection of the sublingual gland through the mylohyoid muscle.** *J Oral Maxillofac Surg* 1989;47:1197–1198
14. Schneider W, Fulgenzi A, Lupovitch A. **Submental herniation of sublingual gland: report of case.** *J Oral Surg* 1972;30:824–826
15. Jafek BW, Strife JL. **Accessory lobe of the submandibular gland.** *Radiology.* 1973;109:75–77
16. Moss-Salentijn L, Hendricks-Klyvert M. **A bilateral, superficial location of human sublingual glands: report of a case.** *J Oral Maxillofac Surg* 1987;45:983–986
17. Faltaous AA, Yetman RJ. **The submental artery flap: an anatomic study.** *Plast Reconstr Surg* 1996;97:56–60; Discussion 61–62
18. White DK HH. **Digital Teaching File.** Salt Lake City: Electronic Medical Education Resource Group;1999