Are your MRI contrast agents cost-effective?
Learn more about generic Gadolinium-Based Contrast Agents.
FRESENIUS KABI
caring for life

AJNR

An Unusual Spinal Presentation of Whipple Disease

Anna Messori, Paolo Di Bella, Gabriele Polonara, Francesco Logullo, Paola Pauri, Ramazan Haghighipour and Ugo Salvolini

AJNR Am J Neuroradiol 2001, 22 (5) 1004-1008
http://www.ajnr.org/content/22/5/1004

This information is current as of April 23, 2024.

AJNR Am J Neuroradiol 22:1004–1008, May 2001

Case Report

An Unusual Spinal Presentation of Whipple Disease

Anna Messori, Paolo Di Bella, Gabriele Polonara, Francesco Logullo, Paola Pauri, Ramazan Haghighipour, and Ugo Salvolini

Summary: When Whipple disease (WD) is confined to the CNS, diagnosis may be difficult. We report a case of WD with spinal presentation in an otherwise healthy woman who had a 5-year history of relapsing-remitting cervico-thoracic myelopathy. We suggest that the diagnosis of WD should be considered in the presence of an enlarged and enhancing spinal cord even in the absence of any systemic involvement.

Whipple disease (WD), first described in 1907 (1), was originally known as a gastrointestinal disease, but has come to be recognized as a multisystem chronic and relapsing infection. It usually affects the small intestine and mesenteric lymph nodes first, causing abdominal pain, impaired intestinal absorption, diarrhea, weight loss, generalized lymphadenopathy, and fever. The joints, heart, and CNS can be involved, generally following gastrointestinal presentation by months or years, despite long-term antibiotic drug administration. CNS involvement is reported in up to 43% of cases (2–4). Even rarer cases (fewer than 5%) present as primary CNS disease (5–9). In the CNS, WD lesions most frequently involve the periaqueductal gray matter, thalamus, hypothalamus, hippocampus, cingulate gyrus, basal ganglia, and cerebellum. Clinical symptomatology frequently includes progressive dementia, supranuclear ophthalmoplegia, hypothalamic disorders, and gait unsteadiness, ending in an akinetic state and eventual coma over a period of months to years (2, 3, 7–10). Oculofacial-skeletal myorhythmia, a convergent/divergent pendular nystagmus associated with synchronous movements of the mouth, masticatory muscles, and other body parts, is considered pathognomonic of the disease (3, 11).

CNS WD lesions confined to the spinal cord are quite exceptional: to our knowledge, only one case has been reported to date (12). We describe the clinical and imaging course of a patient lacking both gastrointestinal and other symptomatology, whose remitting-relapsing cervico-thoracic myelopathy was misdiagnosed over years. Subsequent intracranial extension of lesions, and additional currently available tests that provide more complete information, finally led to correct diagnosis and proper treatment.

Received August 7, 2001; accepted after revision October 9.

From the Departments of Neuroradiology (A.M., G.P., U.S.), Neurology (P.D.B., F.L., R.H.), and Microbiology (P.P.), University of Ancona, Italy.

Address reprint requests to Prof. Ugo Salvolini, Cattedra di Neuroradiologia, Facoltà di Medicina, Università degli Studi di Ancona Polo Ospedaliero-Universitario Torrette di Ancona, via Conca 16, 60020 Ancona, Italy.

© American Society of Neuroradiology

Case Report

In August 1994, a 65-year-old woman presented with a 2-month history of upper and lower limb paresthesias and 1-week paraparesis and sphincter dysfunction. On clinical examination, sensory motor myelopathy with an upper cervical level was confirmed. Spinal MR imaging revealed that the cord was enlarged and inhomogeneously hypointense on T1-weighted images and hyperintense on T2-weighted images from the cervico-occipital level to the upper dorsal region (Fig 1A), and a slight peripheral enhancement was detected after gadopentate dimeglumine administration (Fig 1B). Brain MR imaging findings were normal. An infiltrating spinal cord lesion was first suspected. Repeat examination after 7 days of corticosteroid therapy showed a slight reduction of spinal cord enlargement (Fig 1C).

The patient's clinical condition gradually improved under corticosteroid therapy, and 8 months later MR imaging findings of the cord were normal (Fig 1D). At this stage, a vascular insult seemed most likely. In November 1995, she presented again with sensory abnormalities and sphincter dysfunction, despite paraparesis reduction. MR imaging again showed enlarged distal cervical and dorsal spinal cord, with signal abnormality (Fig 2A) and postcontrast enhancement (not shown) as described above. Once again, a rapid clinical and imaging improvement (Fig 2B) followed corticosteroid therapy, with relief of symptoms for 17 months. Etiology of her relapsing cervico-thoracic myelopathy was unknown, because there was no laboratory evidence for any of the pathologic processes hypothesized (including myelitis, late-onset multiple sclerosis, neoplastic disorder, and infectious myelopathy). During her next relapse (May 1997), her clinical symptomatology was quite different than previously in that hemifacial hypoesthesia, paresthesia, and dysesthesia were the main complaints. MR findings were normal in the cervical spine, but there was nodular T1 hypointensity and T2 hyperintensity with slight mass effect in left middle cerebellar peduncle (Fig 3); contrast medium was not administered. Such a finding, congruent with the hypothesis of late-onset demyelinating disease, persisted despite corticosteroid therapy, although the mass effect decreased. Moreover, sequential MR scans revealed similar signal abnormalities, with only initial contrast enhancement in superior, middle, inferior cerebellar, and cerebral peduncles bilaterally, as well as in the dorsal mesencephalum (Figs 4 and 5). The above-mentioned imaging features were observed over a 2-year period, during which a truncal-cerebellar syndrome was clinically found in addition to the remitting cervico-thoracic spinal cord syndrome. Gait disturbances, sensory cranial nerve V dysfunction, ophthalmoplegia, tremor, dysarthria, dysmetria, adyadococynesis and, finally, oculo-facial movement disorders were the most relevant clinical findings. Remission

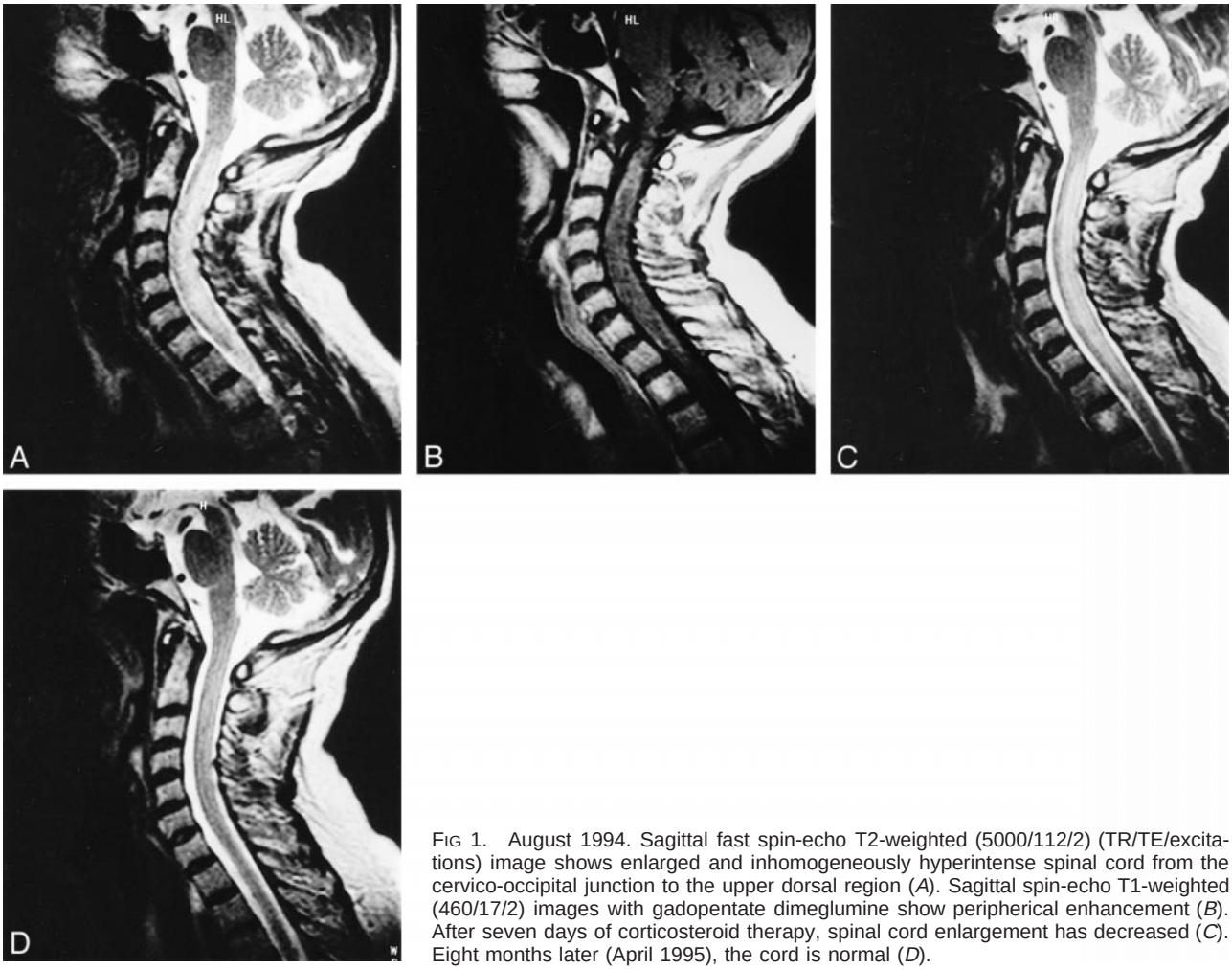

FIG 1. August 1994. Sagittal fast spin-echo T2-weighted (5000/112/2) (TR/TE/excitations) image shows enlarged and inhomogeneously hyperintense spinal cord from the cervico-occipital junction to the upper dorsal region (*A*). Sagittal spin-echo T1-weighted (460/17/2) images with gadopentate dimeglumine show peripherical enhancement (*B*). After seven days of corticosteroid therapy, spinal cord enlargement has decreased (*C*). Eight months later (April 1995), the cord is normal (*D*).

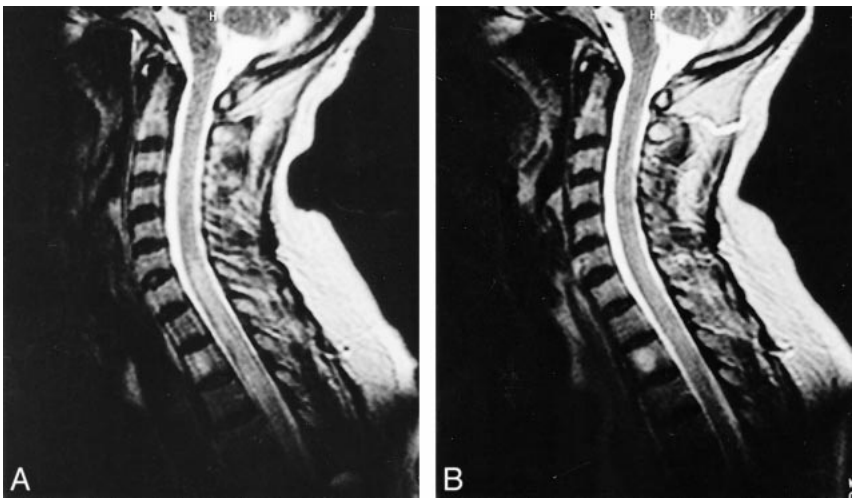

FIG 2. November 1995. Sagittal T2-weighted (5000/112/2) image shows enlarged and inhomogeneously hyperintense spinal cord from distal cervical to upper thoracic cord (*A*). One month later, the cord is normal (*B*).

after corticosteroid therapy was short-lasting and paroxysmal attacks of dysarthria and postural instability became extremely frequent (up to 80 episodes daily) and disabling. The switch from a relapsing-remitting to a chronic-progressive disease course and the onset of the oculo-facial movement disorder caused diagnosis to be questioned, and the possibility of CNS WD was considered, despite the absence of systemic symptomatology in any phase of the illness. Jejunal biopsies were obtained, but they did not show any histopathologic feature of WD. Polymerase chain reaction (PCR) molecular analysis was then performed on jejunal tissue, CSF, and peripheral blood, and DNA of *Tropheryma whippelii* was identified. DNA was extracted from plasma and peripheral blood mononuclear cells, and digested in 200-μL volumes overnight at 55°C, as previously described (13, 14). DNA (5 μg) was mixed with specific primers pW3FE (5′ GGAATTCCAGAGATACGCCCCCC-

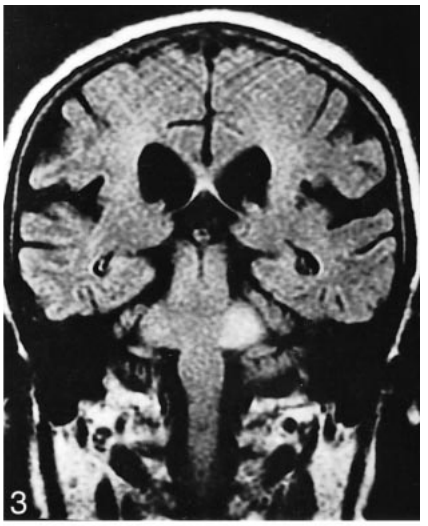

FIG 3. May 1997. Coronal fast-FLAIR (9002/137/2000) (TR/TE/TI) image shows nodular signal hyperintensity with slight mass effect in left middle cerebellar peduncle.

FIG 4. December 1997. Axial fast spin-echo T2-weighted (2300/85/1) (*A*) and enhanced spin-echo T1-weighted (500/14/1) images (*B* and *C*) show hyperintense and enhancing lesions in both middle cerebellar peduncles, in left superior cerebellar peduncle, and in left inferior quadrigeminal colliculus.

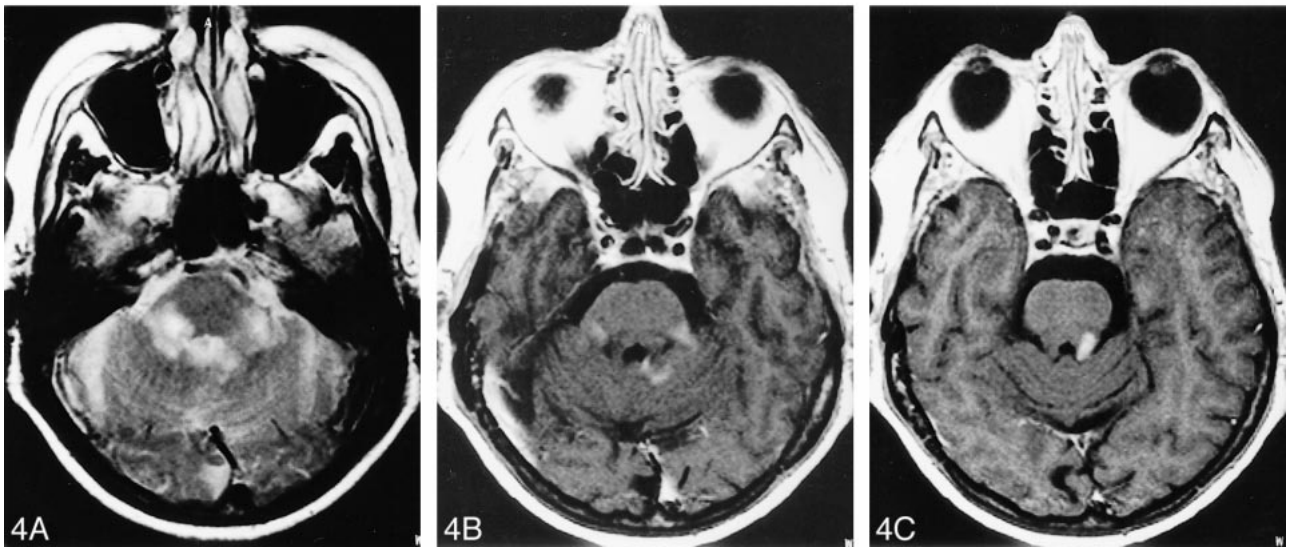

GCAA 3′) and pW2RB (5′ TTCGCTCCACCTTGCGA 3′). The primers were synthesized on a DNA/RNA synthesizer (Oligo 1000 Beckman) and correspond to the region spanning from nucleotides 965 through 983 (PW3FE) and 1214 through 1231 (PW2RB) of the 16S rRNA gene of *T. whippelii*. The PCR mixture (100 μl: 250 μmol of dNTP, 2.5 mM $MgCl_2$ and 200nmol each primer) was subjected to an initial 4-minute denaturation at 94°C. After this step, 40 cycles of amplification were performed (40″ at 94°C, 50″ at 62°C and 50″ at 72°C) in a thermocycler 9600 (Perkin Elmer). DNA from the organism phylogenetically related to *Tropheryma whippelii* (*Actinomyces pyogenes*) was used as a negative control and DNA extracted from paraffin-embedded tissue from a patient with WD was used as a positive control; both were amplified with identical procedures. PCR products (284 bp) were detected by electrophoresis on a 10 % polycrilamide gel and stained with ethidium bromide. On this basis, antibiotic therapy congruent with recent guidelines in the literature for CNS WD (3, 4, 15) (IV sulphamethoxazole-trimethoprim for 2 weeks followed by long-term oral administration) was started, and shortly afterward clinical improvement was observed. Repeat PCR molecular analysis of peripheral blood performed after 4 months gave negative results. Importantly, the disturbing oculo-facial movement disorders dramatically responded to antibiotic therapy. After 12-month treatment, she is doing markedly better. No new MR signal abnormalities have been reported, while the visibility of the previously observed ones has largely decreased (Fig 6); no enhancement was evident after contrast administration.

Discussion

The diagnosis of WD of the CNS is challenging and critical in that it allows specific treatment. It may be extremely difficult if the symptoms occur in the absence of the systemic manifestations of the disease. The clinical picture of CNS involvement is nonspecific and is similar to that of vasculitis or other subacute or chronic encephalopathies, or even tumors, if lesions show mass effect and contrast enhancement (5). When the systemic manifestations are lacking, a biopsy may be diagnostic, and it is a major criterion for definite WD diagnosis (3, 5, 12, 16); however, technological and research progress soon is likely to allow more frequent, noninvasive, definitive diagnosis of WD. Even if attempts to culture the causative organism have been unsuccessful until recently (17), microscopic examination of infected tissue has revealed small

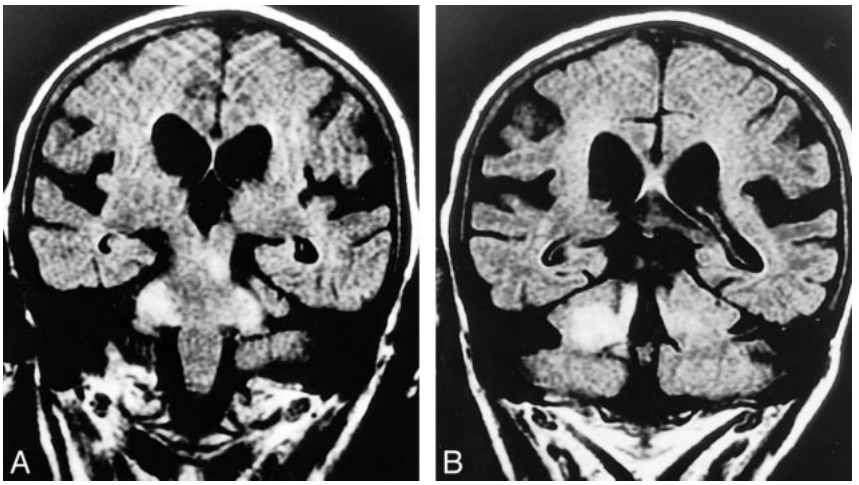

FIG 5. March 1998. Coronal fast-FLAIR (9002/137/2000) images show persistence of the lesions observed previously (*A*), increased involvement of middle and new involvement of superior right cerebellar peduncles (*B*).

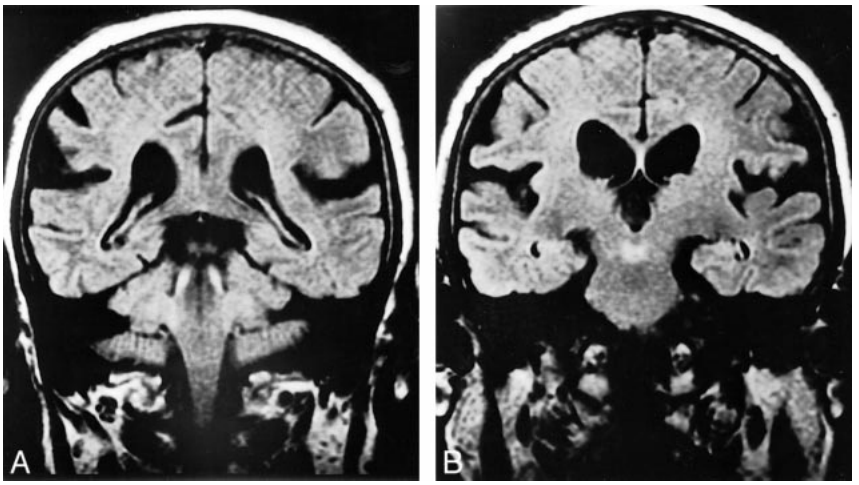

FIG 6. January 2000 (5 months after start of antibiotic therapy). Coronal fast-FLAIR (8802/105/2200) images show regression: only slight signal abnormalities in the structures previously involved, and no new lesions.

gram-positive rods appearing as diastase-resistant intracytoplasmatic inclusions on periodic acid-Schiff (PAS) staining, and electron microscopy has shown they have a characteristic trilaminar membrane (2, 5). At the beginning of the 1990s, identification of bacterial pathogens was accomplished by molecular analysis of the bacterial 16S ribosomal RNA (rRNA) gene. This gene was isolated from infected tissue by use of amplification of the species-specific sequences by the primer-directed PCR. Identification of a novel bacterial 16S rRNA gene sequence in bacterial DNA extracted from biopsy specimens from histopathologically proved cases of WD allowed specific identification of *Tropheryma whippelii* as WD's causative bacillus (13). Subsequently, the presence of genetic material of *Tropheryma whippelii* in the peripheral blood of WD patients has been demonstrated in some cases, and shown in intestinal or brain tissue or CSF in others by use of PCR (3, 14, 18–20). Owing to the high sensitivity and specificity of PCR, the diagnostic importance of this method has been outlined in the last years (19, 20). As far back as 1996, however, Louis et al (3) already proposed that diagnosis and treatment of CNS WD (which should be rapidly instituted, because untreated CNS WD carries a poor prognosis) should be based on the presence of pathognomonic signs or positive biopsy or PCR results. The former reports seem to confirm that a diagnosis of WD can be established from peripheral blood by PCR molecular assay, as proposed by Relman et al (13), and that PCR, as an extremely sensitive and specific method, can allow detection of *Tropheryma whippelii* in the absence of histologic diagnosis (14, 18–22). Nonetheless, one must remember that this is not a typical but is a possible sign of even transient bacteremia. More extensive investigation of molecular analysis in a larger population is needed to better understand the role of peripheral blood PCR analysis in WD. Presently, clinical response to treatment and/or subsequently negative molecular findings after therapy are useful for confirming a diagnosis.

In our case, WD was confined to the CNS. Only 15 such cases have been reported in the literature. In no phase of her clinical history did the patient have systemic manifestations of the disease, and the examination of jejunal biopsy specimens, obtained at the time when the newly presented oculomasticatory symptomatology raised the suspicion of WD, neither revealed the expected histopathologic features nor was positive at PCR analysis.

Pathologic examination of jejunal biopsies can be negative also in traditional gastrointestinal WD, as a result of minimal or patchy involvement, and frequently this is the case with WD patients who present with CNS lesions (WD ''confined'' to the CNS). PCR, despite its higher sensitivity, is likely to give no result in such cases.

Our patient did not undergo CNS tissue biopsy because her clinical history, the MR features of the intracranial lesions, and the last onset sign, ie, oculo-skeletal twitching, seemed highly suggestive of WD, and positive PCR study confirmed disease and prompted antibiotic treatment. Importantly, the negative results of the test after 4-month antibiotic therapy seem to confirm the diagnostic value of PCR analysis of peripheral blood in our case. However, the dramatic improvement of the patient's condition and absence of relapse at 12-month follow-up could be considered the most powerful demonstration of a correct diagnosis.

To our knowledge, this is the second case of spinal presentation of CNS WD. In 1998, Clarke et al (12) described an unusual case of a 62-year-old woman who presented with spastic quadriparesis without evidence of higher cortical dysfunction or neuro-ophthalmologic features. T2-weighted MR images showed high signal lesions in the medulla and cervical cord; no supratentorial abnormality was detected. She was treated with oral dexamethasone and improved. Repeat MR imaging 3 weeks later showed partial resolution of the lesions, which minimally enhanced after administration of contrast material, and a vascular insult seemed likely. At the time of discharge, over 8 weeks after admission, she had satisfactorily improved. Three weeks later, she rapidly deteriorated and MR imaging showed worsening of the high signal and minimally enhancing lesions in the medulla and spinal cord, the latter extending from C3 to D2 with associated cord expansion. A cord biopsy was performed through a midline myelotomy; the biopsy showed a severely disrupted architecture due to large numbers of foamy macrophages containing numerous PAS-positive bacilliform structures, appearances that are consistent with WD. A jejunal biopsy was histologically normal, but PCR study for *Tropheryma whippelii* was positive. This was similar to the situation in our patient.

To conclude, WD should be included in the differential diagnosis of patients presenting with myelopathy, despite the absence of systemic symptomatology. More and more extensive use of MR imaging is likely to detect CNS WD lesions, including spinal involvement, more frequently. MR imaging can identify CNS involvement in WD, evaluate long-term efficacy of treatment, and detect relapse and new localizations, both of which may occur even after several years (23, 24).

References

1. Whipple GH. **A hitherto undescribed disease characterized anatomically by deposits of fat and fatty acids in the intestinal mesenteric lymphatic tissues.** *Bull Johns Hopkins Hosp* 1907;18:382–391
2. Fleming JL, Wiesner RH, Shorter RG. **Whipple's disease: clinical, biochemical, and histopathologic features and assessment of treatment in 29 patients.** *Mayo Clin Proc* 1988;63:539–551
3. Louis ED, Lynch T, Kaufmann P, Fahn S, Odel J. **Diagnostic guidelines in central nervous system Whipple's disease.** *Ann Neurol* 1996;40:561–568
4. Verhagen WIM, Huygen PLM, Dalman JE. **Central nervous system Whipple's disease.** *Ann Neurol* 1997;41:560–561
5. Wroe SJ, Pires M, Harding B, Youl BD, Shorvon S. **Whipple's disease confined to the CNS presenting with multiple intracerebral mass lesions.** *J Neurol Neurosurg Psychiatry* 1991;54:989–992
6. Brown AP, Lane JC, Murayama S, Vollmer DG. **Whipple's disease presenting with isolated neurological symptoms.** *J Neurosurg* 1990;73:623–627
7. Knox DL, Green WR, Troncoso JC, Yardley JH, Hsu J, Zee DS. **Cerebral ocular Whipple's disease: a 62-year odyssey from death to diagnosis.** *Neurology* 1995;45:617–625
8. De Coene B, Gilliard C, Indekeu P, Duprez T, Trigaux JP. **Whipple's disease confined to the central nervous system.** *Neuroradiology* 1996;38:325–327
9. Duprez TPJ, Grandin CBG, Bonnier C, et al. **Whipple disease confined to the central nervous system in childhood.** *AJNR Am J Neuroradiol* 1996;17:1589–1591
10. Anderson M. **Neurology of Whipple's disease.** *J Neurol Neurosurg Psychiatry* 2000;68:2–5
11. Simpson DA, Wishnow R, Gargulinski RB, Pawlak AM. **Oculofacial-skeletal myorhythmia in central nervous system Whipple's disease: additional case and review of the literature.** *Mov Disord* 1995;10:195–200
12. Clarke CE, Falope ZF, Abdelhadi HA, Franks AJ. **Cervical myelopathy caused by Whipple's disease.** *Neurology* 1998;50:1505–1506
13. Relman DA, Schmidt TM, MacDermott RP, Falkow S. **Identification of the uncultured bacillus of Whipple's disease.** *N Engl J Med* 1992;327:293–301
14. Lowsky R, Archer GL, Fyles G, et al. **Diagnosis of Whipple's disease by molecular analysis of peripheral blood.** *N Engl J Med* 1994;331:1343–1346
15. Schnider PJ, Reisinger EC, Berger T, Krejs GJ, Auff E. **Treatment guidelines in central nervous system Whipple's disease.** *Ann Neurol* 1997;41:561–562
16. Mendel E, Khoo LT, Go JL, Hinton D, Zee C-S. Apuzzo MLJ. **Intracerebral Whipple's disease diagnosed by stereotactic biopsy: a case report and review of the literature.** *Neurosurgery* 1999;44:203–209
17. Raoult D, Birg ML, La Scola B, et al. **Cultivation of the bacillus of Whipple's disease.** *N Engl J Med* 2000;342:620–625
18. Lynch T, Odel J, Fredericks DN, et al. **Polymerase chain reaction-based detection of *Tropheryma Whippelii* in central nervous system Whipple's disease.** *Ann Neurol* 1997;42:120–124
19. Ramzan NN, Loftus E Jr, Burgart LJ, et al. **Diagnosis and monitoring of Whipple disease by polymerase chain reaction.** *Ann Intern Med* 1997;126:520–527
20. Pron B, Poyart C, Abachin E, et al. **Diagnosis and follow-up of Whipple's disease by amplification of the 16S rRNA gene of *Tropheryma whippelii*.** *Eur J Clin Microbiol Infect Dis* 1999;18:62–65
21. Durand DV, Lecomte C, Cathebras P, Rousset H, Godeau P. **Whipple disease. Clinical review of 52 cases. The SNFMI Research Group on Whipple disease. Société Nationale Française de Medecine Disease Interne.** *Medicine* 1997;76:170–184
22. Muller C, Petermann D, Stain C, et al. **Whipple's disease: comparison of histology with diagnosis based on polymerase chain reaction in four consecutive cases.** *Gut* 1997;40:425–427
23. Erdem E, Carlier R, Delvalle A, Caquet R, Etienne JP, Doyon D. **Gadolinium-enhanced MRI in cerebral Whipple's disease.** *Neuroradiology* 1993;35:581–583
24. Schnider P, Trattnig S, Kollegger H, Auff E. **MR of cerebral Whipple disease.** *AJNR Am J Neuroradiol* 1995;16:1328–1329