

**Are your MRI contrast agents cost-effective?**

Learn more about generic Gadolinium-Based Contrast Agents.



**FRESENIUS  
KABI**

caring for life

**AJNR**

**Comparative Analysis of MR Imaging,  
Positron Emission Tomography, and Ictal  
Single-photon Emission CT in Patients with  
Neocortical Epilepsy**

Sung-Il Hwang, Jae Hyoung Kim, Sun Won Park, Moon  
Hee Han, In Kyu Yu, Sang Hyun Lee, Dong Soo Lee, Sang  
Kun Lee, Chun-Kee Chung and Kee-Hyun Chang

This information is current as  
of April 17, 2024.

*AJNR Am J Neuroradiol* 2001, 22 (5) 937-946  
<http://www.ajnr.org/content/22/5/937>

# Comparative Analysis of MR Imaging, Positron Emission Tomography, and Ictal Single-photon Emission CT in Patients with Neocortical Epilepsy

Sung-Il Hwang, Jae Hyoung Kim, Sun Won Park, Moon Hee Han, In Kyu Yu, Sang Hyun Lee, Dong Soo Lee, Sang Kun Lee, Chun-Kee Chung, and Kee-Hyun Chang

**BACKGROUND AND PURPOSE:** MR imaging, positron emission tomography (PET), and single-photon emission CT (SPECT) play important roles in presurgical localization of epileptic foci. However, comparative study of these imaging methods for cases of neocortical epilepsy has been limited. The purpose of this study was to compare the sensitivities of these three imaging methods for presurgical localization of neocortical epileptogenic foci.

**METHODS:** We studied 117 consecutive patients who underwent surgery for intractable neocortical epilepsy. The pathologic substrates were neuronal migration disorder (n = 77), tumor (n = 15), and others (n = 25). MR imaging was compared retrospectively with <sup>18</sup>F-fluorodeoxyglucose PET and ictal technetium-99m hexamethylpropyleneamine oxime SPECT regarding their capability to correctly localize the epileptogenic foci. The pathologic findings were used as the standard of reference.

**RESULTS:** Overall, MR imaging, PET, and ictal SPECT correctly localized the lesions for 59.8%, 77.7%, and 70.3% of the patients, respectively, with a 38% concordance rate among the three methods. PET was most sensitive (71–100%) in detecting all substrates. MR imaging was as sensitive (100%) as PET in detecting tumor but was least sensitive (48.1%) in detecting neuronal migration disorder. Ictal SPECT was more sensitive (75.8%) than MR imaging in detecting neuronal migration disorder. Patients with imaging abnormalities achieved good outcomes in 81.4% of the cases, in contrast to 59.5% for those without imaging abnormalities (*P* < .05).

**CONCLUSION:** PET and ictal SPECT were overall more sensitive than was MR imaging, despite the low concordance rate and variable sensitivity depending on substrates. The detection of abnormalities by MR imaging was associated with good outcome. PET or ictal SPECT can be well used as complementary tools, particularly in cases of negative MR imaging findings.

Surgical treatment of epilepsy has been performed for patients with medically intractable epilepsy with focal onset and has become a worldwide established treatment option for such patients. Focal epilepsy can be classified, based on the histologic

and embryologic aspects of the epileptogenic cortex, into mesial temporal lobe epilepsy and neocortical epilepsy, which includes both neocortical temporal and extratemporal origins. Despite a long history of the surgical treatment of epilepsy, surgical practice has been focused on mesial temporal lobe epilepsy, for which higher prevalence, easier characterization, and better surgical outcome were possible, as opposed to surgical treatment of neocortical epilepsy (1). In contrast to mesial temporal lobe epilepsy, which is characterized by hippocampal pathology, neocortical epilepsy lacks a common pathologic substrate. A wide range of structural anomalies is associated with neocortical epilepsy, including neuronal migration disorder, tumor, vascular malformation, and sclerosis from brain injury (trauma, infection, infarction).

Precise presurgical localization of the seizure focus is essential to achieve good surgical outcomes, especially in patients with neocortical epilepsy.

Received July 31, 2000; accepted after revision November 24.

From the Departments of Radiology (S.-I.H., S.W. P., M.H.H., I.K.Y., S.H.L., K.-H.C.), Nuclear Medicine (D.S.L.), Neurology (S.K.L.), and Neurosurgery (C.-K.C.), Seoul National University College of Medicine, Seoul; the Institute of Radiation Medicine SNUMRC (M.H.H., K.-H.C.), Seoul; and the Department of Radiology (J.H.K.), Gyeongsang National University College of Medicine, Chinju, Korea.

This work was supported by grant HMP-99-N-02-0003 from the Medical Technology Development Research Fund, Ministry of Health and Welfare, Korea.

Address reprint requests to Kee-Hyun Chang, MD, Department of Radiology, Seoul National University Hospital, 28 Yongdong-gu, Chongno-gu, Seoul, 110-744, Korea.

Overall surgical outcomes of patients with neocortical epilepsy have been reported to be worse than those of patients with mesial temporal lobe epilepsy, although recent advances in neuroimaging and surgical techniques have improved outcomes (2, 3). Clinical manifestations, video EEG monitoring, neuroimaging, and invasive intracranial EEG play important roles in the presurgical evaluation of patients with epilepsy. MR imaging, positron emission tomography (PET), and single-photon emission CT (SPECT) are now considered important and even vital in presurgical evaluation. These three structural and functional neuroimaging techniques have been extensively studied and reported as individual methods and have been compared with EEG (4, 5). However, it would be preferable to compare these imaging methods to each other for the same patient group at a single institute to enable standardization of equipment, disease, and interpretation of imaging findings. Comparative analysis of these imaging methods is difficult because of limited availability of the techniques, cost, and technologic advances. Most previous comparative studies of these two or three imaging methods were mainly confined to temporal lobe epilepsy (5–9). Comparative study of the three imaging methods in a single large group of patients with neocortical epilepsy has not yet been reported.

The purpose of our study was as follows. First, the sensitivities of MR imaging, PET, and ictal SPECT for presurgical localization of neocortical epileptogenic foci were compared using the pathologic findings as the gold standard of reference. We also compared those sensitivities according to different pathologic substrates. Second, the concordance rates of the results among these imaging methods were evaluated.

## Methods

### *Patient Population*

We reviewed the medical records of 358 consecutive patients who underwent surgery for medically intractable epilepsy at our institute during the period from October 1994 through October 1998. Of these patients, 117 with pathologically confirmed neocortical epilepsy were included in our study. There were 81 male and 36 female patients with an age range of 12 to 46 years (mean, 28 years). Preoperatively, all patients were scheduled to be examined with MR imaging, video EEG monitoring using scalp electrodes, interictal and ictal SPECT, PET, and neuropsychological studies as a routine protocol. Consequently, all patients underwent MR imaging, video EEG monitoring, and neuropsychological studies. However, because of various reasons (such as equipment problems, unavailable radioactive tracers, failure to inject radiopharmaceuticals timely for ictal SPECT, or the high cost of PET), only 103 patients underwent PET, 93 underwent interictal SPECT, and 91 underwent ictal SPECT. Eighty-six patients, who had either normal MR imaging findings or nonconcordant findings among the noninvasive studies, underwent invasive intracranial EEG. Video EEG monitoring was performed in a special epilepsy ward equipped with a 24-hour video monitoring system to enable the simultaneous recording of ictal semiology and ictal EEG.

### *MR Imaging*

Standard MR imaging was performed on a 1.0-T unit (Expert; Siemens AG, Erlangen, Germany) or 1.5-T units (Vision, Siemens AG; and Signa, GE Medical Systems, Milwaukee, WI), using conventional spin-echo T1-weighted sagittal and fast spin-echo T2-weighted axial and coronal sequences. Section thickness was 5 mm, and intersection gap was 1 mm. For the patients who were suspected of having temporal lobe epilepsy, fast spin-echo T2-weighted sequence with 3-mm-thick sections and T1-weighted 3D magnetization-prepared rapid acquisition with gradient-echo sequence with 1.5-mm-thick sections were added in oblique coronal plane for imaging of the temporal lobes. The angle of oblique coronal imaging was perpendicular to the long axis of the hippocampus, with a slight variation of angulation from patient to patient. Spatial resolution was approximately  $1.0 \times 1.0$  mm (matrix,  $256 \times 256$ ; field of view, 25 cm). Contrast enhancement was conducted in selected cases, such as tumor.

### *PET*

Axial raw data were obtained on a PET scanner (ECAT Exact; CTI/Siemens, Knoxville, TN) 60 minutes after IV injection of  $^{18}\text{F}$ -fluorodeoxyglucose (FDG) (370 MBq) during the interictal period. Acquisition time was approximately 20 minutes. Axial images were reconstructed with a Shepp-Logan filter (cutoff frequency, 0.35 cycles per pixel) and realigned in coronal and sagittal planes. Spatial resolution was  $6.1 \times 6.1 \times 4.3$  mm.

### *SPECT*

Baseline axial interictal and ictal SPECT data were acquired using a SPECT scanner (Prism 3000XP; Picker Corp., Cleveland, OH) with triple head camera and fan beam collimator after IV injection of technetium-99m-hexamethylpropyleneamine oxime (925 MBq). For ictal SPECT, the radiotracer was injected during the ictal period, within 30 seconds after the onset of seizure, and then images were obtained 1 to 3 hours after the seizure activity ceased. Axial images were reconstructed with a Metz filter ( $X = 1.7\text{--}2.0$ ). Axial images were realigned in the coronal and sagittal planes. Spatial resolution was  $12 \times 12 \times 5$  mm.

### *Surgery and Pathologic Diagnosis*

Surgical treatment included neocortical resection ( $n = 60$ ), neocortical resection and anterior temporal lobectomy ( $n = 24$ ), anterior temporal lobectomy ( $n = 21$ ), lesionectomy ( $n = 10$ ), and hemispherectomy ( $n = 2$ ). The surgical site was determined primarily by the location of abnormality on MR imaging that was concordant with the results of video EEG. When MR imaging findings were normal or MR imaging abnormalities were not concordant with the results of video EEG or other imaging methods, the operative site was determined on the basis of the results of the invasive EEG, mostly with subdural grid recordings, by the consensus of an epileptologist and neurosurgeon.

Histopathologic examination of the surgical specimens revealed abnormalities in all patients. They consisted of neuronal migration disorder, including focal cortical dysplasia, microdysgenesis, heterotopia, micropolygyria, and neuronal clustering ( $n = 77$ ), benign tumor ( $n = 15$ ), vascular malformation ( $n = 2$ ), traumatic contusion ( $n = 7$ ), infarction ( $n = 5$ ), and others, including nonspecific gliosis and inflammation ( $n = 11$ ) (Table 1).

### *Classification of Surgical Outcomes*

All the patients were regularly followed up for assessment of seizure control and psychosocial outcomes for 12 to 67 months (mean, 34 months) after surgery. Postoperative seizure

TABLE 1: Pathologic diagnosis of neocortical epilepsy

Pathologic Abnormality	Location					
	Temporal	Frontal	Occipital	Parietal	Hemispheric*	Multifocal†
Total (n = 117)	50	33	15	13	2	4
Neuronal migration disorder (n = 77)	28	25	10	10	2	2
Tumors (n = 15)	13	0	1	0	0	1
Others (n = 25)	9	8	4	3	0	1

\* Diffuse hemispheric involvement of the lesion.

† More than two epileptogenic foci separated from each other.

outcomes were determined at the time of the latest follow-up according to Engel's four categories by an epileptologist. Class I (seizure free) indicates an absence of seizure activity since surgery, regardless of medication. Class II (rare seizures) indicates a few seizures in a year. Class III (worthwhile improvement) means at least a 75% improvement in seizure frequency compared with preoperative status. Class IV denotes no worthwhile improvement. Surgical outcomes classified by using Engel's categories were also analyzed on the basis of MR imaging abnormalities.

#### Image Interpretation and Data Analysis

Blinded reinterpretation of MR images and PET and ictal SPECT scans was performed, respectively, without knowledge of the results of clinical examination, EEG, or other imaging findings. The diagnostic criteria for the three imaging methods were based on qualitative visual interpretation. MR images were interpreted by experienced neuroradiologists. Either a specific radiologic diagnosis or a description of the abnormalities, such as abnormal signal intensity, focal or diffuse atrophy, mass effect, and presumably calcified nodule, was documented. For the PET scans, the area of the greatest decrease of FDG uptake was interpreted as the epileptogenic region on the basis of symmetry. For ictal SPECT studies, the area of hyperperfusion relative to the remaining regions was considered as the epileptogenic region. When the hyperperfusion was seen in multiple areas, the most hyperperfused area was regarded as the epileptogenic region. Interictal SPECT was used only as a baseline image to determine the perfusion status on ictal SPECT scans, because in our experience, interictal SPECT showed low sensitivity (approximately <50%). Both PET and SPECT scans were interpreted by an experienced nuclear medicine specialist.

Second, to obtain the correct localization rates of the three imaging methods, the location of abnormality seen on each method was compared with the operative site and the location of histopathologic abnormality by the consensus of two neuroradiologists. When the location of a focal abnormal finding of each imaging method matched the operative site and the location of histopathologic abnormality, it was interpreted as correct localization. When the abnormality on PET or ictal SPECT scans was somewhat diffuse but the extent of abnormality was overlapped with the operative site, it was also interpreted as correct localization.

Subsequently, to determine the concordance and nonconcordance of the results among the three imaging methods in localizing the epileptogenic foci, the results were compared with each other and with the histopathologic findings. The word *concordance* was used when the location of focal or diffuse abnormal findings on MR images or PET or ictal SPECT scans was consistent with each other and when this abnormality was seen in the same area as that revealed by the histopathologic examination. Therefore, when an abnormal finding on PET or SPECT scans was seen remote from that revealed by other imaging methods or histopathologic examination (ie, right frontal lobe on PET or SPECT scans and right temporal lobe on MR images or revealed by histopathologic examina-

tion), it was interpreted as nonconcordance. However, when the abnormality on PET or ictal SPECT scans was somewhat diffuse but was seen on the same side with some overlapping of lesion location as revealed by other imaging methods and the histopathologic examination, it was considered as concordance.

We obtained the correct localization rates of each imaging method and the concordance rates among the three imaging methods. The correct localization rates were also obtained according to different pathologic substrates and their locations (ie, temporal versus extratemporal).

We used the  $\chi^2$  test to assess the statistical significance of the differences for the following data: 1) correct localization rates among different imaging methods and between temporal and extratemporal foci, 2) concordance rates of the three imaging methods, and 3) good surgical outcome rates between patients with and those without MR imaging abnormalities. The level of significance was defined as  $P < .05$ . Computations were performed with the SPSS statistical software package (SPSS, Chicago, IL).

## Results

Abnormalities on MR images and PET and ictal SPECT scans were found in 81 of 117 patients, 93 of 103 patients, and 84 of 91 patients, respectively. Of these patients with imaging abnormalities, 11 who underwent MR imaging, 13 who underwent PET, and 20 who underwent ictal SPECT were considered to have received incorrect localization, when compared with operative sites and histopathologic findings. Therefore, MR imaging, PET, and ictal SPECT localized the epileptogenic foci correctly in 59.8% (70 of 117 patients), 77.7% (80 of 103 patients), and 70.3% (64 of 91 patients) of the patients, respectively (Table 2). The difference of the correct localization rates between MR imaging and PET (59.8% versus 77.7%) was statistically significant ( $P < .05$ ).

The epileptogenic foci were located in the temporal lobe in 50 patients and in the extratemporal regions in 67 patients. For the patients with temporal epileptogenic foci, correct localization rates of MR imaging, PET, and ictal SPECT were 64.0% (32 of 50 patients), 86.7% (39 of 45 patients), and 80.6% (29 of 36 patients), respectively, whereas those for the patients with extratemporal foci were 56.7% (38 of 67 patients), 70.7% (41 of 58 patients), and 63.6% (35 of 55 patients), respectively (Table 2). However, correct localization rates between temporal and extratemporal locations were not statistically significantly different.

TABLE 2: Correct localization rates of imaging methods

	MR			PET			Ictal SPECT		
	Temporal	Extratemporal	Total	Temporal	Extratemporal	Total	Temporal	Extratemporal	Total
	Total (n = 117)	64.0% (32/50)	56.7% (38/67)	59.8% (70/117)*	86.7% (39/45)	70.7% (41/58)	77.7% (80/103)*	80.6% (29/36)	63.6% (35/55)
Neuronal migration disorder (n = 77)	46.4% (13/28)	49.0% (24/49)	48.1% (37/77)†	80.8% (21/26)	65.1% (28/43)	71.0% (49/69)†	85.7% (18/21)	70.7% (29/41)	75.8% (47/62)‡
Tumors (n = 15)	100% (13/13)	100% (2/2)	100% (15/15)‡	100% (11/11)	100% (2/2)	100% (13/13)‡	66.7% (6/9)	0% (0/2)	54.5% (6/11)‡
Others (n = 25)	66.7% (6/9)	75.0% (12/16)	72.0% (18/25)	87.5% (7/8)	84.6% (11/13)	85.7% (18/21)	83.3% (5/6)	50.0% (6/12)	61.1% (11/18)

\*  $P < .05$  between MR imaging and PET.

†  $P < .01$  between MR imaging and PET, and between MR imaging and ictal SPECT.

‡  $P < .01$  between MR imaging and ictal SPECT, and  $P < .05$  between PET and ictal SPECT.

TABLE 3: Concordance rates among three imaging methods

Imaging Methods	Concordance Rates
MR and PET	53.4% (55/103)
MR and ictal SPECT	42.9% (39/91)
PET and ictal SPECT	58.0% (47/81)
MR, PET, and ictal SPECT	38.3% (31/81)

Neuronal migration disorder, as the most common pathologic substrate, was found in 77 patients. For these patients, MR imaging, PET, and ictal SPECT localized the epileptogenic foci correctly in 48.1% (37 of 77 patients), 71.0% (49 of 69 patients), and 75.8% (47 of 62 patients), respectively (Table 2). The differences of the correct localization rates between MR imaging and PET (48.1% versus 71.0%) and between MR imaging and ictal SPECT (48.1% versus 75.8%) were statistically significant ( $P < .01$ ).

Tumors were found in 15 patients. Correct localization rates of MR imaging, PET, and ictal SPECT were 100% (15 of 15 patients), 100% (13 of 13 patients), and 54.5% (6 of 11 patients), respectively (Table 2). The differences of the correct localization rates between MR imaging and ictal SPECT (100% versus 54.5%) and between PET and ictal SPECT (100% versus 54.5%) were statistically significant ( $P < .01$  and  $P < .05$ , respectively).

The results of MR imaging were concordant with those of PET and ictal SPECT in 53.4% (55 of 103 patients) and 42.9% (39 of 91 patients), respectively (Table 3). The results of PET were concordant with those of ictal SPECT in 58.0% (47 of 81 patients). The overall concordance rate among all three imaging methods was 38.3% (31 of 81 patients) (Fig 1).

Eighty-seven of the total patients achieved good surgical outcomes (classes I and II). For these patients, MR imaging, PET, and ictal SPECT localized the lesion correctly in 65.5% (57 of 87 patients), 77.2% (61 of 79 patients), and 73.8% (48 of 65 patients), respectively (Table 4). The results of MR imaging were concordant with those of PET and ictal SPECT in 58.2% (46 of 79 patients) and 47.7% (31 of 65 patients), respectively. The overall concordance rate among all three imaging methods was 41.7% (25 of 60 patients).

For the total patients, MR imaging findings were interpreted to be normal in 30.8% (36 of 117 patients) (Fig 2): 16 with temporal lobe epilepsy, 11 with frontal lobe epilepsy, and nine with occipital lobe epilepsy. These patients had pathologic substrates of neuronal migration disorder (n = 31) and others (n = 5) revealed by histopathologic examination. For these patients with normal MR imaging findings, PET localized the lesion correctly in 59.4% (19 of 32 patients) (Fig 3), and ictal SPECT in 54.8% (17 of 31 patients) (Fig 4) (Table 5). The results of PET were concordant with those of ictal SPECT in 39.3% (11 of 28 patients).

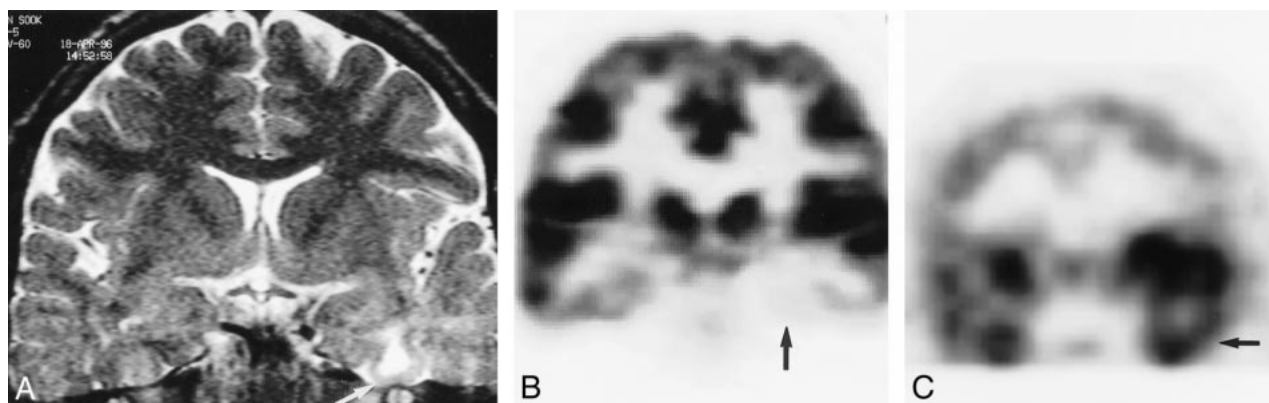


FIG 1. Concordance of the results among MR imaging, PET, and ictal SPECT findings for a 36-year-old man with left neocortical temporal lobe epilepsy.

A, Oblique coronal fast spin-echo T2-weighted (6000/90) MR image shows a well-defined focal high signal intensity in the left inferior temporal lobe (arrow).

B, FDG PET scan shows hypometabolism in the left inferior temporal lobe (arrow).

C, Ictal SPECT scan shows focal hyperperfusion in the left inferior temporal lobe (arrow). Lesion-like increased uptake in the right frontotemporal lobe is due to asymmetrical reconstruction of the image. After anterior temporal lobectomy, the pathologic diagnosis was dysembryoplastic neuroepithelial tumor. Engel's outcome was class I.

TABLE 4: Correct localization rates of imaging methods in patients with good surgical outcomes

	MR	PET	Ictal SPECT
Total (n = 87)	65.5% (57/87)*	77.2% (61/79)*	73.8% (48/65)*
Neuronal migration disorder (n = 57)	52.6% (30/57)	70.4% (38/54)	82.2% (37/45)
Tumors (n = 13)	100% (13/13)	100% (11/11)	44.4% (4/9)
Others (n = 17)	82.4% (14/17)	85.7% (12/14)	63.6% (7/11)

\* P > .05 among three imaging methods.

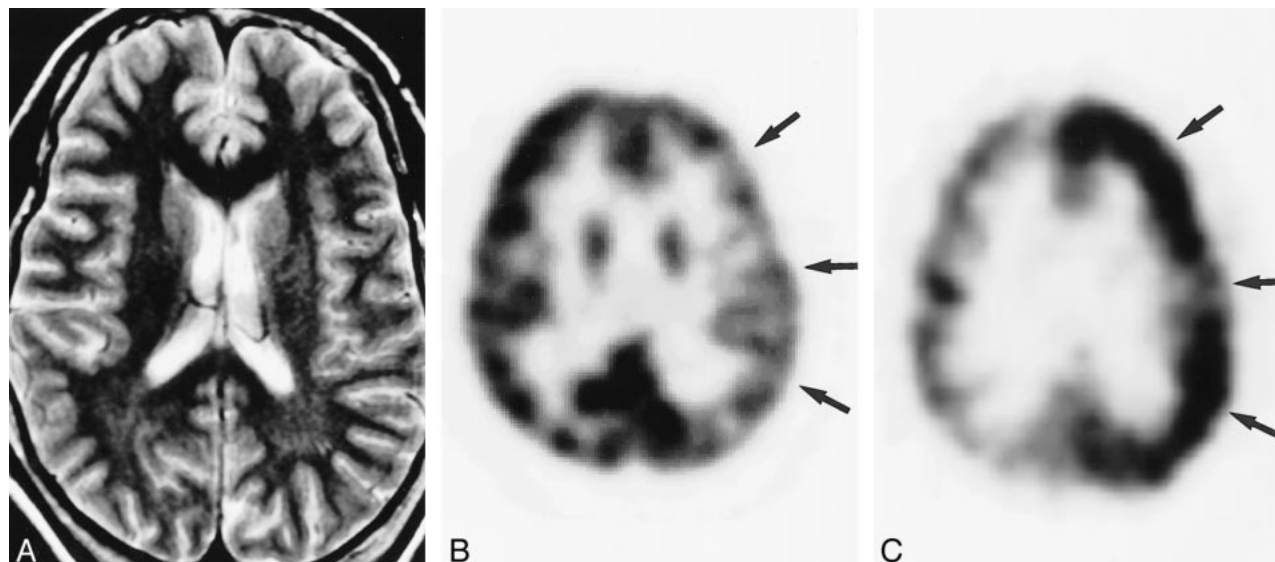


FIG 2. False-negative MR imaging finding for a 24-year-old woman with left frontal lobe epilepsy.

A, Axial fast spin-echo T2-weighted (5000/100) MR image shows no diagnostic abnormality.

B, FDG PET scan shows diffuse hypometabolism in the left frontal and parietal cortices (arrows).

C, Ictal SPECT scan shows diffuse hyperperfusion in the same area as that shown in B (arrows). Invasive EEG study localized the epileptogenic focus in the left inferior frontal lobe. After neocortical resection, the pathologic diagnosis was cortical dysplasia. Engel's outcome was class I.

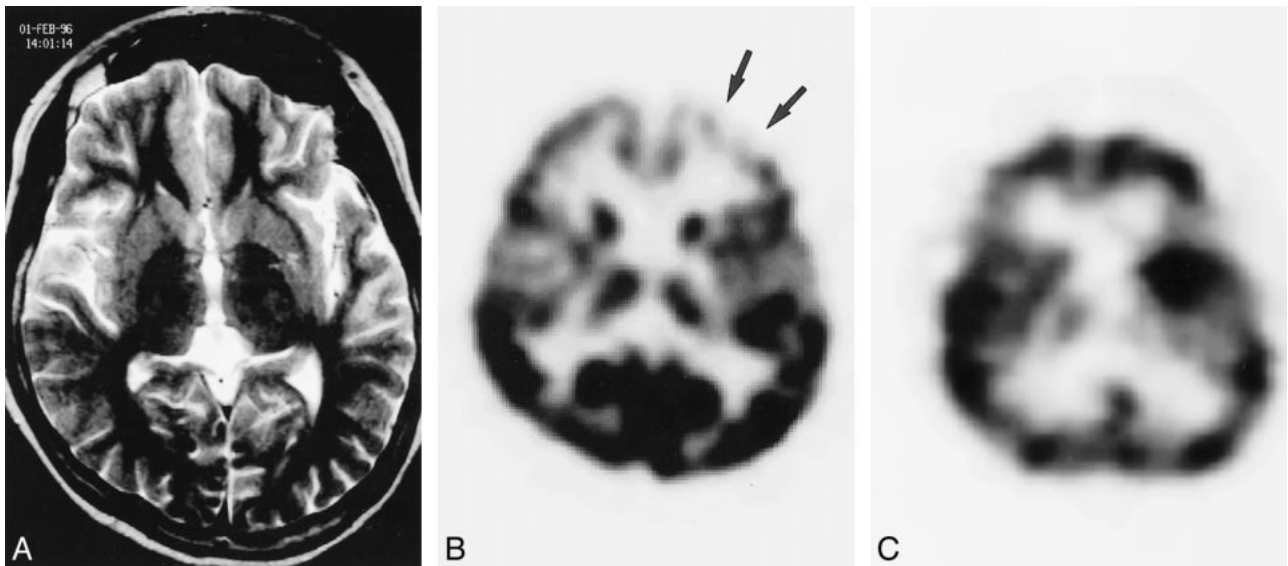


FIG 3. False-negative MR imaging and ictal SPECT findings for an 18-year-old female patient with left frontal lobe epilepsy. A, Axial fast spin-echo T2-weighted (6000/90) MR image shows no diagnostic abnormality. B, FDG PET scan shows focal hypometabolism in the left frontal cortex (arrows). C, Ictal SPECT scan fails to show hyperperfusion in any area. Lesion-like increased uptake in the left basal ganglia is due to asymmetrical reconstruction of the image. Invasive EEG study detected ictal activity originating from the left frontal lobe. After neocortical resection, the pathologic diagnosis was microdysgenesis. Engel's outcome was class IV.

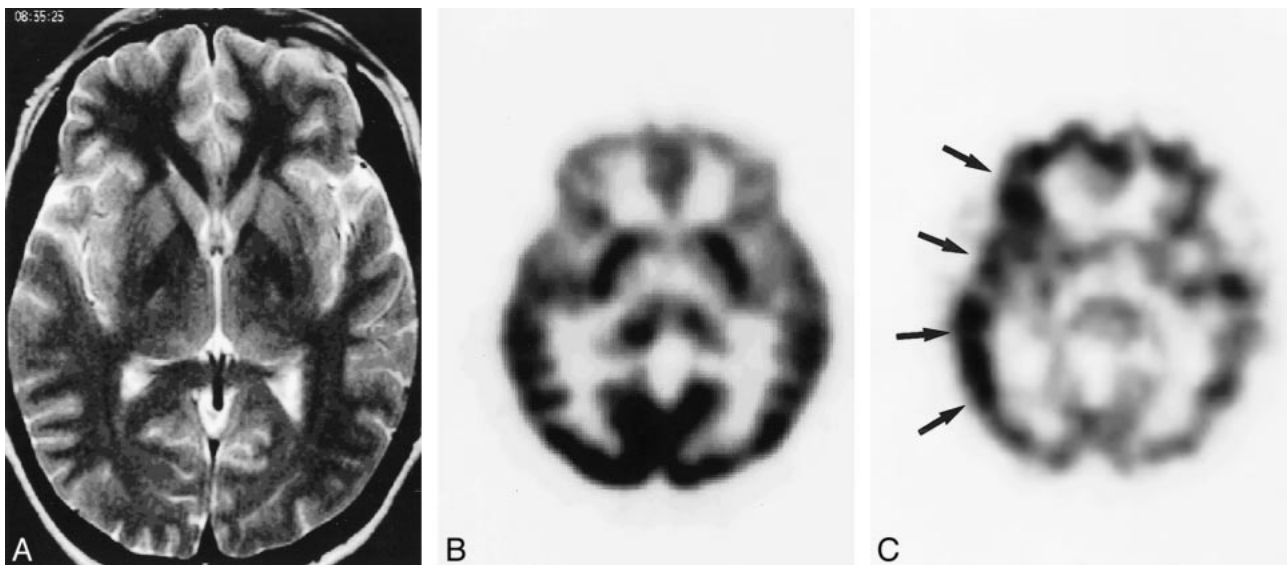


FIG 4. False-negative MR imaging and PET findings for a 25-year-old woman with right neocortical temporal lobe epilepsy. A, Axial fast spin-echo T2-weighted (6000/90) MR image shows no focal abnormalities. B, Axial FDG PET scan shows no focal abnormalities. C, Ictal SPECT scan shows somewhat diffuse hyperperfusion in the right frontotemporal cortices (arrows). Invasive EEG study detected ictal activity arising from the right temporoparietal area. After neocortical resection, the pathologic diagnosis was heterotopia. Engel's outcome was class I.

TABLE 5: Correct localization rates of PET and ictal SPECT in patients with normal MR imaging findings

	PET	Ictal SPECT
Total (n = 36)	59.4% (19/32)	54.8% (17/31)
Neuronal migration disorder (n = 31)	55.6% (15/27)	51.9% (14/27)
Others (n = 5)	80.0% (4/5)	75.0% (3/4)

TABLE 6: Surgical outcomes according to MR imaging abnormality

Engel's Outcome Class	MR Imaging Findings		Total (n = 117†)
	Abnormal (n = 70*)	Normal (n = 36)	
I = Seizure free	64.3% (45/70)‡	58.3% (21/36)‡	61.5% (72/117)
II = Rare seizures	17.1% (12/70)‡	2.8% (1/36)‡	12.8% (15/117)
III = Worthwhile improvement	11.4% (8/70)	22.2% (8/36)	15.4% (18/117)
IV = No Worthwhile improvement	7.1% (5/70)	16.7% (6/36)	10.3% (12/117)

\* Patients with correctly localizing MR imaging abnormalities.

† All patients including 11 patients with incorrectly localizing MR imaging abnormalities.

‡ The difference of good outcome rates (Class I and II) between two subgroups with abnormal and normal MR imaging findings was statistically significant ( $P < .05$ ).

The surgical outcomes of the total patients according to MR imaging abnormalities are summarized in Table 6. Patients with correctly localizing MR imaging abnormalities achieved good outcomes (classes I and II) in 81.4% of the cases (57 of 70 patients), whereas patients with normal MR imaging findings achieved good outcomes in 61.1% of the cases (22 of 36 patients). Good outcome rates between these two groups (81.4% versus 61.1%) were statistically significantly different ( $P < .05$ ).

### Discussion

Precise localization of the epileptogenic foci for the surgical treatment of epilepsy is more difficult in patients with neocortical epilepsy than in those with mesial temporal lobe epilepsy. Although a few studies have tried to differentiate clinical and electrographic manifestations between mesial temporal lobe epilepsy and neocortical temporal lobe epilepsy (10–12) and between temporal lobe epilepsy and extratemporal epilepsy (13, 14), MR imaging, PET, and SPECT have played important roles in presurgical localization. Recent advances in imaging techniques allow more precise noninvasive localization of epileptogenic foci, thereby lessening the need for invasive intracranial EEG. MR imaging provides anatomic and histopathologic information associated with epilepsy, whereas PET and SPECT provide functional information.

The results of MR imaging, PET, and ictal SPECT in localizing the epileptogenic foci have been variably reported in the literature, and those results were reviewed and summarized by Spencer (4). In this review, the highest sensitivity was obtained with ictal SPECT (90% in temporal and 81% in extratemporal epilepsy), the lowest sensitivity with MR imaging (55% in temporal and 43% in extratemporal epilepsy), and intermediate sensitivity with PET (84% in temporal and 33% in extratemporal epilepsy) by using EEG as the standard of reference. However, these sensitivities cannot be exactly compared with our results because they could not differentiate neocortical temporal lobe epilepsy from mesial temporal lobe epilepsy. Furthermore, the technical advancement of all three imaging methods since the study conducted by

Spencer might have improved the detection rate of pathologic lesions. In our study, the overall correct localization rate of the epileptogenic foci, including both neocortical temporal and extratemporal origins, was lowest with MR imaging (59.8%), highest with PET (77.7%), and intermediate with ictal SPECT (70.3%) for the total patients. For patients with good surgical outcomes, however, the correct localization rate of MR imaging (65.5%) was slightly higher than that for the total patients, in contrast to those of PET (77.2%) and ictal SPECT (73.8%), which were relatively constant. Even for patients with normal MR imaging findings who had worse surgical outcomes than did patients with abnormal MR imaging findings, the correct localization rates of PET (59.4%) and ictal SPECT (54.8%) remained good. All these findings indicated that PET and ictal SPECT in neocortical epilepsy show relatively high and constant correct localization rates compared with MR imaging, whereas MR imaging findings are better associated with surgical outcomes. This result is also supported by previous studies describing that patients with MR imaging abnormalities in cases of extratemporal epilepsy achieved better surgical outcomes than did those without MR imaging abnormalities (15–17).

Location of the epileptogenic focus seems to be related to the sensitivity of imaging methods. According to previous studies (4, 9, 17), MR imaging, PET, and ictal SPECT each showed higher sensitivity in cases of temporal lobe epilepsy that included both mesial and neocortical origins than in cases of extratemporal epilepsy. This higher sensitivity in cases of temporal lobe epilepsy may have been achieved largely because of inclusion of mesial temporal lobe epilepsy, which is characterized by better localization than is any other type of epilepsy. However, there has been no study to compare the sensitivities achieved separately in cases of neocortical temporal lobe epilepsy and extratemporal epilepsy. In our study, higher correct localization rates were achieved for the patients with neocortical temporal lobe epilepsy with all three imaging methods (64.0% with MR imaging, 86.7% with PET, and 80.6% with ictal SPECT) than for the patients with extratemporal epilepsy (56.7% with MR imaging, 70.7% with PET, and 63.6% with ictal SPECT). However, higher sensitivity of



MR imaging in cases of neocortical temporal lobe epilepsy must be due to topologic predilection of tumors in the temporal lobe, because MR imaging showed a 100% correct localization rate for tumors. When tumors are excluded, there is no difference in the sensitivity of MR imaging between neocortical temporal and extratemporal locations. On the other hand, the correct localization rates of PET and ictal SPECT in cases of neocortical temporal lobe epilepsy are higher than those of extratemporal epilepsy and similar to those of mesial temporal lobe epilepsy, when compared with a recent previous study (9) in which the majority of the cases of temporal lobe epilepsy were of mesial temporal origin. The reason for low correct localization rates of PET and ictal SPECT in extratemporal epilepsy is unclear. With extratemporal epilepsy, the epileptogenic focus is known to be difficult to localize using EEG because of more variation in the extent of epileptogenic lesions and more complexity of epileptiform activity than with the more common temporal lobe epilepsy (18, 19). As a similar scenario, there may be a functional difference between the temporal and extratemporal regions, such as cerebral connectivity or spread patterns of the epileptiform discharge, causing the difference of localization rates, although the mechanism cannot be suggested clearly.

Neuronal migration disorder is a common pathologic substrate associated with epilepsy, and it frequently has an extratemporal location (20, 21). In our study, neuronal migration disorder was the most common pathologic substrate and it had more extratemporal locations than did tumor, as shown in Table 1. We included cortical dysplasia, microdysgenesis, heterotopia, micropolygyria, and neuronal clustering in the pathologic substrate of neuronal migration disorder, and cortical dysplasia was a major pathologic finding. The MR images of patients with mild to moderate dysplasia have a tendency to show subtle and restricted lesions or unremarkable findings (21–23). In our study, the correct localization rate of MR imaging was 59.8% for the total patients. For patients with neuronal migration disorder, however, it dropped to 48.1% in contrast to those of PET and ictal SPECT, which were relatively equal or increased. The low correct localization rate of MR imaging in our study might be due to inclusion of mild degree lesions. Approximately one-half the patients with neuronal migration disorder in our study had normal MR imaging findings, and, conversely, most of patients with normal MR imaging findings had neuronal migration disorder. These results reflect a relative insensitivity of MR imaging to neuronal migration disorder, especially in cases of mild dysplasia. These results are also consistent with a previous review of the literature describing that half the patients with normal MR imaging findings in cases of neuronal migration disorder had abnormal PET and SPECT findings (5).

The tumor is another major pathologic substrate associated with epilepsy, and it has temporal predilection in location (21, 24). In our study, tumors were the second most common pathologic substrates and most of them were located in the temporal lobe. As mentioned earlier, focal lesions, particularly tumor detected on MR images, are associated with good surgical outcomes (16). In our study, 86.7% (13 of 15 patients) of patients with tumor achieved good surgical outcomes, which was best among all pathologic substrates. A previous review of the literature (5) reported that MR imaging was the most sensitive (96%) and interictal SPECT was the least sensitive (82%) in detecting the tumors. Although the results of ictal SPECT were not available in this review, comparable results were found in our study; correct localization rates of MR imaging, PET, and ictal SPECT were 100%, 100%, and 54.5%, respectively. The reason for the low sensitivity of ictal SPECT in cases of tumor is not clear, although a small population of patients with tumors can be a possible factor in our study. Further investigation may be needed to clarify the physiological relationship between radiotracer kinetics and epileptogenic mechanism in cases of tumor.

PET has the unique ability to image cerebral metabolism during the interictal period. There is a wide discrepancy in the sensitivity of PET in cases of extratemporal epilepsy between our study and previous studies. According to the literature review (4), PET showed the lowest sensitivity (33%) in cases of extratemporal epilepsy. When MR imaging results were negative, PET was considered to have no advantage in cases of extratemporal epilepsy (25). In our study, with a larger number of patients than in previous studies, PET showed the highest correct localization rate (70.7%) among the three imaging methods in cases of extratemporal epilepsy. Furthermore, more than half the patients with normal MR imaging findings had abnormalities revealed by PET. We cannot explain this wide discrepancy (33% versus 70.7%). Clearly, however, technical advancement (ie, improved spatial resolution) may be a factor contributing to the improvement of PET sensitivity in our study. Further study is needed of the role of PET in cases of extratemporal epilepsy.

SPECT is used to assess cerebral blood flow changes during the ictal and interictal periods because of the short uptake time of the radiotracer. The sensitivity of ictal SPECT was reported to be the highest among the three imaging methods in both cases of temporal lobe epilepsy and cases of extratemporal epilepsy in a previous literature review (4). In our study, the overall correct localization rate of ictal SPECT (70.3%), regardless of lesion location, was slightly lower than that of PET (77.7%). However, correct localization of ictal SPECT was variable depending on the pathologic substrates, slightly higher than that of PET in cases of neuronal migration disorder (75.8% with ictal

SPECT and 71.0% with PET), and remarkably lower than that of PET in cases of tumor (54.5% with ictal SPECT and 100% with PET). Therefore, we think that the difference of sensitivities between our study and those previously reported might be caused by a different proportion of the pathologic substrates.

The results of MR imaging, PET, and ictal SPECT cannot be perfectly concordant because these methods rely on inherently different physiological mechanisms for imaging. Only a few comparative studies regarding the sensitivity of imaging methods in cases of focal epilepsy have been conducted with all three methods (5, 6, 9) and with PET and SPECT only (7, 8). Because of different populations of patients, different types of epilepsy, and advancement in imaging techniques (especially in image resolution) between the studies, the concordance rates of the imaging methods in the previous studies cannot be easily compared with those of our study. Among the previous studies, a recent one (9) included a large single group of patients, most of whom were of mesial temporal lobe epilepsy. The authors reported a 55% concordance rate among all three imaging methods, 68% between MR imaging and PET, 58% between MR imaging and ictal SPECT, and 71% between PET and ictal SPECT. In our study, concordance rates in the same sequence as above were 38.3%, 53.4%, 42.9%, and 58.0%. The relatively low concordance rates in our study can be explained by lower sensitivities of each imaging method in cases of neocortical epilepsy than in cases of mesial temporal lobe epilepsy. Concordance rates may also vary depending on the different kinds of pathologic substrates, as do correct localization rates. Therefore, the combined use of imaging methods is important in the clinical field for accurate localization, particularly when the results of video EEG and MR imaging are not conclusive.

The detection of abnormalities by MR imaging was associated with good outcomes in this study. This result reflects that focal abnormalities, such as tumors, are well revealed by MR imaging and can be completely removed. Therefore, outcomes associated with focal abnormalities will be better than those associated with diffuse or multifocal abnormalities, such as neuronal migration disorder or gliosis, which cannot be resected entirely even though invasive EEG is applied. Neuronal migration disorder has a tendency to show subtle, diffuse, or multifocal lesions that are relatively insensitive to MR imaging (21–23). Most of the patients with normal MR imaging findings in this study had neuronal migration disorder, although more than a half these patients had abnormal PET and SPECT findings. All these findings suggest the role of PET and ictal SPECT as complementary tools to MR imaging in cases with negative MR imaging findings.

Our study has several limitations. First, we did not routinely perform fluid-attenuated inversion recovery imaging and high-resolution T2-weighted

imaging for this patient population, which might have increased the sensitivity of MR imaging. Fluid-attenuated inversion recovery imaging was not available during the early period of our study, and high-resolution T2-weighted imaging has not been routinely used for patients with extratemporal neocortical epilepsy. Therefore, the routine use of these imaging techniques in cases of neocortical epilepsy might have improved the localization rate of MR imaging in this study. Second, there are no exact criteria by which MR imaging, PET, and ictal SPECT can be compared with each other. In our study, we interpreted nonconcordance when the abnormal findings on each imaging method were seen remote from each other, even though they were seen in the same hemisphere. Although this interpretation was conducted by the consensus of two radiologists, an inherent difference among the three imaging methods owing to different imaging mechanisms and spatial resolutions might prohibit the establishment and application of precise criteria. Third, the pathologic findings that we used as the standard of reference are not absolute means for verification because poor outcomes still exist after surgery. In our study, however, we also considered concordance between the location of an abnormal imaging finding and an operative site when determining the correctness of localization. Therefore, comprehensive results of all presurgical evaluations, including invasive EEG, were used together with pathologic findings as references. We think that this is more practical in the clinical field than using a single reference, such as EEG or surgical outcome, alone.

## Conclusion

The sensitivity of each imaging method in localizing the epileptogenic foci in cases of neocortical epilepsy was variable according to the pathologic substrates and their locations. PET and ictal SPECT were overall more sensitive than MR imaging despite a low concordance rate among the three methods, whereas MR imaging abnormality was associated with good outcomes. Therefore, PET or ictal SPECT can be well used as a complementary tool to MR imaging, particularly in the cases of inconclusive localization with video EEG and MR imaging. The combination of imaging findings in relation to each other can enable more accurate localization in cases of neocortical epilepsy with a wide range of pathologic substrates.

## References

1. Comair YG, Choi HY, Ness PV. **Neocortical resections.** In: Engel J, Pedley TA, eds. *Epilepsy: A Comprehensive Textbook*. Philadelphia: Lippincott-Raven Publishers; 1997; 1819–1828
2. Rasmussen T. **Focal epilepsies of non-temporal and non-frontal origin.** In: Weiser HG, Elger CE, eds. *Presurgical Evaluation of Epileptics: Basics, Techniques and Implications*. Berlin: Springer-Verlag; 1987; 344–351
3. Engel J Jr. **Surgery for seizures.** *N Engl J Med* 1996;334:647–652

4. Spencer SS. **The relative contribution of MRI, SPECT, and PET imaging in epilepsy.** *Epilepsia* 1994;35[suppl 6]:S72-S89
5. Spencer SS, Theodore WH, Berkovic SF. **Clinical applications: MRI, SPECT, and PET.** *Magn Reson Imaging* 1995;13:1119-1124
6. Stefan H, Pawlik G, Bocher-Schwarz HG, et al. **Functional and morphological abnormalities in temporal lobe epilepsy: a comparison of interictal and ictal EEG, CT, MRI, SPECT and PET.** *J Neurol* 1987;234:377-384
7. Coubes P, Awad IA, Antar M, Magdinec M, Sufka B. **Comparison and spatial correlation of interictal HMPAO-SPECT and FDG-PET in intractable temporal lobe epilepsy.** *Neurol Res* 1993;15:160-168
8. Markand ON, Salanova V, Worth R, Park H-M, Wellman HN. **Comparative study of interictal PET and ictal SPECT in complex partial seizures.** *Acta Neurol Scand* 1997;95:129-136
9. Won HJ, Chang KH, Cheon JE, et al. **Comparison of MR imaging with PET and ictal SPECT in 118 patients with intractable epilepsy.** *AJNR Am J Neuroradiol* 1999;20:593-599
10. Pacia SV, Devinsky O, Perrine K, et al. **Clinical features of neocortical temporal lobe epilepsy.** *Ann Neurol* 1996;40:724-730
11. Foldvary N, Lee N, Thwaites G, et al. **Clinical and electrographic manifestations of lesional neocortical temporal lobe epilepsy.** *Neurology* 1997;49:757-763
12. Jung WY, Pacia SV, Devinsky R. **Neocortical temporal lobe epilepsy: intracranial EEG features and surgical outcome.** *J Clin Neurophysiol* 1999;16:419-425
13. Bleasel A, Kotagal P, Kankirawatana P, Rybicki L. **Lateralizing value and semiology of ictal limb posturing and version in temporal lobe and extratemporal epilepsy.** *Epilepsia* 1997;38:168-174
14. Kutsy RL. **Focal extratemporal epilepsy: clinical features, EEG patterns, and surgical approach.** *J Neurol Sci* 1999;166:1-15
15. Lorenzo NY, Parisi JE, Cascino GD, Jack CR Jr, Marsh WR, Hirschorn KA. **Intractable frontal lobe epilepsy: pathological and MRI features.** *Epilepsy Res* 1995;20:171-178
16. Zentner J, Hufnagel A, Ostertun B, et al. **Surgical treatment of extratemporal epilepsy: clinical, radiologic, and histopathologic findings in 60 patients.** *Epilepsia* 1996;37:1072-1080
17. Chong BW, Shelton DK. **Magnetic resonance imaging, positron emission tomography, and single-photon-emission computed tomography in epilepsy.** *West J Med* 1996;165:53-54
18. Olivier A, Awad IA. **Extratemporal resections.** In: Engel J, ed. *Surgical Treatment of the Epilepsies*. 2nd ed. New York: Raven Press; 1993; 489-500
19. Westmoreland BF. **The EEG findings in extratemporal seizures.** *Epilepsia* 1998;39[suppl 4]:S1-S8
20. Taylor DC, Falconer MA, Bruton CJ, Corsellis JA. **Focal dysplasia of the cerebral cortex in epilepsy.** *J Neurol Neurosurg Psychiatry* 1971;34:369-87
21. Hirabayashi S, Binnie CD, Janota I, Polkey CE. **Surgical treatment of epilepsy due to cortical dysplasia: clinical and EEG findings.** *J Neurol Neurosurg Psychiatry* 1993;56:765-770
22. Mischel PS, Nguyen LP, Vinters HV. **Cerebral cortical dysplasia associated with pediatric epilepsy. review of neuropathologic features and proposal for a grading system.** *J Neuropathol Exp Neurol* 1995;54:137-153
23. Kuzniecky R, Garcia JH, Faught E, Morawetz RB. **Cortical dysplasia in temporal lobe epilepsy: magnetic resonance imaging correlations.** *Ann Neurol* 1991;29:293-298
24. Prayson RA, Estes ML, Morris HH. **Coexistence of neoplasia and cortical dysplasia in patients presenting with seizures.** *Epilepsia* 1993;34:609-615
25. Engel J, Henry TR, Risinger MW, Sutherling WW, Chugani HT. **PET in relation to intracranial electrode evaluations.** *Epilepsy Res Suppl* 1992;5:111-120