

# Generic Contrast Agents

Our portfolio is growing to serve you better. Now you have a *choice*.



[VIEW CATALOG](#)

# AJNR

## **Dural Arteriovenous Fistula in Children: Endovascular Treatment and Outcomes in Seven Cases**

Patricia K. Kincaid, Gary R. Duckwiler, Y. Pierre Gobin and  
Fernando Viñuela

This information is current as  
of May 12, 2025.

*AJNR Am J Neuroradiol* 2001, 22 (6) 1217-1225  
<http://www.ajnr.org/content/22/6/1217>

# Dural Arteriovenous Fistula in Children: Endovascular Treatment and Outcomes in Seven Cases

Patricia K. Kincaid, Gary R. Duckwiler, Y. Pierre Gobin, and Fernando Viñuela

**BACKGROUND AND PURPOSE:** Dural AVF is a vascular anomaly that rarely occurs in children and is best treated by endovascular embolization. We report our experience using various endovascular embolization techniques in the treatment of dural AVF in a pediatric population.

**METHODS:** Seven children with angiographically proven dural AVF were treated with endovascular embolization using microcoils, *N*-butylcyanoacrylate, detachable balloons, and/or silk suture. All imaging studies, embolization procedures, and patient charts were retrospectively reviewed.

**RESULTS:** Seven children had been treated for dural AVF at our institution since 1987. Three newborns presented with congestive heart failure. Four older children (10 months–10 years) presented with signs referable to venous hypertension, including seizures, hydrocephalus, and proptosis. Embolization approaches included transarterial, transvenous, and direct puncture after neurosurgical exposure of a dural sinus. The number of embolizations ranged from 1 to 13 sessions per patient. All patients experienced symptomatic improvement after each embolization session. The three newborns showed marked improvement in cardiac function that allowed discharge to home. Clinical follow-up ranged from 3 weeks to 9 years (mean, 4.1 years). Two children with partially embolized dural AVF died, and one was lost to follow-up. Four children are alive after complete embolization of their dural AVF; two are developmentally normal, and two have mild developmental delay.

**CONCLUSION:** Endovascular embolotherapy is the current treatment of choice for dural AVF. Embolization therapy may be life saving in the setting of cardiac failure and curative in cases of small or simple fistulae. Multiple, complex dural AVF are usually not curable, and treatment is aimed at symptomatic relief. Treatment strategies focus on the location and/or complexity of the fistula, the patient's clinical status, and the neurologic prognosis.

Dural AVF are uncommon vascular malformations that are rare in the pediatric population (1, 2). They may be a cause of life-threatening congestive heart failure in neonates. Expedient diagnosis and treatment may be life saving in this setting. Older children with dural AVF tend to present with neurologic problems related to intracranial venous hypertension. For these children, prompt therapy is critical to prevent irreversible brain injury (1).

Endovascular embolization is currently the leading treatment option for dural AVF. Embolization of dural AVF achieves short-term palliation at least and may be curative at best. We report a series of seven children with dural AVF, describe their treatment using endovascular embolization techniques, and report their outcomes. In addition, we review the clinical and radiologic findings associated with this unusual and interesting disease.

Received May 10, 2000; accepted after revision January 16, 2001.

From the Divisions of Diagnostic (P.K.K.) and Interventional (G.R.D., Y.P.G., F.V.) Neuroradiology at the University of California Los Angeles Medical Center, Center for the Health Sciences, Los Angeles, CA.

Presented in part at the Western Neuroradiological Society Meeting, October 1997, La Quinta, CA.

Address preprint requests to Gary Duckwiler, MD, Department of Radiological Sciences, University of California Los Angeles Medical Center, Room B2-188 CHS, 10833 Le Conte Avenue, Los Angeles, CA 90095.

## Methods

Seven children had undergone endovascular treatment for simple or complex dural AVF at our institution since 1987. A retrospective analysis of these cases included review of the patients' charts and all available imaging studies, including transcranial sonography, MR imaging, CT, and angiography. Telephone interviews were conducted to obtain current follow-up information regarding patients who had not been recently seen.

Clinical information and imaging findings are summarized in Table 1. Treatment and outcomes are summarized in Table 2.

TABLE 1: Clinical and radiologic findings

Case (No.)/ Sex	Age at First Treat- ment	Presentation	Other Clinical Information	Initial Imaging	DAVF Location
1/F (Fig 2)	1 day	CHF	Premature birth at 32 weeks GA, Gr. 2 IVH, duplicated left kidney.	Prenatal sonography read as "posterior fossa cyst", CT of brain showed normal parenchyma.	Left transverse, sigmoid sinuses.
2/M	4 days	CHF; occipital bruit.	.....	Normal brain parenchyma on CT scan.	Torcula, SSS.
3/M	8 days	CHF, ↑HC, cranial bruit.	Syndactaly	Normal brain parenchyma on CT scan.	Torcula
4/F	10 months	Seizures, ↑HC	Hemangiomas of face and tongue enlarging since birth.	MR showed enlarged venous sinuses, ↑T2W signal in white matter, hydrocephalus, tonsillar prolapse.	Multifocal SSS
5/M (Fig 3)	18 months	Seizures	↑HC was being followed, prominent facial veins noted.	CT showed hydrocephalus, wide subarachnoid spaces over convexities. First angiogram showed bilateral sigmoid sinus occlusions.	Right transverse sinus, torcular
6/F	4 years	↑ Right proptosis and pain.	Right orbital vascular lesion with near blindness in that eye since birth.	Normal brain parenchyma on CT, MR.	Right sphenoparietal sinus and superior orbital fissure.
7/F (Fig 1)	10 years	Seizures, headache, right proptosis, chemosis, visual loss, bilateral cranial bruits.	Facial vascular lesion at birth, development reportedly normal. CT for closed head injury at age 6 showed cerebral calcification leading to erroneous dx of Sturge-Weber.	Hydrocephalus and dystrophic brain calcification on CT scans. Tonsillar prolapse, ischemic changes in right hemisphere on MR images.	Torcula, SSS, right sphenoparietal and cavernous sinuses, bilateral inferior petrosal sinuses.

Note.—CHF, congestive heart failure; GA, gestational age; Gr, grade; IVH, intraventricular hemorrhage; SSS, superior sagittal sinus; ↑, increased; HC, head circumference; T2W, T2-weighted; dx, diagnosis.

TABLE 2: Treatment and outcome

Case #	Embol. Route	# of Embol. Sessions	Embol. Materials	Angiographic Outcome (Time from Last Embol.)	Clinical Outcome (Time from 1st Embol.)	Comments
1 (Fig 2)	Transarterial, trans-venous.	3	Coils, NBCA.	Complete embol. (at last session).	Alive, developmentally normal, blind in left eye (1 year). Dead (3 weeks).	Embolized left middle meningeal a. arose from the left ophthalmic a. Acute epidural hematoma at torcula on autopsy. Lost to f/u.
2	Transarterial.	1	Coils, PVA.	Partial embol. with 90% reduction in flow (at single session).	Alive (3 years).	
3	Transarterial.	1	Coils, NBCA.	Partial embol. with 80% reduction in flow (at single session).	Alive (3 years).	
4	Transarterial, trans-venous and direct puncture.	4	Coils, NBCA.	Complete embol. (3 months), acquired stenosis of left transverse sinus.	Alive, mild developmental delay, mild right hemiparesis (6.3 years).	Attends regular school with 1 year delay, resolution of seizures.
5 (Fig 3)	Transarterial, trans-venous.	4	Coils, NBCA.	Complete embol. (14 months), rerouting of venous drainage through SOVs.	Alive, mild delay in fine motor skills (3.5 years).	Attends regular school with 1 year delay, occasional headaches, no seizures.
6	Transarterial.	1	PVA.	Partial embol. (at single session). No residual DAVF on f/u angiogram (7.75 years)	Alive, developmentally normal (9 years).	Single embol. was followed by complete surgical resection.
7 (Fig 1)	Transarterial, trans-venous, and direct puncture.	13	Coils, NBCA, balloons, silk suture.	Partial embol. (16 months), acquired stenoses of bilateral sigmoid sinuses.	Dead (6.25 years) following slowly progressive neurological deterioration.	Extremely large, complex, multifocal DAVF.

Note.—embol., embolization; NBCA, N-butylcyanoacrylate; PVA, polyvinyl alcohol; a., artery; SOVs, superior ophthalmic veins; DAVF, dural arteriovenous fistula; f/u, follow-up.

All patients were treated by embolization via transarterial, transvenous, or direct venous puncture approaches. Direct puncture techniques were used after neurosurgical exposure of the involved sinus and were usually used when the fistula nidus was inaccessible by conventional transarterial approaches or when such an approach would entail unacceptable risk for untoward embolization of the normal tissue. Embolization materials included fibered platinum microcoils, Guglielmi detachable coils, *N*-butylcyanoacrylate, polyvinyl alcohol particles, detachable balloons, and silk suture. Guglielmi detachable coils were used instead of fibered coils in specific circumstances. First, when the flow rate was high and there was a concern that the coil would migrate, the pre-detachment control led us to use Guglielmi detachable coils. Second, when using 0.010-in systems, the size options for fibered coils was limited and Guglielmi detachable coils were therefore used.

Our approach to the treatment of these lesions has evolved over the years as the materials have improved, and the long-term results of limited treatment have become evident. Because those patients with significant residual fistulae tended to do poorly (see Results), we have become more aggressive early in the course of the disease. Also, with modern materials, direct puncture access is usually no longer necessary because we are usually able to get sufficiently distal, via either the transarterial or transvenous route, to allow embolization. Our goal during the acute period is related to the presentation and status of the patient's condition. In those patients with congestive heart failure, a reduction of the flow sufficient for survival and growth is performed, with later attempts at cure (usually at 3–6 months of age) if this is not achieved at the time of the first embolization. However, if the brain continues to use the involved sinus as a major outlet, close follow-up is conducted and repeat embolization via a transarterial approach is attempted to prevent delayed brain injury. In those patients presenting later in the disease process, aggressive transarterial embolization is recommended because the onset of seizures and neurologic deficit indicates ongoing brain injury. It is possible, in some cases, to occlude the sinuses when rerouting of venous outflow has occurred. However, this is generally a late finding at which time brain injury has already occurred.

Our current materials of choice are fibered coils of sufficient size or with a detachment mechanism to prevent migration when embolizing from a transvenous approach. *N*-butyl cyanoacrylate is the agent of choice in transarterial approaches and in transvenous embolization after a sufficient nest of coils is placed to prevent untoward pulmonary embolization.

However, more important than any technique is that the family needs to know the severity of the disease process and why this leads to an aggressive treatment approach.

## Results

### *Patient Population*

The seven children (three boys and four girls) can be divided into two categories by age: newborns and older children. The newborns all presented with life-threatening congestive heart failure within the first week of life (patients 1–3). The newborns were 1 to 8 days old at the time of first embolization. Of the older children, three presented with hydrocephalus and seizures (patients 4, 5, and 7) and one presented with proptosis (patient 6). These children ranged in age from 10 months to 10 years at the time of initial embolization. Overall, the most common presenting symptoms included congestive heart failure ( $n = 3$ ), seizures ( $n = 3$ ), facial vascular lesions ( $n = 3$ ), proptosis ( $n = 2$ ), and other congenital anomalies ( $n = 2$ ). Patient 1

had a duplicated left kidney, and patient 3 had syndactyly.

### *Initial Imaging Findings*

For the neonates, radiographs of the chest revealed cardiomegaly, pulmonary vascular congestion, and edema, consistent with their presentations with congestive heart failure. The initial CT scans obtained of these newborns showed enlargement of the involved venous sinuses but normal-appearing brain parenchyma. This contrasts with the initial imaging findings of some of the older children who, at the time of referral, had already developed hydrocephalus and evidence of brain ischemia. The evidence of parenchymal ischemic change included MR changes such as white matter thinning and T2 hyperintensity and CT findings of white matter hypodensity and dystrophic calcification (Fig 1). Patient 6, a 4-year-old child at the time of referral who had a very small dural AVF coupled with a large orbital vascular malformation, had no hydrocephalus or ischemic change revealed by the initial imaging. Also seen on the MR images was prolapse of the cerebellar tonsils through the foramen magnum in two patients (patients 4 and 7) (Fig 1) and large, increased flow voids in the involved venous sinuses.

The original angiograms documented the dural AVF in each patient. The arteries that were involved in most patients were the middle meningeal and occipital arteries (Fig 2). The first angiogram obtained of patient 5 (Fig 3) showed bilateral sigmoid sinus occlusions. No other patient had sinus occlusions revealed by initial angiography, although two patients acquired sinus stenoses later (patients 4 and 7).

### *Dural AVF Nidus Location*

The torcular, transverse, and sigmoid sinuses were involved in the majority of cases (five of seven cases). One patient had multifocal involvement of the superior sagittal sinus (patient 4). One patient had extremely complex, multifocal dural AVF involving the torcular, superior sagittal, sphenoparietal, cavernous, and petrosal sinuses (patient 7). One patient had a large orbital vascular malformation with a small associated dural AVF involving the superior orbital fissure and sphenoparietal sinus (patient 6).

### *Treatment*

We performed a total of 26 embolization sessions in the treatment of these seven patients. The number of embolization sessions per patient ranged from one to 13 (mean = 3.7 sessions per patient). The embolization route was transarterial in 16 sessions (seven patients) and transvenous in 11 (three patients). Of the transvenous approaches, three sessions in two patients were via direct puncture of the involved sinus.



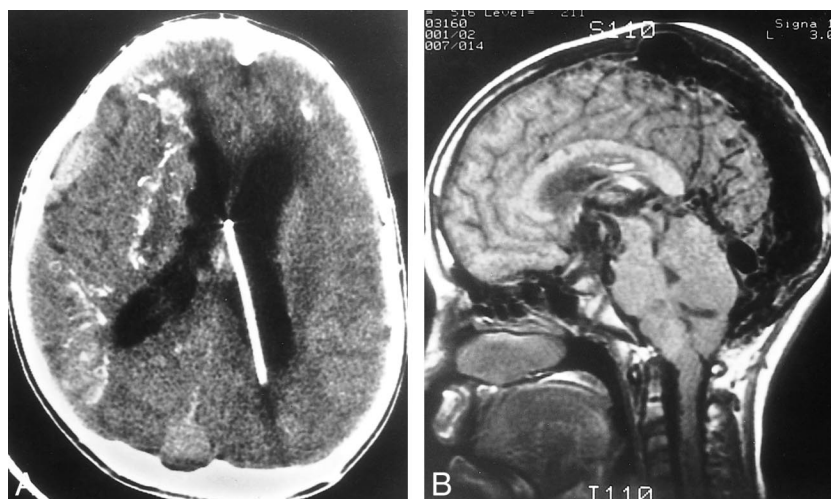


FIG 1. Patient 7 was a 10-year-old girl with a complex, multifocal dural AVF (infantile type dural arteriovenous shunt), who presented late with advanced neurologic symptoms.

A, Axial view contrast-enhanced CT scan obtained at the time of referral shows dystrophic calcification in the brain parenchyma, hydrocephalus, thinning of white matter that is abnormally hypodense, and enlarged right sphenoparietal and superior sagittal sinuses. This patient had already developed irreversible brain injury related to her dural AVF.

B, Sagittal view T1-weighted MR image shows a significantly enlarged flow void in the superior sagittal sinus and torcular herophili, some of the sites of arteriovenous shunting in this patient. Also note the prolapse of the cerebellar tonsils at the craniocervical junction, the so-called *acquired Chiari I malformation* that can also be seen with the vein of Galen malformation.

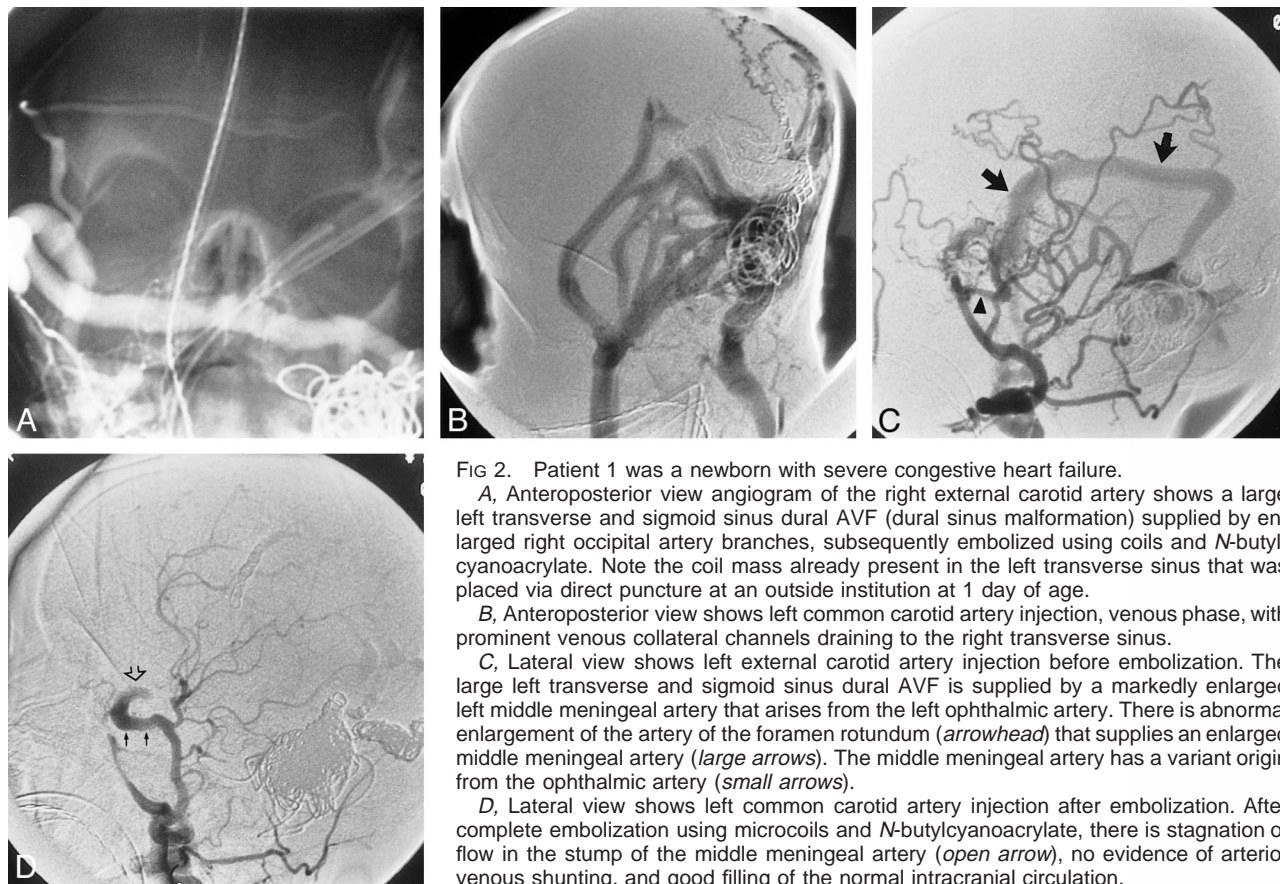


FIG 2. Patient 1 was a newborn with severe congestive heart failure.

A, Anteroposterior view angiogram of the right external carotid artery shows a large left transverse and sigmoid sinus dural AVF (dural sinus malformation) supplied by enlarged right occipital artery branches, subsequently embolized using coils and *N*-butylcyanoacrylate. Note the coil mass already present in the left transverse sinus that was placed via direct puncture at an outside institution at 1 day of age.

B, Anteroposterior view shows left common carotid artery injection, venous phase, with prominent venous collateral channels draining to the right transverse sinus.

C, Lateral view shows left external carotid artery injection before embolization. The large left transverse and sigmoid sinus dural AVF is supplied by a markedly enlarged left middle meningeal artery that arises from the left ophthalmic artery. There is abnormal enlargement of the artery of the foramen rotundum (arrowhead) that supplies an enlarged middle meningeal artery (large arrows). The middle meningeal artery has a variant origin from the ophthalmic artery (small arrows).

D, Lateral view shows left common carotid artery injection after embolization. After complete embolization using microcoils and *N*-butylcyanoacrylate, there is stagnation of flow in the stump of the middle meningeal artery (open arrow), no evidence of arteriovenous shunting, and good filling of the normal intracranial circulation.

The majority of the embolizations were performed using microcoils (17 embolization sessions) and *N*-butylcyanoacrylate (16 sessions). Polyvinyl alcohol particles and detachable balloons were used

in two sessions each, and silk suture was used in only one session. The use of polyvinyl alcohol particles occurred before 1989. The embolization sessions using silk suture and balloons were performed

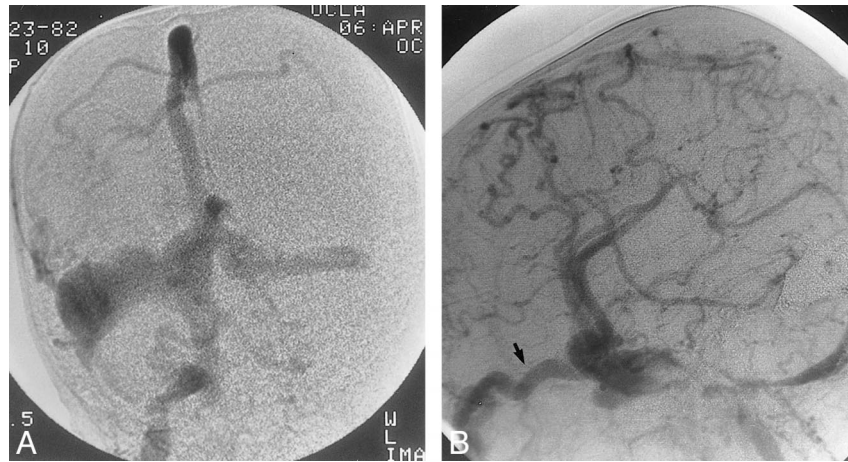

FIG 3. Patient 5, with a dural sinus malformation, was an 18-month-old who presented with seizures and prominent facial veins.

A, Anteroposterior view angiogram of the right external carotid artery, venous phase, shows bilateral sigmoid sinus occlusions and an enlarged occipital vein. The arterial phase (not shown) showed enlarged right occipital artery feeders to a large right transverse sinus dural fistula.

B, Lateral view angiogram of the right common carotid artery, obtained after complete embolization of the dural AVF, shows development of collateral venous drainage, ultimately draining through the superior ophthalmic veins (*arrow*), which is seen to be markedly dilated.

before 1995, and these materials were used to fill gaping spaces in very enlarged venous sinuses.

Patient 6, the patient with the large orbital malformation, underwent surgical resection of the residual dural AVF in the middle cranial fossa after partial embolization. The dural AVF could not be completely embolized in this patient because of technical inability to catheterize the ophthalmic artery that gave off multiple small branches supplying the fistula. No other patient received adjuvant surgical or radiation therapy.

#### *Immediate Outcome*

Immediate angiographic and clinical outcomes after each embolization session were good. Angiographically, each embolization session achieved either marked reduction in flow or complete obliteration with stagnation of flow through the dural AVF. The dural AVF were completely embolized at the last session in three patients. From a clinical standpoint, all the neonates experienced marked improvement in cardiac function. The older children each experienced immediate improvement in referring symptoms such as decreased frequency or severity of seizures, decreased proptosis, and/or generally improved neurologic function. These effects proved permanent in those patients in whom complete embolization was achieved.

Procedural complications occurred in two patients. Patient 2, a newborn with a huge torcular hemophilic dural AVF that was partially embolized on his fourth day of life, showed marked postembolization improvement of cardiac function, allowing discharge home at 13 days of age. Approximately 2 weeks after discharge, the baby was found cyanotic and apneic in his crib. Cardiopulmonary

resuscitation was unsuccessful. The autopsy showed an acute epidural hematoma at the torcular.

Another newborn (patient 1) experienced two individual procedural complications. The chest radiograph obtained after embolization of a large transverse and sigmoid sinus dural AVF showed several small pulmonary radiodensities, consistent with *N*-butylcyanoacrylate emboli. Despite this, her cardiopulmonary status significantly improved after the dural AVF embolization procedure. She also developed a postembolization thrombocytopenia that was thought to be related to platelet consumption by the thrombosis of the embolized venous sinus. This required platelet transfusion, but the baby subsequently did very well.

#### *Delayed Outcome*

Delayed angiographic follow-up was performed in four patients ranging from 3 months to 7.75 years after last embolization (mean, 31 months). Three patients were cured with no angiographic evidence of residual dural AVF. Two of them (patients 4 and 5) had undergone complete embolization at the last embolization session, and one had undergone partial embolization plus complete surgical resection (patient 6).

The fourth patient for whom follow-up angiography was available (patient 7), was the girl who presented at 10 years of age with a large, complex and multifocal dural AVF. She underwent 13 separate embolization procedures in attempts to slow her neurologic deterioration. Her last angiogram showed multifocal residual dural AVF, bilateral sigmoid sinus stenoses, and severe cerebral venous hypertension. An attempt to angioplasty the left sigmoid sinus was unsuccessful because of extreme fibrosis. Consider-

ing the limited success achieved by previous embolizations and the patient's poor neurologic status and prognosis, her parents chose to place her in hospice, where she later died at the age of 16 years.

Clinical follow-up ranged from 3 weeks to 9 years (mean, 4.1 years) after first embolization. At last follow-up, five patients were alive. One of the five was known to be alive at 3 years after a single embolization procedure performed at 8 days of age but was subsequently lost to follow-up (patient 3). Of the remaining four living patients for whom current follow-up information is available, two are developmentally normal (patients 1 and 6) and the other two have only mild neurologic deficits (ie, diminished fine motor skills in patient 5 and mild hemiparesis in patient 4). One developmentally normal child is blind in one eye (patient 1). All these children are cured. The two patients who died have already been discussed.

### Discussion

There are few case reports of intracranial dural AVF occurring in the pediatric population. The two largest reported series to date were 11 cases reported by Garcia-Monaco et al (3), only four of which were described in detail because of their unusual complexity, and 29 cases described by Lasjaunias et al (1), which probably included some cases from the other series. In addition to those 29 cases, there are only 20 others reported in the literature (4–17). Dural AVF account for approximately 10% of all intracranial arteriovenous shunts in children, lower than the 10% to 20% estimated for adults (3, 18, 19). When occurring in children, dural AVF have a greater incidence of multifocality and tend to have a more aggressive clinical course (eg, congestive heart failure, hypertensive venopathy, hydrocephalus) (1, 20). In this series of children with dural AVF, we also observed greater complexity and multiplicity than is usually seen in cases of adult dural AVF.

Dural AVF are direct arteriovenous connections with the dura itself, with drainage into dural sinuses or cortical veins. Meningeal and pial vessels can contribute to the fistula. Pathologically, the malformation consists of a network of arteriovenous microfistulae in the wall of a dural sinus (19–21). The most common locations of dural AVF are the sigmoid-transverse, cavernous, and superior sagittal sinuses (22). Those affecting the occipital-suboccipital region are reported to account for 50% of all dural AVF (2).

The arterial supply and venous drainage observed in this series of pediatric dural AVF are similar to those reported in the literature. The transverse-sigmoid, superior sagittal sinus, and torcular herophili were the most commonly involved fistula sites. In addition, either the middle meningeal or occipital arteries or both initially supplied all the malformations. After transarterial embolization of these main arterial feeders, follow-up angiography

frequently revealed interval recruitment of smaller arterial feeders by the dural AVF. This secondary development of new shunts in the region of a partially treated dural AVF has been well described in the literature (3, 4, 21). The new shunts can be dural, pial, or both. Explanations that have been proposed for the development of these secondary shunts include abnormal angiogenetic activity and/or a venous “sump” effect related to the dural AVF (1, 3, 21).

In the adult patient, dural AVF is generally accepted as being an acquired disorder. Because of the increased incidence of concomitant venous sinus thrombosis with dural AVF, many authors have ascribed sinus thrombosis a pathogenetic role in the formation of these vascular malformations (22–26). Adults with dural AVF frequently have etiologic risk factors for venous sinus thrombosis, including head trauma, neurologic surgery, and ear or sinus infection (24, 25). That some patients with dural AVF have no evidence of previous sinus thrombosis and that a venous thrombosis can be acquired from a dural AVF add further confusion regarding the pathogenesis of these malformations (26). Lasjaunias et al (1) proposed that a primary structural weakness of the dura coincided with a trigger factor, resulting in the formation of a dural AVF. Congenital causes have also been theorized, but several observations have been made regarding dural AVF in infants and children that oppose a true congenital (embryologic) cause (27). First, dural AVF have not been shown to be familial or associated with other vascular malformations. Second, in several pediatric cases of dural AVF, Garcia-Monaco et al (3) observed the presence of mature arterial and venous configurations and the absence of persistent embryonic vascular patterns. They therefore theorized that dural AVF in children develop after the third month of intrauterine life and may be considered acquired, although the acquisition may occur prenatally. Still, the exact intrauterine events leading to the development of these lesions remain unknown, and a multifactorial process is likely.

Clinical manifestations vary by age, location of fistula, and severity of arteriovenous shunting. Lasjaunias et al (1) describe three types. First is the dural sinus malformation, which typically occurs in neonates. Second is the infantile type dural arteriovenous shunt, which occurs in children. Third is the adult type dural arteriovenous shunt, which is less frequent but also occurs in children. The neonates with dural AVF, in whom direct arteriovenous shunting is severe at birth, tend to present immediately with congestive heart failure as a result of the increased venous return and volume overload. The babies also usually have an objective cranial bruit. We observed this presentation in patients 1, 2, and 3. These three patients and patient 5 correspond to the dural sinus malformation classification presented by Lasjaunias et al. The leading clinical differential consideration in cases such as these is



a vein of Galen malformation. This diagnosis can be excluded by imaging findings of a normal sized vein of Galen and straight sinus. The lesion often affects the torcular herophili or lateral sinus. If the lesion involves the lateral sinus, a direct transvenous approach can be curative with preservation on normal brain venous outflow through the torcular herophili and contralateral sinus. If the torcular herophili is involved, the sinus can be taken only when venous rerouting has occurred (as in patient 5).

In general, we found that the degree of arteriovenous shunting was less severe in the older children. If their dural AVF were present at the time of birth, either their hearts compensated for the lesser arteriovenous shunting or venous outflow restriction allowed the fistula to remain clinically silent until cerebral venous hypertension became symptomatic. Cerebral venous hypertension, due to direct arteriovenous shunting, may cause venous ischemia or infarction, hemorrhage, and/or problems with CSF dynamics. When the pressure within the superior sagittal sinus approximates or exceeds the pressure in the subarachnoid space, there is resultant failure of resorption CSF, thus producing an imbalance in brain water or volume and ventricular size (3). We also found that a later presentation was more variable by location of the dural AVF. As in adults, the children with dural AVF involving the cavernous sinus region presented with proptosis and chemosis (patients 6 and 7). Of interest is that older children with dural AVF often have objective but non-subjective cranial bruits, which suggests that the noise was always present in the natural acoustic environment of the child and was thus probably present at birth (3, 4).

The radiologic findings of these children also tended to vary by patient age. The brains of the newborns were essentially normal, except for the enlarged venous structures related to the dural AVF. With such an early presentation, no radiographic or clinical brain injury had yet occurred. We found that the longer the dural AVF remained undiagnosed and cerebral venous hypertension went unchecked, the more irreversible was the brain injury. Ischemic brain injury was evidenced by dystrophic calcification in the brain parenchyma (Fig 1) and white matter abnormalities, such as thinning and abnormal density or intensity.

Another imaging finding of these children, previously described in conjunction with vein of Galen malformation, is cerebellar tonsillar prolapse (Fig 1). This tonsillar prolapse has been shown to be reversible after endovascular treatment and is thought to be a result of hydrovenous dysfunction of the posterior fossa (28).

A frequent angiographic finding that has been reported in association with dural AVF is venous sinus occlusion and/or stenosis (22, 23, 26, 28). It is often not possible to determine whether the venous sinus occlusion/stenosis preceded the development of the dural AVF, possibly playing an etiopathogenic role, or was caused by the dural AVF.

In addition, the combination of intracranial hypertensive venopathy and arterialized, turbulent blood flow can also lead to progressive veno-occlusive disease in the cortical veins and dural sinuses by an as yet undefined mechanism (29, 30). In this series, bilateral sigmoid sinus occlusion was observed on the initial angiogram in one patient and two other patients acquired sinus stenoses during staged embolization treatment.

Endovascular treatment of dural AVF is now widely considered the first primary method of therapy. Appropriate medical management with inotropic agents and diuretics is also vital at the onset of cardiac manifestations (31). Surgical resection after partial embolization may be successful in small dural AVF, as in patient 6 (classified as adult type dural arteriovenous shunt). Surgical treatment without previous embolization carries a risk of significant operative blood loss, which is a particular concern in infants (4). Radiation therapy has been used in adults with localized slow flow dural lesions but is not an appropriate treatment in infants or children with extensive dural AVF (32).

Endovascular therapy should be targeted to the specific area of shunting that is thought to be most responsible for the individual patient's symptoms. In infants with cardiac decompensation, the area of highest arteriovenous shunting should be embolized first (Fig 2). As with all such procedures, embolization at the nidus of the lesion is critical if cure is to be achieved. Proximal embolization, although possibly resulting in transient symptomatic improvement, is associated with a high rate of recurrence and may serve to isolate the involved sinus so as to make further transvascular treatment attempts difficult or impossible. Because of the recruitment of secondary shunts at the fistula nidus, it has been our experience that cure can be achieved only after complete occlusion of the involved venous sinus. This is most easily done in cases of dural AVF that are relatively simple and involve single sinuses or short segments of larger sinuses; in such cases in this series, embolization was most successful. Our typical treatment approach began with transarterial embolization of the main arterial feeders with a permanent agent such as *N*-butylcyanoacrylate. If necessary, transvenous packing of the involved sinus was then performed to accomplish complete sinus occlusion.

Multifocal dural shunts (infantile type dural arteriovenous shunts) that involve nearly all the major dural venous sinuses, as in patients 4 and 7, cannot be immediately cured by current embolization techniques because complete occlusion of all the involved venous sinuses would result in severe venous outflow problems. When a major dural sinus becomes occluded, the cerebral venous drainage must reroute, which is usually accomplished without difficulty in the setting of a single area of dural sinus occlusion. If multiple major venous sinuses are occluded, the venous outflow typically

becomes redirected through cortical veins or deep venous sinuses. It is in this setting that collateral venous drainage may prove inadequate, resulting in dangerous cerebral venous hypertension. Therefore, in patients with complex, multifocal dural AVF, endovascular treatment is generally aimed at symptomatic relief. However, patient 4 developed sinus thrombosis after repeated arterial embolizations resulted in cure.

If the cerebral venous drainage successfully reroutes through adequate venous collaterals, cure may be achieved after complete occlusion of the involved venous sinuses. We observed this phenomenon in patient 5 (Fig 3). When this patient was referred to us at 18 months of age, his initial angiogram showed bilateral sigmoid sinus occlusions and the presence of collateral venous drainage pathways eventually draining through the superior ophthalmic veins. It was the presence of these important venous collaterals that proved crucial to his favorable outcome after complete embolization of most of the posterior venous sinuses.

### Conclusion

Pediatric dural AVF are more often multiple and are usually more complex than adult dural AVF. Early, aggressive treatment is critical to prevent long-standing cerebral venous hypertension and resultant irreversible brain injury. Endovascular embolization is currently the best treatment option for dural AVF and may be life saving in the setting of neonatal congestive heart failure. Embolization strategies must be individualized to the patient's presenting symptoms. Depending on the complexity of the fistula, treatment may be either palliative or curative, but in our experience, cure can be achieved only after total occlusion of the involved sinus.

### References

- Lasjaunias P, Maguif A, Goulao R, Suthipongchai S, Rodesch R, Alvarez H. **Anatomoclinical aspects of dural arteriovenous shunts in children.** *Intervent Neuroradiol* 1996;2:179-191
- Ushikoshi S, Kikuchi Y, Miyasaka K. **Multiple dural arteriovenous shunts in a 5-year-old boy.** *AJNR Am J Neuroradiol* 1999; 20:728-730
- Garcia-Monaco R, Rodesch G, Terbrugge K, Burrows P, Lasjaunias P. **Multifocal dural arteriovenous shunts in children.** *Childs Nerv Syst* 1991;7:425-431
- Albright AL, Latchaw RE, Price RA. **Posterior dural arteriovenous malformations in infancy.** *Neurosurgery* 1983;13: 129-135
- Al-Mefty O, Jinkins JR, Fox JL. **Extensive dural arteriovenous malformation: case report.** *J Neurosurg* 1986;65:417-420
- Chan ST, Weeks RD. **Dural arteriovenous malformation presenting as cardiac failure in a neonate.** *Acta Neurochir (Wien)* 1988;91:134-138
- Debrun G, Chartres A. **Infra and supratentorial arteriovenous malformations, a general review: about 2 cases of spontaneous supratentorial arteriovenous malformation of the dura.** *Neuroradiology* 1972;3:184-192
- Epstein B, Platt N. **Visualization of an intracranial arteriovenous fistula during angiocardiology in an infant with congestive heart failure.** *Radiology* 1962;79:625-627
- Gordon IJ, Shah BL, Hardman DR, Chameides L. **Giant dural supratentorial arteriovenous malformation.** *AJR Am J Roentgenol* 1977;129:734-736
- Konishi Y, Hieshima GB, Hara M, Yoshino K, Yano K, Takeuchi K. **Congenital fistula of the dural carotid-cavernous sinus: case report and review of the literature.** *Neurosurgery* 1990;27: 120-126
- Newton TH, Hoyt WF. **Spontaneous arteriovenous fistula between dural branches of the internal maxillary artery and the posterior cavernous sinus.** *Radiology* 1968;91:1147-1150
- Robinson JL, Sedzimir CB. **External carotid-transverse sinus fistula: case report.** *J Neurosurg* 1970;33:718-720
- Rosenbloom S, Edwards M. **Dural arteriovenous malformations.** In: Edwards MH, ed. *Cerebral Vascular Disease in Children and Adolescents*. Baltimore: Williams & Wilkins; 1989:343-365
- Ross DA, Walker J, Edwards MS. **Unusual posterior fossa dural arteriovenous malformation in a neonate: case report.** *Neurosurgery* 1986;19:1021-1024
- Sundt TM Jr, Piepgras DG. **The surgical approach to arteriovenous malformations of the lateral and sigmoid dural sinuses.** *J Neurosurg* 1983;59:32-39
- Tsugane R, Sato O, Watabe T. **Non-communicating hydrocephalus caused by dural arteriovenous malformation.** *Surg Neurol* 1979;12:393-396
- Van de Werf A. **Sur un cas d'anévrisme arterioveux intradural bilatéral de la fosse postérieure chez un enfant.** *Neurochirurgie* 1964;10:140-144
- Luessenhop A. **Dural arteriovenous malformations.** In: Wilkins RH, ed. *Neurosurgery*. New York: McGraw-Hill; 1985:1473-1477
- Newton TH, Cronqvist S. **Involvement of dural arteries in intracranial arteriovenous malformations.** *Radiology* 1969;93: 1071-1078
- Chaloupka J. **Endovascular therapy of dural arteriovenous fistulae.** *Semin Intervent Radiol* 1994;11:1-13
- Iizuka Y, Rodesch G, Garcia-Monaco R, et al. **Multiple cerebral arteriovenous shunts in children: report of 13 cases.** *Childs Nerv Syst* 1992;8:437-444
- Houser OW, Campbell JK, Campbell RJ, Sundt TM Jr. **Arteriovenous malformation affecting the transverse dural venous sinus: an acquired lesion.** *Mayo Clin Proc* 1979;54:651-661
- Chaudhary MY, Sachdev VP, Cho SH, Weitzner I Jr, Puljic S, Huang YP. **Dural arteriovenous malformation of the major venous sinuses: an acquired lesion.** *AJNR Am J Neuroradiol* 1982; 3:13-19
- Djindjian R, Merland JJ. **Superselective Arteriography of the External Carotid Artery.** Berlin: Springer; 1978
- Cognard C, Gobin YP, Pierot L, et al. **Cerebral dural arteriovenous fistulas: clinical and angiographic correlation with a revised classification of venous drainage.** *Radiology* 1995;194: 671-680
- Mironov A. **Pathogenetical consideration of spontaneous dural arteriovenous fistulas (DAVFs).** *Acta Neurochir (Wien)* 1994; 131:45-58
- Roland J, Bernard C, Bracad S, et al. **Microvascularization of the intracranial dura mater.** *Surg Radiol Anat* 1987;9:43-49
- Girard N, Lasjaunias P, Taylor W. **Reversible tonsillar prolapse in vein of Galen aneurysmal malformations: report of eight cases and pathophysiological hypothesis.** *Childs Nerv Syst* 1994; 10:141-147
- Duckwiler GR, Dion JE, Viñuela F, Reichman A. **Delayed venous occlusion following embolotherapy of vascular malformations in the brain.** *AJNR Am J Neuroradiol* 1992;13: 1571-1579
- Reichman A, Viñuela F, Duckwiler GR, Peacock WJ, Vinters HV. **Pathologic findings in a patient with a vein of Galen aneurysm treated by staged endovascular embolization.** *Childs Nerv Syst* 1993;9:33-38
- Garcia-Monaco R, De Victor D, Mann C, Hannedouche A, Terbrugge K, Lasjaunias P. **Congestive cardiac manifestations from cerebrocranial arteriovenous shunts: endovascular management in 30 children.** *Childs Nerv Syst* 1991;7:48-52
- Lasjaunias PL, Berenstein A, Raybaud C. **Surgical Neuroangiography.** Berlin: Springer-Verlag; 1987