



## **MR Imaging in Comatose Survivors of Cardiac Resuscitation**

Eelco F. M. Wijdicks, Norbert G. Campeau and Gary M. Miller

*AJNR Am J Neuroradiol* 2001, 22 (8) 1561-1565  
<http://www.ajnr.org/content/22/8/1561>

This information is current as of May 5, 2025.

# MR Imaging in Comatose Survivors of Cardiac Resuscitation

Eelco F. M. Wijdicks, Norbert G. Campeau, and Gary M. Miller

**BACKGROUND AND PURPOSE:** The prognosis of comatose survivors is determined by clinical examination. Early laboratory indicators of poor prognosis (such as evoked potentials) have low sensitivity. The role of MR imaging as a confirmatory study was investigated.

**METHODS:** We studied fluid-attenuated inversion recovery (FLAIR) and diffusion-weighted (DW) imaging in 10 patients comatose after cardiac arrest.

**RESULTS:** None of the 10 comatose patients had myoclonus status epilepticus or fixed, dilated pupils on neurologic examination, and none had abnormal somatosensory-evoked potentials. Eight patients showed diffuse signal abnormalities, predominantly in the cerebellum ( $n = 5$ ), the thalamus ( $n = 8$ ), the frontal and parietal cortices ( $n = 8$ ), and the hippocampus ( $n = 9$ ). One patient showed normal MR imaging results, and one patient had abnormalities in the thalamus and cerebellum and minimal abnormality on DW images; both later awakened. None of the patients with abnormal cortical structures on FLAIR MR images recovered beyond a severely disabled state.

**CONCLUSION:** MR imaging in comatose survivors may parallel the pathologic findings in severe anoxic-ischemic injury, and extensive abnormalities may indicate little to no prospects for recovery. If confirmed, MR imaging may have a role as a prognosticating test in anoxic-ischemic coma.

Since the landmark study by Levy et al (1) on prognostication in anoxic-ischemic coma, to our knowledge no study has challenged its findings that clinical examination within the first 3 days can accurately determine outcome (2–5). Recent studies have added clinical and electrophysiological modifiers that may further aid in prognostication. We and others have found that myoclonus status epilepticus in comatose patients portends a poor outcome (6–8), and several authors have noted that somatosensory-evoked potentials (SSEP) performed within 24 hours after cardiac resuscitation may accurately predict a persistent vegetative state (9, 10).

In certain circumstances, an additional confirmatory test is needed before poor prognosis in anoxic-ischemic coma can be established. First, many patients are heavily sedated or paralyzed after cardiac resuscitation to combat pulmonary complications, which renders neurologic examination almost

useless. Second, early clinical signs of poor prognosis are infrequent, occurring in 20% of patients at most. Further, tests such as CT or SSEP have not been consistently useful because abnormal findings, such as diffuse cerebral edema or absent scalp potentials on SSEP, also are uncommon. Third, families of previously healthy patients struck by severe anoxic-ischemic damage to the brain often demand some form of corroborative testing for assurance before the decision is made to withdraw support.

MR imaging may aid in prognostication, but its availability, its costs, and the complicated transport of patients with the potential for recurrent cardiac arrhythmias have been prohibitive and hindered its study. We performed a preliminary study of MR imaging using fluid-attenuated inversion recovery (FLAIR) and diffusion-weighted (DW) imaging in 10 comatose survivors of cardiac arrest.

## Methods

For 12 months, we prospectively followed 27 patients who remained comatose after cardiac resuscitation. All of the patients, who had been admitted to a medical or surgical intensive care unit, underwent a complete neurologic examination. Consent was obtained to perform MR imaging, but in 17 patients with terminal cardiac failure or recurrent cardiac arrhythmias, MR imaging was not judged safe. Ten patients underwent MR imaging with anesthesia support. It took 20 to 30 minutes to

Received May 30, 2000; accepted after revision March 23, 2001.

From the Departments of Neurology (E.F.M.W.) and Diagnostic Radiology (N.G.C., G.M.M.), Mayo Medical Center and Mayo Foundation, Rochester, Minnesota.

Address reprint requests to E. F. M. Wijdicks, MD, Mayo Clinic, W8B, 200 First Street SW, Rochester, MN 55905.

© American Society of Neuroradiology

TABLE 1: Clinical features in 10 comatose patients after cardiac arrest

Patient No.	Age (y)/Sex	Place of Arrest	GCS	Brain Stem Reflexes	SSEP	EEG	Days to MR	Outcome
1	66/F	Out of hospital	3	Intact	ND	Delta-Theta	1	Vegetative state
2	32/F	In hospital	3	Intact	ND	ND	1	Death
3	43/M	In hospital	3	Intact	Normal	Delta	6	Death
4	60/M	Out of hospital	5	Intact	Normal	ND	7	Vegetative state
5	76/F	In hospital	3	Intact	Normal	ND	15	Death
6	49/M	Out of hospital	3	Intact	Indeterminate	Theta	6	Death
7	65/M	In hospital	3	Intact	Indeterminate	ND	2	Death
8	71/M	In hospital	3	Intact	ND	ND	8	Death
9	46/F	Out of hospital	3	Intact	Normal	Theta	4	Good
10	66/F	In hospital	4	Intact	ND	Delta	1	Good

Note.—F indicates female; M, male; ND, not done; GCS, Glasgow coma score; SSEP, somatosensory-evoked potential; EEG, electroencephalography.

TABLE 2: MR characteristics in 10 patients with anoxic-ischemic coma

Patient No.	Cereb		Brainst		Basal G		Caud		Thal		Splen		Front		Temp		Pariet		Occip		Insular		Hippoc		WM	
	F	D	F	D	F	D	F	D	F	D	F	D	F	D	F	D	F	D	F	D	F	D	F	D	F	D
1	●	●		●					●		●		e		e		e		e		●		●		●	●
2			●	●	●		●		●	●	●	●	●	●	●		●	●	●	●			●		●	●
3							●	●	●	●	●	●	●	●	●	●	●	●	●	●	●	●	●	●	●	●
4	●	●	●				●		●				e		e		e		e		●		●		●	●
5	●	●	●	●	●								●	●		e		●	●	●	●	●	●			●
6					●		●		●				●	●	●		●	●	●	●	●	●	●		●	●
7	●	—		—	●	—	●	—	●	—		—	●	—	●	—	●	—	●	—	●	—	●	—	—	—
8*	●	—	●	—	●	—	●	—	●	—		—	●	—	●	—	●	—		—	●	—	●	—	—	—
9*	●	●							●												●		●			
10*																										
Totals	6	4	4	3	5	0	6	1	8	2	3	2	8	4	7	1	8	4	7	5	8	1	9	1	4	3

Note.—Cereb indicates cerebellum; Brainst, brain stem; Basal G, basal ganglia; Caud, caudate; Thal, thalamus; Splen, splenium; Front, frontal lobe; Temp, temporal lobe; Pariet, parietal lobe; Occip, occipital lobe; Hippoc, hippocampus; WM, white matter; e, cerebral edema; F, FLAIR; D, diffusion; ND, not done; ●, signal abnormality; —, not done.

\* No DW imaging performed.

complete the study in each patient. The MR images were reviewed without knowledge of any of the clinical features.

Nine of the patients had a noncontrast CT head examination within 24 hours of their anoxic event, and all 10 patients had MR imaging of the head 1 to 15 days after resuscitation (median, 6 days). All MR examinations were performed with a 1.5-T imager (General Electric Signa LX, 8.2.5, Milwaukee, WI). Standard MR imaging was performed in all 10 patients, which included a T1-weighted sagittal sequence (580/14/1 [TR/TE/excitation]), intermediate- and T2-weighted spin-echo axial sequences (2000–2500/30–80/1), and a FLAIR T2-weighted axial sequence (1100/168/2250/1 [TR/TE/TI/excitation]). Echo-planar DW images (9999/93/1, b = 1000 s/mm<sup>2</sup> in three orthogonal directions, and b = 0 with FLAIR prepulse TI = 2200) were acquired in seven patients. Six patients were given intravenous contrast medium (Magnevist, 0.1 mmol/kg, Berlex Laboratories, Princeton, NJ), and postcontrast T1-weighted axial and coronal images were obtained (400–500/14–20/2). Two patients had follow-up MR imaging of the head, within 4 or 5 days of the first study.

## Results

The clinical features are shown in Table 1. Age ranged from 32 to 76 years. Six patients had in-hospital arrest. Eight of 10 patients had a Glasgow coma sum score of 3 after resuscitation, but brain stem reflexes were present in all patients. There

were absent motor responses to pain in eight patients, and extensor responses in two patients. One patient showed continuous blinking, and another patient had a persistently downward gaze. None of the patients had a sustained upward gaze or myoclonus status epilepticus. Median SSEP were performed in six patients and were normal or indeterminate (prolonged latencies or unilaterally absent scalp potential). Electroencephalography (EEG), available for five patients, showed a mixed appearance of delta and theta frequencies. None of the patients had an  $\alpha$ -coma or burst-suppression pattern. CT scan findings were normal in all nine patients.

The MR imaging features are shown in Tables 2 and 3. Apparent diffusion coefficient (ADC) mapping and quantification are shown in Table 3. Normal values are  $700\text{--}800 \times 10^{-6} \text{ mm}^2/\text{s}$ ; decreased ADC values represent areas of restricted diffusion, presumably because of infarction. Areas with increased ADC should represent vasogenic edema. In six patients, MR imaging showed diffuse signal abnormalities in the cortex in both hemispheres, frontal and parietal lobes, cerebellum, thalamus, and hippocampus (Fig 1). In two patients, effacement of the sulci and T2-weighted signal abnormalities

TABLE 3: Apparent diffusion coefficient mapping and quantification

Patient	Side	Cereb	Pons	Basal G	Caud	Thal	Splen	Front	Temp	Pariet	Occip	Insular	Hippoc	WM
1	R	651	660		700	732	692	775		743	752	783		707
	L	654			688	721		783		708	764	781		643
2	R	791	799		874	748		915		804	798			
	L				889	838		952			792			
3	R	725	680		614	738	276		546		637			244
	L				650	704					618			369
4	R	671	782		1038	782	744	945			728			750
	L	621			1016	789			776		514			694
5	R	660	674		1088	776	960			594	518	844		757
	L	635			737	780			818		519	772		656
6	R	710	735		818	781	854		844	513	557	797		683
	L	712			832	805			806	409	467	834		697
7	R	794	702			723	723				794		862	790
	L					798			769				765	780

Note.—R indicates right; L, left; other abbreviations as in Table 2. DW imaging not performed in patients 8–10.

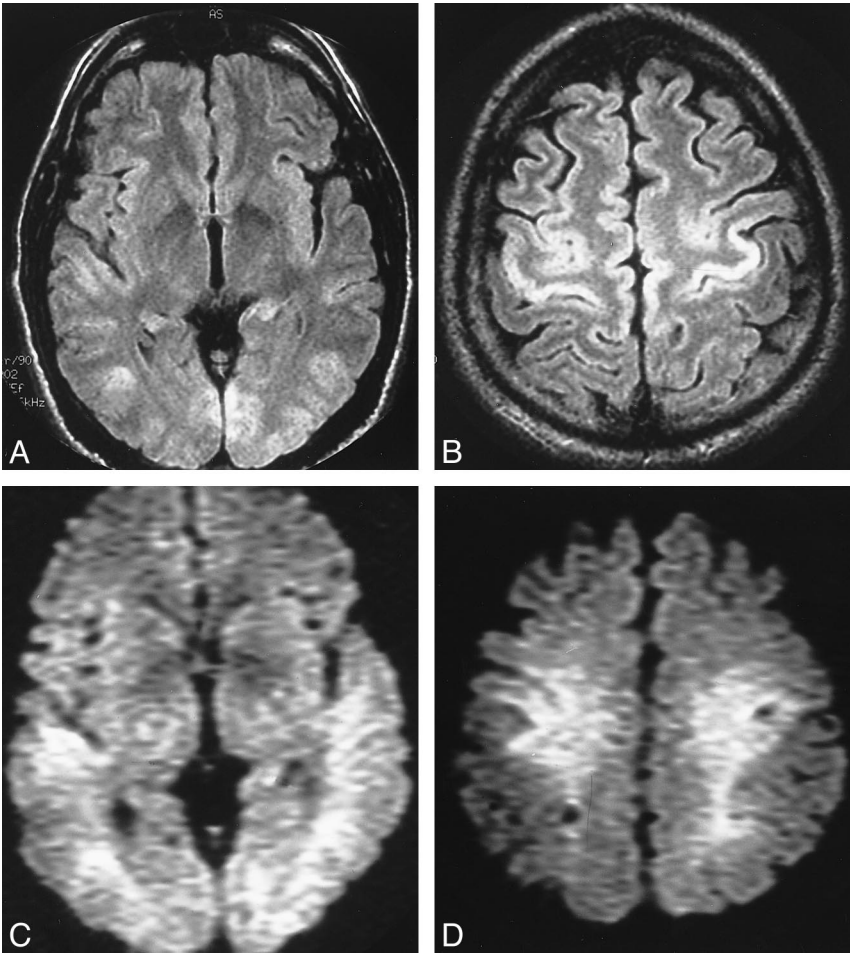


FIG 1. Patient 3. A and B, Axial FLAIR images show widespread T2 signal abnormalities. C and D, throughout the cortices of both cerebral hemispheres. DWI shows intense signal at these locations.

were found in white matter (Fig 2). None of these eight patients recovered beyond a severely disabled state, and six patients died within several weeks from withdrawal of support or systemic complications. Two patients awakened within 3 days with no major neurologic deficit. One patient had normal MR images, and one patient had abnormalities in the thalamus and cerebellum and minimal abnormalities on DWI (Fig 3).

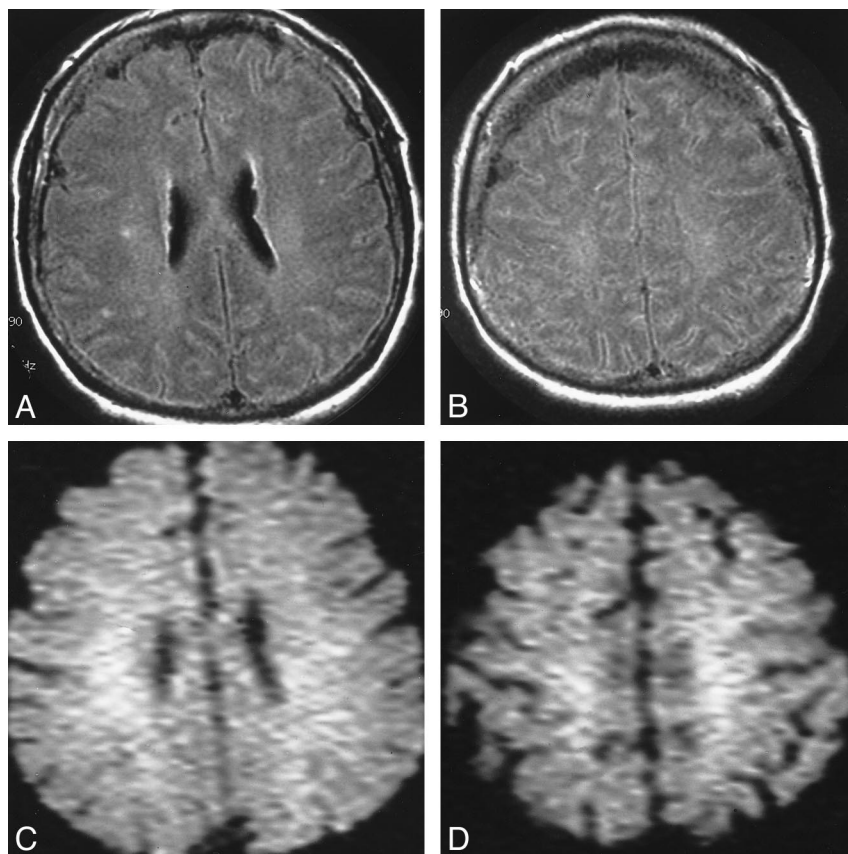
Discussion

Outcome in comatose survivors of resuscitation is determined by the presence of heart failure or recurrent cardiac arrhythmias. Patients who survive this critical period may remain comatose and pose a difficult problem in planning future treatment. Our study of MR imaging shows its potential for use in prognostication in comatose survivors of cardiac resuscitation. The MR abnormalities in co-

FIG 2. Patient 1.

A and B, Axial FLAIR images show cerebral edema with effacement of the sulci and T2 signal abnormalities in white matter.

C and D, DW images show only a corresponding white matter abnormality.



matose patients who never awakened were diffuse and extensive, involving the cortex, thalamus, and cerebellum. The two patients who awakened had normal or localized findings on MR images. We believe that this study may have value because no other clinical or laboratory features were present that would have predicted poor outcome. Clinical neurologic examination revealed intact brain stem reflexes and absence of myoclonus status epilepticus. None of our patients who underwent electrophysiological tests showed abnormal median SSEP (9, 10) or burst-suppression patterns on EEG.

We do acknowledge the difficulty of performing MR imaging in these critically ill patients. In fact, our preliminary cohort suggests only one in three patients may be eligible for MR imaging. In our major teaching hospital, the proximity of the MR imager to the intensive care units allowed us to perform MR imaging with anesthesia support during the acquisition of data. None of the patients had any life-threatening cardiac arrhythmias or hypotension during transport or MR imaging, but we excluded patients in need of inotropic or antiarrhythmic agents. Thus, the applicability of our data to the entire population of comatose survivors of cardiac arrest remains very uncertain, and we should continue to expect major logistical difficulties with MR imaging.

The MR abnormalities can be widespread and represent the well-described pathologic patterns seen at autopsy. Selective vulnerability has been reported for anoxic-ischemic injury; the middle

lamina of the cortex, caudate nucleus, putamen, globus pallidus, thalami, and Purkinje cells may be at particular risk. In this MR study, these predisposed locations were affected, although border zone infarcts were absent. The presence of cortical involvement in our preliminary series appeared to distinguish between poor outcome and possible recovery.

DW imaging measures the diffusion of free water. Ischemic brain damage results in restricted diffusion of free water, principally because of failure of the energy-requiring active water transport mechanism. The physiological changes of acute ischemia initially manifest as areas of high signal intensity on DW images. Diffusion abnormalities are present within minutes of an acute ischemic episode and, DW imaging will show infarcts earlier than conventional MR imaging, including FLAIR images (11, 12). Inclusion of DW imaging is important if imaging is to be performed within several hours of the ischemic insult. This was highlighted in a study by Arbelaez and coworkers (13), in which two of three patients imaged within 3 hours showed only diffusion abnormalities. DW imaging signal abnormalities may not be present in the subacute period (days 6–12) because of pseudonormalization of the ADC. This is not of any concern, because the FLAIR images remain abnormal, as seen in one patient in this study imaged after 1 week.

### Conclusion

Our results confirm those of the early study by Arbelaez and associates (13), who reported similar



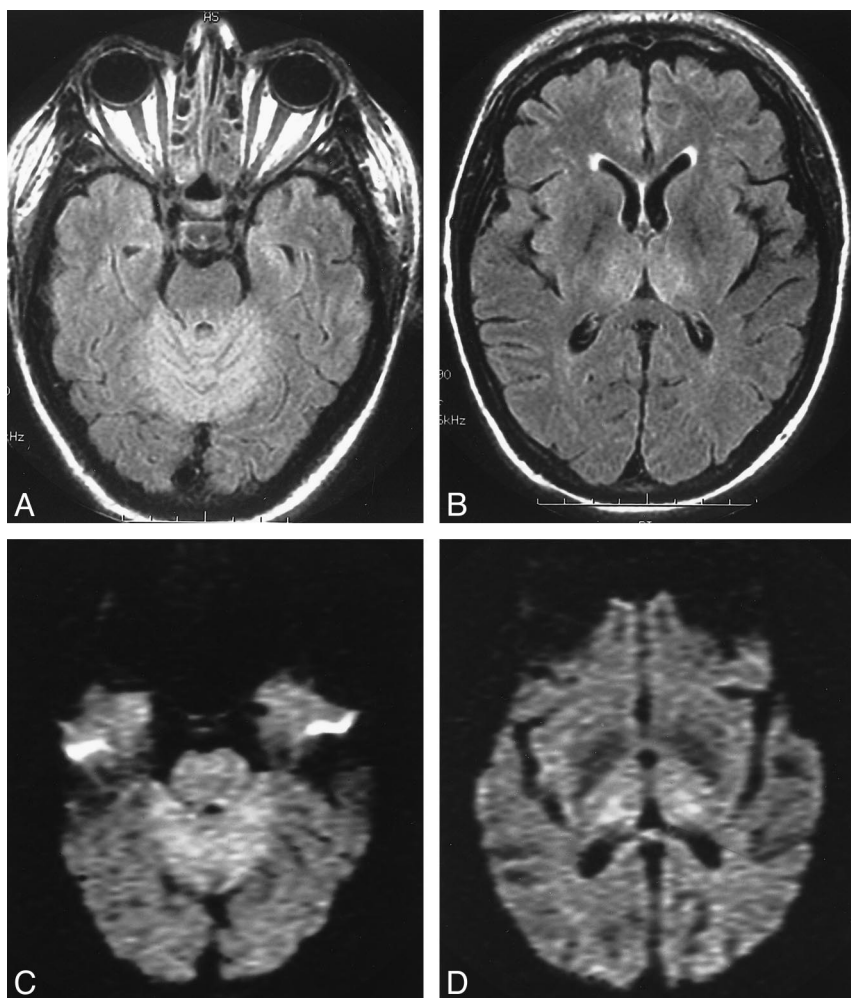


FIG 3. Patient 9.

A and B, Axial FLAIR images at the level of the superior cerebellum and thalamus show symmetrical T2 signal abnormalities.

C and D, DW images at the same level show abnormalities at same locations.

abnormal changes in the basal ganglia, cerebellum, and cortex. However, comparison with their study is difficult because of inclusion of children and other causes for cardiac arrest (such as sepsis and cocaine overdose) and no correlation of MR imaging with other indicators of a poor prognosis. Further larger studies are needed, but our preliminary observation suggests that FLAIR and DW imaging can help detect extensive ischemic damage in comatose survivors. If our observations are confirmed, withdrawal of intensive care support can be justified, thus reducing the substantial costs of prolonged intensive care of severely crippled comatose survivors of resuscitation. The cost of a single MR study may offset these costs.

### References

1. Levy DE, Caronna JJ, Singer BH, Lapinski RH, Frydman H, Plum F. Predicting outcome from hypoxic-ischemic coma. *JAMA* 1985;253:1420-1426
2. Thomassen A, Wernberg M. Prevalence and prognostic significance of coma after cardiac arrest outside intensive care and coronary units. *Acta Anaesthesiol Scand* 1979;23:143-148
3. Mullie A, Verstringe P, Buylaert W, et al. Predictive value of Glasgow coma score for awakening after out-of-hospital cardiac arrest. Cerebral Resuscitation Study Group of the Belgian Society for Intensive Care. *Lancet* 1988;1:137-140
4. Sandroni C, Barelli A, Piazza O, Proietti R, Mastro D, Boninsegna R. What is the best test to predict outcome after prolonged cardiac arrest? *Eur J Emerg Med* 1995;2:33-37
5. Attia J, Cook DJ. Prognosis in anoxic and traumatic coma. *Crit Care Clin* 1998;14:497-511
6. Wijdicks EF, Parisi JE, Sharbrough FW. Prognostic value of myoclonus status in comatose survivors of cardiac arrest. *Ann Neurol* 1994;35:239-243
7. Krumholz A, Stern BJ, Weiss HD. Outcome from coma after cardiopulmonary resuscitation: relation to seizures and myoclonus. *Neurology* 1988;38:401-405
8. Young GB, Gilbert JJ, Zochodne DW. The significance of myoclonic status epilepticus in postanoxic coma. *Neurology* 1990;40:1843-1848
9. Zandbergen EG, de Haan RJ, Stoutenbeek CP, Koelman JH, Hijdra A. Systematic review of early prediction of poor outcome in anoxic-ischaemic coma. *Lancet* 1998;352:1808-1812
10. Chen R, Bolton CF, Young B. Prediction of outcome in patients with anoxic coma: a clinical and electrophysiologic study. *Crit Care Med* 1996;24:672-678
11. Mintorovich J, Moseley ME, Chileuitt L, Shimizu H, Cohen Y, Weinstein PR. Early detection of cerebral ischemia in cats: comparison of diffusion and T2-weighted MRI and spectroscopy. *Magn Reson Med* 1990;14:330-346
12. Mintorovich J, Moseley ME, Chileuitt L, Shimizu H, Cohen Y, Weinstein PR. Comparison of diffusion and T2-weighted MRI for the early detection of cerebral ischemia and reperfusion in rats. *Magn Reson Med* 1991;18:39-50
13. Arbelaez A, Castillo M, Mukhterji SK. Diffusion-weighted MR imaging of global ischemic cerebral anoxia. *AJNR Am J Neuroradiol* 1999;20:999-1007