



## ASNR Career Center

The Go-To Job Site for Neuroradiology Employers and Job Seekers

Start here: [careers.asnr.org](http://careers.asnr.org)

# AJNR

### **Superior Petrosal Sinus Catheterization for Transvenous Embolization of a Dural Carotid Cavernous Sinus Fistula**

Charbel Mounayer, Michel Piotin, Laurent Spelle and Jacques Moret

This information is current as of September 30, 2023.

*AJNR Am J Neuroradiol* 2002, 23 (7) 1153-1155  
<http://www.ajnr.org/content/23/7/1153>

# Superior Petrosal Sinus Catheterization for Transvenous Embolization of a Dural Carotid Cavernous Sinus Fistula

Charbel Mounayer, Michel Piotin, Laurent Spelle, and Jacques Moret

**Summary:** We report the endovascular treatment of a dural carotid cavernous fistula in a 67-year-old woman in whom superior petrosal sinus catheterization was performed to access the venous site of the fistula. To our knowledge, this retrograde venous route via the superior petrosal sinus has not been previously described.

Dural carotid cavernous fistulas (DCCFs) are a rare cause of eye redness. Most DCCFs are well tolerated and resolve spontaneously without any treatment. However, hyperpressure in the superior ophthalmic vein (SOV) may cause eye damage. Similarly, cortical venous reflux sometimes causes intracranial hemorrhage (1). Treatment for DCCFs should be considered for patients in whom clinical symptoms (eg, bruit, headaches, proptosis, chemosis, eye redness) are bothersome and among patients with cranial nerve palsy (eg, diplopia, facial or trigeminal paresis; impairment of visual acuity). Brain hemorrhage and cortical venous drainage are absolute indications for treatment. Both arterial and venous endovascular approaches have been used (2–4). We report a case of a DCCF that was treated by embolization after venous retrograde access to the superior petrosal sinus (SPS) was achieved.

## Patient Characteristics and Description of Technique

A 67-year-old woman was admitted to our institution for painful eye redness of 6 months' duration. Clinical examination revealed chemosis and proptosis of the right ocular globe. No evidence of associated cranial nerve palsy was present. CT findings confirmed the exophthalmia and an enlarged right SOV and ruled out a tumoral origin of the symptoms. Cerebral angiography revealed a DCCF fed by arterial rami arising from the ipsilateral carotid siphon and by branches of the right middle meningeal artery (Fig 1). The site of the fistula was identified at the posterosuperior margin of the right cavernous sinus (CS). The DCCF drained into the right CS, which drained into the right SOV, the right superficial middle cerebral vein, and the right trigeminal vein. At cerebral venography, the most

distal aspect of the right SPS was identified at the point where it merged with the right transverse sinus (Fig 2). With the patient under general anesthesia and tracheal intubation, a 5F sheath was inserted into the right internal jugular vein, and an unsuccessful attempt was made to recanalize the right inferior petrosal sinus (IPS) with a 0.035-inch hydrophilic guidewire (Radiofocus; Terumo, Tokyo, Japan). Then, the right SPS was targeted and recanalized by using a 0.016-inch hydrophilic guidewire (Radiofocus; Terumo) and an Excelsior microcatheter (Boston/Target, Fremont, CA) in conjunction with a 5F hydrophilic guiding catheter (vertebral curve, Radiofocus; Terumo). The microcatheter was navigated up to the right CS into the collecting venous pouch of the fistula (Fig 3). This pouch was then packed with seven mechanically detachable platinum coils (DCS-18 and DCS-10; William Cook Europe, Bjaeverskov, Denmark). The control angiogram showed no more filling of the fistula (Fig 4). The immediate follow-up was uneventful, and the patient was discharged home 4 days after the procedure. Ocular symptoms regressed within a few weeks, and the patient was symptom-free at 6-month follow-up.

## Discussion

Many believe that the venous approach to DCCF treatment is the safest and most efficient way to manage the fistula (2, 4–6). The CS can be reached by either a posterior approach (ie, via the IPS) or an anterior approach (ie, via the SOV), although the latter after requires surgical exposure. Halbach et al (6) reported 13 cases of embolization after IPS catheterization. In five of these cases, they were not able to demonstrate the IPS at angiography performed before the intervention. Likewise, Oishi et al (7) reported five cases of IPS catheterization without opacification. Quinones et al (8) reported 12 patients who were treated after surgical exposure of the SOV, with 11 definitive occlusions. In that study, the SOV was catheterized in two patients although it was thrombosed. We do not have any experience with catheterization through a thrombosed SOV, but this possibility should be considered in cases in which IPS or SPS catheterization is not possible. Halbach et al (6) also reported four cases in which the transsellar approach was used. In these cases, CS embolization was performed via the contralateral CS, after the microcatheter was directed through the basilar plexus to the site of interest. This method can be used in cases in which the ipsilateral IPS is not seen and cases in which SOV catheterization appears to be too difficult. In our case, the SOV was patent, and approaching it from the facial vein would have been possible. More recently, a retrograde approach through the contralateral pterygoid plexus has also been described (9).

Received February 14, 2001; accepted after revision April 1, 2002.

From the Department of Interventional Neuroradiology, Fondation Rothschild, Paris, France.

Address reprints requests to Jacques Moret, MD, Service de Neuroradiologie Interventionnelle, Hôpital de la Fondation Ophthalmologique Adolphe de Rothschild, 75940 Paris Cedex 19, France.

FIG 1. Lateral angiograms.

A, Arterial-phase right internal carotid arteriogram shows the DCCF at the right posterosuperior aspect of the CS (*solid arrow*) fed by dural branches of the carotid siphon. The right trigeminal vein (*open arrow*) is draining the DCCF.

B, Right external carotid arteriogram shows that the DCCF is draining into the right superficial middle cerebral vein (*arrowheads*), the right SOV (*solid arrow*), and the right trigeminal vein (*open arrow*).

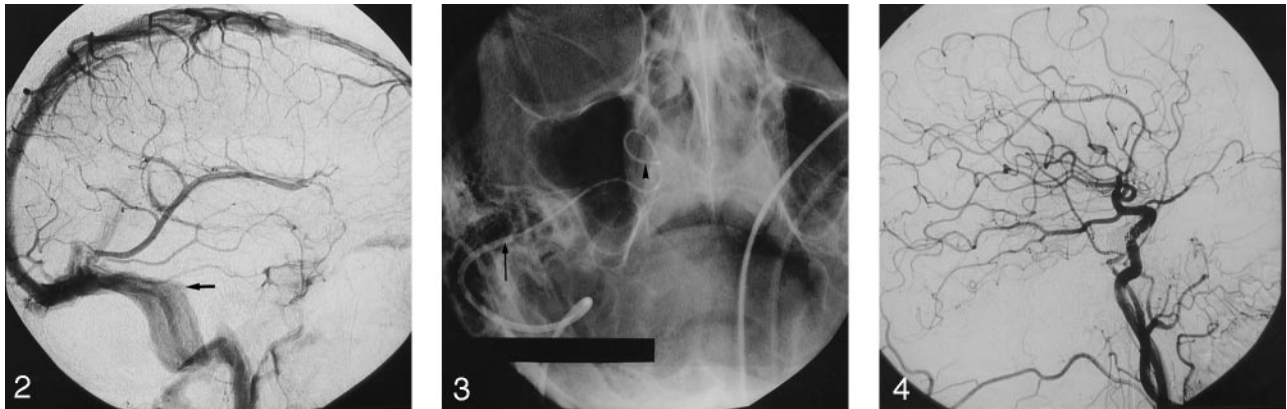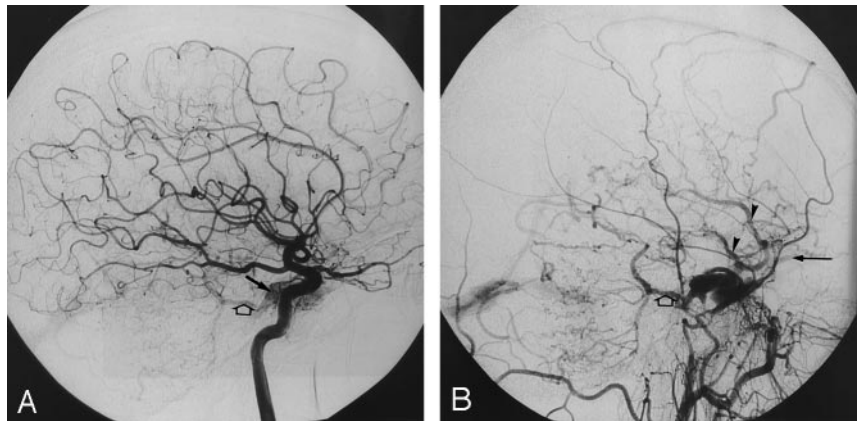


FIG 2. Venous-phase lateral left common carotid arteriogram. The most distal aspect of the right SPS is faintly opacified as it merges with the right transverse sinus (*arrow*).

FIG 3. Frontal skull radiographic image shows retrograde catheterization of the right SPS via a right internal jugular route. A 5F hydrophilic catheter (*arrow*) is positioned into the distal end of the right SPS by means of a right jugular approach. A microcatheter (*arrowhead*) is coaxially introduced into the 5F catheter and navigated into the SPS to reach the CS.

FIG 4. Right common carotid control angiogram obtained at the end of the embolization procedure shows that the DCCF is no more opacified than before and during the procedure.

Some authors (10) advocate sequential venous embolization, which consists of the occlusion of cortical draining veins, followed by occlusion of the noncortical veins, and finally coil placement in the CS. The main advantage of this method is that it prevents dangerous venous rerouting by first protecting the cortical draining pathways. We have no experience with this method, which was described only recently (10). With our approach, however, no increase in cortical drainage was seen after treatment. King et al (11) reported a subarachnoid hemorrhage owing to IPS perforation with a stiff guidewire. Oishi et al (7) reported five complications in 19 patients; the complications included blepharoptosis, forehead dysesthesia, and third and sixth cranial nerve palsies. The cranial nerves palsies were believed to be caused by coil over-packing or dural laceration inside the Dorello channel. The blepharoptosis may be caused by prolonged surgical exposure of the SOV, which leads to major eyelid edema.

### Conclusion

When the use of a retrograde venous approach is planned for the treatment of a DCCF, the retrograde

catheterization of the SPS can be considered as an alternative to IPS or SOV catheterization.

### References

1. Brown RD Jr, Wiebers DO, Nichols DA. **Intracranial dural arteriovenous fistulae: angiographic predictors of intracranial hemorrhage and clinical outcome in nonsurgical patients.** *J Neurosurg* 1994;81:531-538
2. Halbach VV, Higashida RT, Hieshima GB, Reicher M, Norman D, Newton TH. **Dural fistulas involving the cavernous sinus: results of treatment in 30 patients.** *Radiology* 1987;163:437-442
3. Lucas CP, Zabramski JM, Spetzler RF, Jacobowitz R. **Treatment for intracranial dural arteriovenous malformations: a meta-analysis from the English language literature.** *Neurosurgery* 1997;40:1119-1130
4. Roy D, Raymond J. **The role of transvenous embolization in the treatment of intracranial dural arteriovenous fistulas.** *Neurosurgery* 1997;40:1133-1141
5. Yamashita K, Taki W, Nishi S, et al. **Transvenous embolization of dural carotico-cavernous fistulae: technical considerations.** *Neuroradiology* 1993;35:475-479
6. Halbach VV, Higashida RT, Hieshima GB, Hardin CW, Pribram H. **Transvenous embolization of dural fistulas involving the cavernous sinus.** *AJNR Am J Neuroradiol* 1989;10:377-383
7. Oishi H, Arai H, Sato K, Iizuka Y. **Complications associated with transvenous embolisation of cavernous dural arteriovenous fistula.** *Acta Neurochir* 1999;141:1265-1271
8. Quinones D, Duckwiler G, Gobin PY, Goldberg RA, Vinuela F. **Embolization of dural cavernous fistulas via superior ophthalmic vein approach.** *AJNR Am J Neuroradiol* 1997;18:921-928

9. Jahan R, Gobin YP, Glenn B, Duckwiler GR, Vinuela F. **Transvenous embolization of a dural arteriovenous fistula of the cavernous sinus through the contralateral pterygoid plexus.** *Neuroradiology* 1998;40:189-193
10. Cheng KM, Chan CM, Cheung YL, et al. **Transvenous embolization of spontaneous carotid-cavernous fistulas by sequential occlusion of the cavernous sinus.** *Intervent Neuroradiol* 1999;5:225-234
11. King WA, Hieshima GB, Martin NA. **Venous rupture during transvenous approach to a carotid-cavernous fistula: case report.** *J Neurosurg* 1989;71:133-137